

# STRATIFICATION: An Essential Principle in Understanding Class IV Composite Restorations

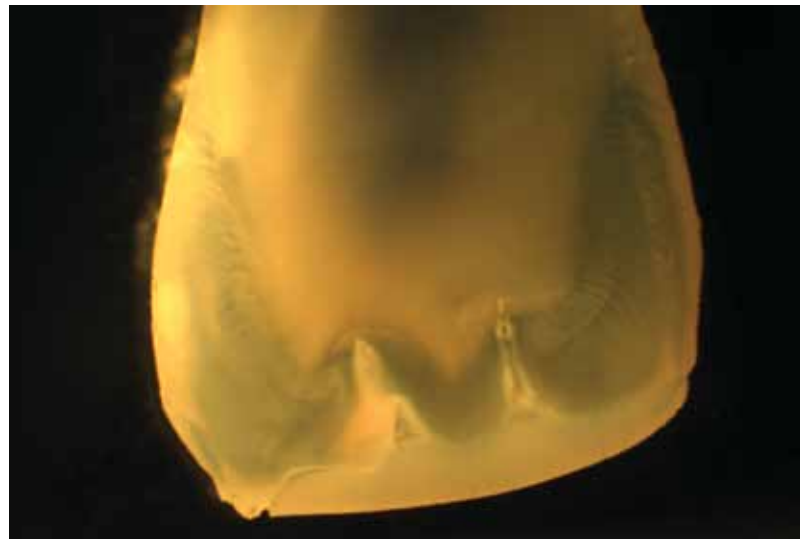
## Tips for Accreditation Case Type IV

Scott W. Finlay, DDS, FAGD, FAACD

### Introduction

Segmental restoration of teeth with composite resin is a common procedure and a valuable service to provide patients. This conservative restorative solution requires that a glass-reinforced resin blend invisibly with the adjacent tooth structure.<sup>1</sup> When we study the histological cross sections of natural teeth, we can appreciate the complexity of structure that we are trying to replace (**Fig 1**). Enamel is very crystalline, with specific—although varying—orientation. It has very little chroma, but does have a significant impact on how the light is reflected.<sup>2</sup> Dentin, on the other hand, is a very dense and amorphous layer that absorbs light and has the largest influence on chroma. In understanding the shades of teeth and attempting to restore what is missing, we want to use materials that are similar in their light-refractive qualities to the missing tooth (i.e., replacing dentin with a dentin substitute and enamel with an enamel substitute).<sup>3</sup>

Although there are limits to the correlation between the optical properties of natural tooth structure and resin, the conceptual application of the properties of stratification will go a long way in creating restorations that invisibly blend into the surrounding dentition. Most commercially available resin systems offer a series of resins that vary in opacity. Chromatic or achromatic enamel shades are the most translucent. Dentin shades are more opacous and have greater impact on the chroma of the tooth.<sup>4</sup>



**Figure 1:** The light-refractive properties of each of the layers of stratification within a natural tooth have an effect on the visual perception of shades and depth of color.

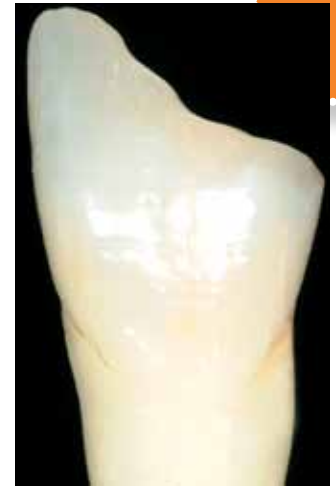// The mastery of stratification is a key principle in the successful restoration of teeth with both resin and ceramic materials. //

## Process

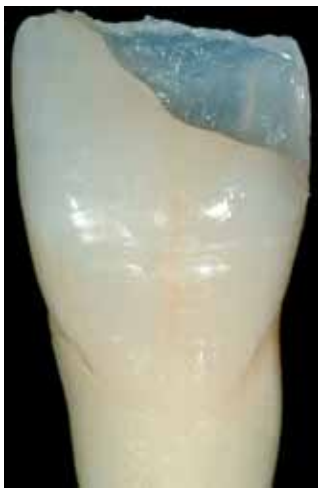A CLASS IV FRACTURE REQUIRES an understanding of the components of the optical properties of the adjacent tooth structure to create an invisible restoration (Fig 2). A series of two bevels is helpful in visually blending the cavo-surface into the surrounding tooth structure. The primary bevel involves the first 2 mm of the preparation. The secondary bevel continues from this point and tapers into the tooth's final facial contours (Fig 3).



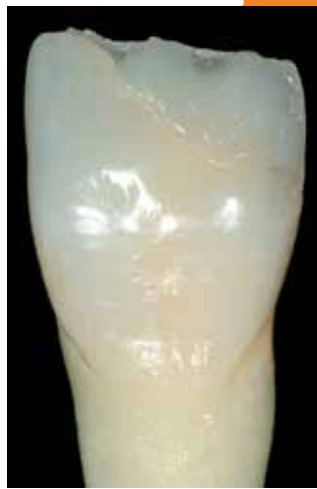**Figure 2:** It is necessary to understand the components of the optical properties of the adjacent tooth structure.



**Figure 3:** It is helpful to have two bevels to visually blend the cavo-surface into the surrounding tooth structure.



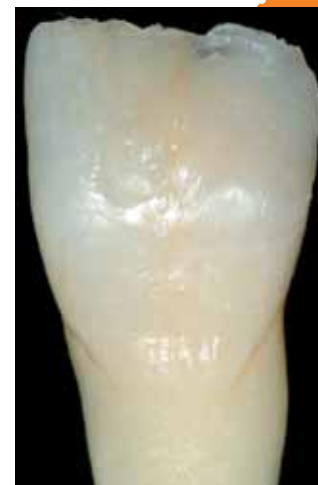**Figure 4:** A lingual shell of semi-translucent enamel shade composite defines the outline of the final tooth.



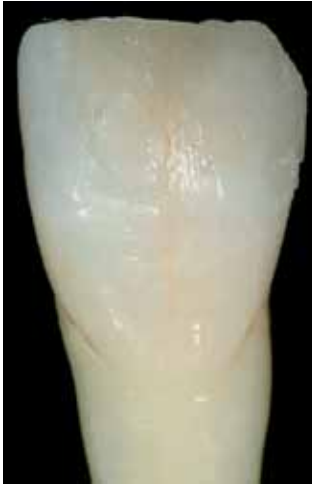**Figure 5:** A dentin shade is sculpted.

A LINGUAL SHELL OF SEMI-TRANSLUCENT ENAMEL shade composite defines the outline of the restored tooth. This is best developed utilizing a lingual putty stent created preoperatively from a diagnostic wax-up, or a composite mock-up intraorally (Fig 4). A dentin shade (which typically has the highest opacity in most resin systems) is then sculpted to reproduce the natural contours of the dentinal lobes observed in the adjacent tooth structure or adjacent teeth (Fig 5).

A CHROMATIC OR BODY SHADE RESIN is helpful in eliminating any visual recognition of the cavo-surface. This demarcation should disappear before the final translucent layer is applied. Also, if any maverick colors, fracture lines, or internal characterizations are to be applied, this must be accomplished during preparation of this layer (Fig 6).



**Figure 6:** A chromatic or body shade resin is helpful in eliminating any visual recognition of the cavo-surface.



**Figure 7:** A final layer of enamel resin is applied.



**Figure 8:** It is important to replicate the surface texture and polish that exist in the natural tooth surface.

A FINAL LAYER OF ENAMEL RESIN that mimics the translucency of the adjacent tooth structure is applied (**Fig 7**). Once the general contours of the tooth have been created, it is important to replicate the same surface texture and polish in the restorative material as exist in the natural tooth surface (**Fig 8**).

The achievement of Accreditation requires a level of excellence that demonstrates a broad knowledge and skill set in the restoration of teeth to their natural state. The mastery of stratification is a key principle in the successful restoration of teeth with both resin and ceramic materials.

#### Acknowledgment

*The author thanks Lee Culp, CDT, AAACD (Lakewood Ranch, FL) for the use of Figure 2.*

#### References

1. Terry DA. Dimensions of color: creating high diffusion layers with composite resin. *Compend Contin Educ Dent*. 2003 Feb;24(2 Suppl):3-13.
2. Vanini L. Light and color in anterior composite restorations. *Pract Periodontics Aesthet Dent*. 1996 Sep;8(7):673-82.
3. LeSage BP. Aesthetic anterior composite restorations: a guide to direct placement. *Dent Clin North Am*. 2007 Apr;51(2):359-78, viii.
4. Villarroel M, Fahl N, De Sousa AM, De Oliveria OB Jr. Direct resin restorations based on translucency and opacity of composite resins. *J Esthet Restor Dent*. 2011 Apr;23(2):73-87. **jCD**

“The conceptual application of the properties of stratification will go a long way in creating restorations that invisibly blend into the surrounding dentition.”



Dr. Finlay is an AACD Accredited Fellow and has been an AACD Accreditation Examiner since 2008. A 1986 graduate of the University of Maryland, Baltimore College of Dental Surgery, Dr. Finlay practices in Arnold, Maryland.

Disclosure: The author did not report any disclosures.