

# jcd

vol. 28 issue 1

Journal of Cosmetic Dentistry

## Subjective Art & Objective Science

I. Ahmad

## Feldspathic Stacked and Pressed Porcelain Veneers

D. Adolfi and M. Fradeani

## Conceptualizing the Complexities of Color and Smile Design

C. Sieber, J. Kim, B. LeSage, and L. Dalloca

SPRING 2012

**AACD** American Academy  
of Cosmetic Dentistry®

Fashioned for fit and performance.



**The latest advancement  
in LED curing lights**

- Newly designed light probe for easy access to posterior teeth
- Patented Polywave™ technology to cure all dental materials<sup>1</sup>
- Cordless or corded use

For more information log on to  
[ivoclarvivadent.us/bluephasestyle](http://ivoclarvivadent.us/bluephasestyle)

Introducing  
**bluephase**<sup>®</sup>  
*style*

LED CURING LIGHT

100% CUSTOMER SATISFACTION  
GUARANTEED!

[ivoclarvivadent.com](http://ivoclarvivadent.com)

Call us toll free at 1-800-533-6825 in the U.S., 1-800-263-8182 in Canada.  
©2012 Ivoclar Vivadent, Inc. bluephase, and polywave are trademarks of Ivoclar Vivadent.  
<sup>1</sup>All materials known to date in the range of 385 – 515 nm

**ivoclar**  
**vivadent**<sup>®</sup>  
passion vision innovation

# jcd

vol. 28 Issue 1  
Journal of Cosmetic Dentistry

## EDITOR-IN-CHIEF

Edward Lowe, DMD, AAACD  
Vancouver, BC, Canada, edlowe@mac.com

## MANAGING EDITOR

Tracy Skenandore, tracys@aacd.com

## PUBLICATIONS ASSISTANT

Denise Sheriff, denises@aacd.com

## ART DIRECTOR

Lynnette Rogers, lynnetter@aacd.com

## GRAPHIC DESIGNER

Elizabeth Kiracofe, elizabethk@aacd.com

## EDITORIAL CONSULTANT

Juliette Kurtz, publications@aacd.com

## MANUSCRIPT

## DEVELOPMENT LIAISON

Allison DiMatteo, MPS, allison@cremedellacreme.org

## MEMBERSHIP

## AND MARKETING DIRECTOR

Michael DiFrisco, michaeld@aacd.com

## ADVERTISING AND SPONSORSHIP

## DIRECTOR OF STRATEGIC PARTNERSHIPS

Jeff Roach, jeffr@aacd.com

## CONTRIBUTING EDITORS

Scott W. Finlay, DDS, FAGD, FAACD, Arnold, MD  
Julie M. Gillis, DDS, AAACD, Grand Junction, CO  
James H. Peyton, DDS, FAACD, Bakersfield, CA  
J.A. Reynolds, DDS, AAACD, Franklin, TN  
Gregory B. Wright, DDS, FAACD, Southlake, TX

## EDITORIAL MISSION

The mission of the *Journal of Cosmetic Dentistry* is to educate AACD members, as well as other professionals in the field, on the art and science of cosmetic dentistry. We will endeavor to do this by publishing well-researched, peer-reviewed articles accompanied by high-quality, comprehensive clinical imagery. The objective is to enhance readers' knowledge and skills while showcasing the latest cosmetic techniques and procedures. The *Journal of Cosmetic Dentistry* will strive to help readers become better clinicians, so they can offer their patients the best—and most responsible—treatment possible.

## AACD OFFICE

### CHIEF EXECUTIVE OFFICER

Ed Simeone

402 West Wilson Street, Madison, WI 53703

800.543.9220 • 608.222.8583

fax 608.222.9540 • info@aacd.com • www.aacd.com

---

Advertising: 800.543.9220 • 608.222.8583 or jeffr@aacd.com

Editorial: 800.543.9220 • 608.222.8583 or publications@aacd.com

---

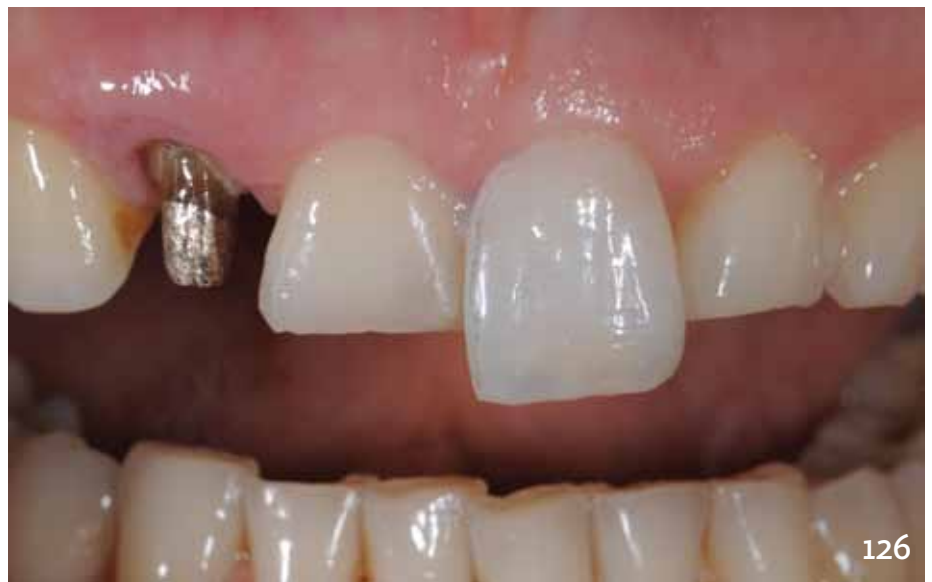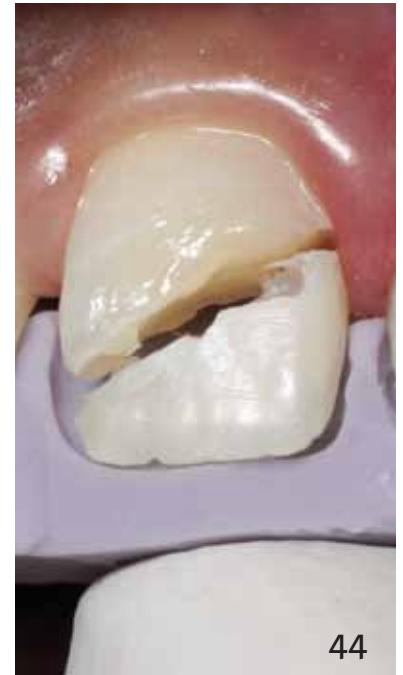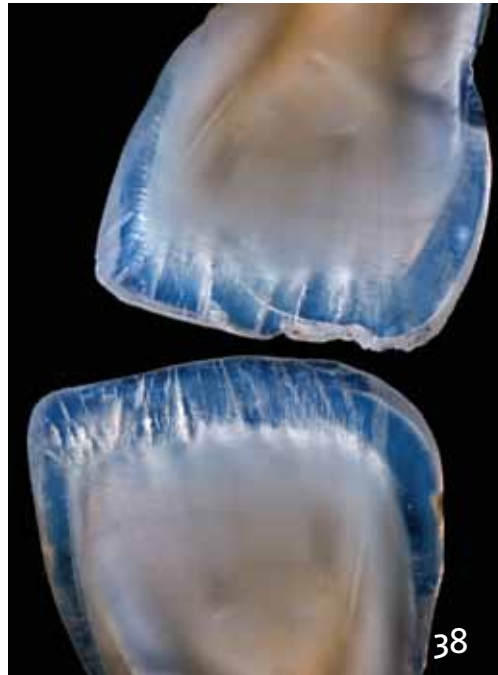
A PUBLICATION OF THE  
AMERICAN ACADEMY OF COSMETIC DENTISTRY

## EDITORIAL REVIEW BOARD

Pinhas Adar, MDT, CDT, Marietta, GA  
Naoki Aiba, CDT, Monterey, CA  
Gary Alex, DMD, AAACD, Huntington, NY  
Edward P Allen, DDS, PhD, Dallas, TX  
Elizabeth M. Bakeman, DDS, FAACD, Grand Rapids, MI  
Oliver Brix, MDT, Kelkheim, Germany  
Christian Coachman, DDS, CDT, São Paulo, Brazil  
Michael W. Davis, DDS, Santa Fe, NM  
Gerald E. Denehy, DDS, Iowa City, IA  
Newton Fahl Jr., DDS, MS, Curitiba-PR, Brazil  
Hugh D. Flax, DDS, AAACD, Atlanta, GA  
David A. Garber, DMD, Atlanta, GA  
Ronald E. Goldstein, DDS, FACD, FICD, Atlanta, GA  
Steve D. Hoofard, CDT, AAACD, Hermiston, OR  
Nelson Y. Howard, DDS, AAACD, San Marcos, CA  
Ronald D. Jackson, DDS, FAACD, Middleburg, VA  
San K. Jun, CDT, Monterey, CA  
Michael J. Koczarski, DDS, AAACD, Woodinville, WA  
John C. Kois, DMD, MSD, Seattle, WA  
Gerard Kugel, DMD, MS, PhD, Boston, MA  
Trevor R. Laingchild, RDT, AAACD, Burlington, ON, Canada  
Ernesto A. Lee, DMD, Bryn Mawr, PA  
David A. Little, DDS, San Antonio, TX  
Robert A. Lowe, DDS, Charlotte, NC  
Frank J. Milnar, DDS, AAACD, St. Paul, MN  
Ricardo Mitrani, DDS, MSD, Mexico D.F., Mexico  
Michael T. Morris, CDT, FAACD, Lexington, KY  
Carlos A. Munoz, DDS, MSD, Buffalo, NY  
Thomas W. Nabors III, DDS, AAACD, Nashville, TN  
W. Peter Nordland, DMD, MS, La Jolla, CA  
Paul S. Petrunaro, DDS, North Oaks, MN  
Gary M. Radz, DDS, Denver, CO  
Christopher D. Ramsey, DMD, AAACD, Jupiter, FL  
Nelson A. Rego, CDT, AAACD, Santa Fe Springs, CA  
Dwight G. Rickert, CDT, AAACD, Indianapolis, IN  
Robert G. Ritter, DMD, Jupiter, FL  
Matthew R. Roberts, CDT, AAACD, Idaho Falls, ID  
Jean-François Roulet, DDS, PhD, Schann, Liechtenstein  
Henry Salama, DMD, Atlanta, GA  
Maurice A. Salama, DMD, Atlanta GA  
Michael R. Sesemann, DDS, FAACD, Omaha, NE  
Michael Sonick, DMD, Fairfield, CT  
Rhys D. Spoor, DDS, AAACD, Seattle, WA  
Thomas T. Teel, DDS, Fort Wayne, IN  
Thomas F. Trinkner, DDS, AAACD, Columbia, SC  
Eric Van Dooren, DDS, Antwerp, Belgium  
Marcos A. Vargas, DDS, Iowa City, IA  
Dennis J. Wells, DDS, AAACD, Brentwood, TN

## Features

- 38 Visually Speaking  
Words Cannot Express  
Everything ♦  
*Claude Sieber, MDT*
- 44 Clinical Essays  
1. Minimum Intervention:  
Maximum Satisfaction  
2. Keeping It Real! ♦  
*Irfan Ahmad, BDS*
- 66 Myths vs. Realities  
Feldspathic Stacked Porcelain Veneers  
and  
Pressed Porcelain Veneers ♦  
*Dario Adolfi, DDS, CDT*  
*Mauro Fradeani, DDS*
- 82 Tips on Dental Photography  
A Picture is Worth....♦  
*Alessandro Devigus, Dr.Med.Dent.*
- 90 Translucency Determinants  
of Natural Teeth ♦  
*Jason J. Kim, CDT*
- 100 Minimally Invasive and Non-Invasive  
Ceramic Veneers ♦  
*Joachim A. Maier, MDT*
- 114 Springing from Diagnosis ♦  
*Alain Méthot, DMD*
- 126 Approaches to Smile Design (CE Article) ♦  
*Brian P. LeSage, DDS, FAACD*  
*Luca Dalloca, DMD, CDT*
- 148 AACD Self-Instruction  
Continuing Education ♦
- 150 Members' Exchange  
"Pearls" for Taking Portraits ♦  
*Bernard B. Villadiego, DDS*
- 150 Advertising Index



## Columns

- 8 Guest Editorial  
The Art and Science of Shade Match-  
ing in Dentistry—Is There Progress?  
*John M. Powers, PhD*
- 10 Up Front  
Color is Science ♦  
*Shigemi Ishikawa-Nagai, DDS, PhD*



## Imagine Increasing Your Annual Revenue By \$223,284 in 2012!

...or 137 new-patient calls in just 30 days ... or a 10-to-1 return on your marketing investment ... or a 30% increase in new patients/month!

These are actual Patient News client results reported to us by some of the more than 7,000 dentists who have used our proven Patient Acquisition & Patient Retention programs.

With both comprehensive dental marketing systems, we do the work and you get the rewards. Let us help you get similar results.



**Visit President Karen Galley  
& Vice President Joanne Bishop  
in Washington at Booth 422**

**PLUS...**

Sign up for Karen's course on  
Friday May 4, 9:15 AM – 12:15 PM

**Drive Double-Digit Business Growth**  
*Powerhouse marketing gurus share  
Fortune 500 insights*

*Speakers: Karen Galley,  
Ernan Roman, & Jaynie Smith*

**Increase revenue.  
Generate more  
new patients.**

**877.779.2767**

Print & Digital Solutions  
Acquire. Retain. Grow.

## Departments

**12** Behind the Cover  
**The Many Dimensions of Color** ♦  
*Ifan Ahmad, BDS*

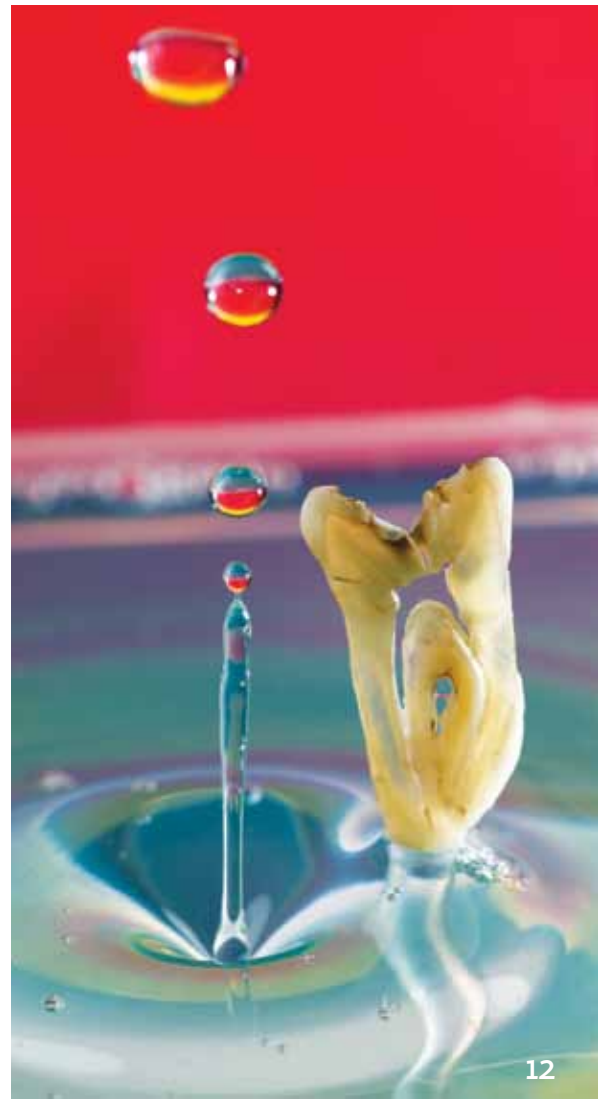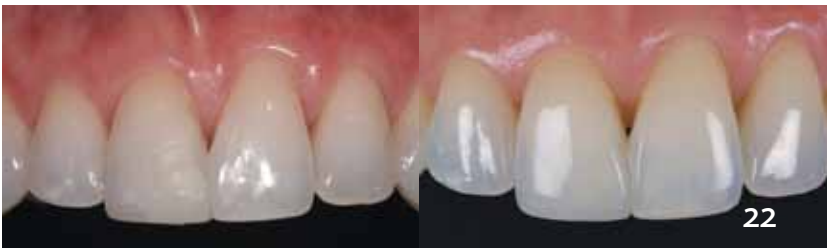**14** Give Back a Smile™  
**Hiding in Plain Sight** ♦  
*John S. Leite, PhD*

**22** Accreditation Essentials -  
 Clinical Case Type IV  
**Conservative Replication of  
 Nature with a Class IV Direct  
 Composite** ♦  
*Todd C. Snyder, DDS, AAACD*

**30** Examiners' Observations  
**Key Insights for Accreditation  
 Case Type IV** ♦  
*J.A. Reynolds, DDS, AAACD*

**32** Accreditation Tips  
**Stratification: An Essential Prin-  
 ciple in Understanding Class IV  
 Composite Restorations** ♦  
*Scott W. Finlay, DDS, FAGD, FAACD*

**36** Credentialing Announcement  
**"Class of 2012"**



### AACD MISSION STATEMENT

The American Academy of Cosmetic Dentistry is dedicated to advancing excellence in the art and science of cosmetic dentistry and encouraging the highest standards of ethical conduct and responsible patient care.



The *Journal of Cosmetic Dentistry*, ISSN # 1532-8910, USPS# 10452, published four times a year, January, April, July, and October. \$200 per year (U.S. & Canada) or \$240 per year (All other countries), single issues available upon request, by the American Academy of Cosmetic Dentistry®, 402 West Wilson Street, Madison, WI 53703. 800.543.9220 OR 608.222.8583. Periodicals postage paid in Madison, WI, and additional offices.

POSTMASTER: send address changes to:

*Journal of Cosmetic Dentistry*

American Academy of Cosmetic Dentistry

402 West Wilson Street

Madison, WI 53703

Peer-reviewed articles are denoted with the following symbol ♦

Statements of fact and opinion are the responsibility of the authors alone and do not imply an opinion on the part of the officers of the AACD. Materials may not be reproduced without written permission. Contents © 2012 American Academy of Cosmetic Dentistry®

The *Journal of Cosmetic Dentistry* maintains signed patient release forms for all articles featuring clinical or other patient photography.

Data on file. ©2012 DENTSPLY International.  
All rights reserved.



Academy  
of General Dentistry™  
CORPORATE SPONSOR

DENTSPLY  
CAULK

Only her dentist knows.

Now with  
Optimized  
Handling!



Restorations as real as the real thing.

Esthet•X® HD Restorative gives you the power to mimic nature. Our TruMatch® Shade Guide offers unmatched ability to predict and control the esthetic outcome of every restoration. And optimized handling and excellent polishability deliver life-like results for a beautiful smile that's as real as the real thing.

Visit [www.esthetxhd.com](http://www.esthetxhd.com) for your FREE sample today!

**ESTHET•X® HD**  
HIGH DEFINITION MICRO MATRIX RESTORATIVE

GET REAL.



# The Art and Science of Shade Matching in Dentistry: Is There Progress?



**John M. Powers, PhD**  
Professor of Oral Biomaterials,  
University of Texas School of  
Dentistry  
Dr. Powers is senior editor of  
The Dental Advisor.

Disclosure: The author is on  
the Executive Committee of  
SCAD.

**P**arameters of color are important aspects of the art and science of shade matching in esthetic dentistry. Our understanding of color science and color matching has progressed beyond that described by the pioneers.<sup>1-4</sup>

In addition to color, other attributes of the appearance of restorative materials can now be measured by instrumental and visual methods. We have new shade guides and other tools that make the shade-matching procedure easier and more predictable. There is also an education and training program available on color science and shade matching.

## Esthetic Properties of Restorative Materials

Color-related properties of restorative materials encompass color compatibility, stability, and interactions. In addition, translucency, gloss, fluorescence, and opalescence contribute to the appearance of restorative materials such as resin composites and ceramics. The effects of these parameters can be measured using scientific protocols and specialized equipment. But questions remain: Can resin composites placed in bulk provide the esthetics of layered composites? Can milled monolithic restorations, such as full-contour zirconium or lithium disilicate all-ceramic crowns, provide the esthetics of stacked or pressed restorations?

## Shade-Matching Tools

The VITA Classical Shade Guide (Vident; Brea, CA) has been considered the gold standard in dentistry for more than 50 years. Subsequently, the VITA 3D-Master Shade Guide was introduced. Today we have the VITA Linearguide 3D-Master for more rapid shade matching and the VITA Bleachedguide 3D-Master for tracking in-office tooth-whitening procedures. We should no longer be using the Classical Shade Guide to track changes in tooth-whitening studies.

Several hand-held shade-matching lamps with excellent characteristics complement the advanced shade guides. Two intraoral spectrophotometers are also available: Easyshade Compact (Vident) and SpectroShade Micro (MHT Optic Research; Niederhasli, Switzerland).

## Color Education and Training

The most recent resources for color education and training encompass a webinar by Goodacre and colleagues,<sup>5</sup> a book by Chu and colleagues,<sup>6</sup> ISO guidance on color measurement,<sup>7</sup> and the Dental Color Matcher.<sup>8</sup> The Dental Color Matcher is a free online education and training program for esthetic dentistry. It is designed to help improve the appearance and overall esthetics of restorations, color communication, and color reproduction.

**We have new shade guides and other tools that make the shade-matching procedure easier and more predictable.**

## REFERENCES

1. Clark EB. An analysis of tooth color. *J Am Dent Assoc.* 1931;18:2093-103.
2. Sproull RC. Color matching in dentistry. part I: the three dimensional nature of color. *J Prosthet Dent.* 1973;29:416-24.
3. Preston JD, Bergen SF. Color science and dental art. St. Louis: Mosby; 1980.
4. Paravina RD, Powers JM, editors. Esthetic color training in dentistry. St. Louis: Elsevier Mosby; 2004.
5. Goodacre CJ, Paravina RD, Bergen SE, Preston JD. A contemporary guide to color and shade selection for prosthodontics [DVD]. Chicago: American College of Prosthodontists; 2009.
6. Chu SJ, Devigus A, Paravina RD, Mieleszko A. Fundamentals of color: shade matching and communication in esthetic dentistry. 2nd ed. Hanover Park (IL): Quintessence Pub.; 2011.
7. International Organization for Standardization. ISO/TR 28642. Dentistry: guidance on color measurement. Geneva, Switzerland: The Organization; 2011.
8. Paravina RD. Dental color matcher: an online educational and training program for esthetic dentistry. Available from: [www.scadent.org](http://www.scadent.org).

## Society for Color and Appearance in Dentistry

SCAD was founded in 2008 as a consortium of dental professionals and other experts interested in the comprehensive, multidisciplinary investigation and application of color and appearance in esthetic dentistry. Its 4th Annual Conference will be held in Chicago on September 28-29, 2012. The meeting will feature evidence-based information presented by clinicians, laboratory technicians, and dental researchers. SCAD also publishes the *Journal of Color and Appearance in Dentistry*, a permanent semi-annual supplement of the *Journal of Dentistry*.



## PLEASE MEET SARAH

MRS. GLOBE MICHIGAN 2011

LK Dental Studio is proud to support the ongoing and tireless team efforts throughout the dental community to improve the lives of people in need. As the exclusive laboratory for the Women In Need Foundation (WIN) and the Mrs. Globe pageant contestants, LK Dental Studio assists the team at the WIN foundation to change lives while bringing gorgeous smiles to life.

As a participating dentist, Dr. Schindler supports the program with her exceptional dentistry. Together, we make a winning team.



## JOIN THE TEAM

AND BRING SMILES TO LIFE.

LAB WORK FABRICATED AND DONATED BY  
LK DENTAL STUDIO | DENTISTRY BY DR.  
SHARON SCHINDLER, COLUMBUS, OH



DENTAL **LK** STUDIO

LKDENTALSTUDIO.COM  
866-550-3522

Dentistry has no iron-clad standard or scientific basis for accurate color determination.

## Color is Science



Shigemi Ishikawa-Nagai, DDS, PhD  
Assistant Professor, Department of  
Restorative Dentistry and Biomaterials  
Sciences, Harvard School of Dental  
Medicine  
Board Member, Society for Color and  
Appearance in Dentistry

*Up Front* provides a forum for influential leaders to share their opinions. In this issue, we welcome Dr. Shigemi Ishikawa-Nagai, whose primary research interest and expertise are in color science in dentistry.

*Disclosure: The author did not report any disclosures.*

Although technological advances have significantly benefited dental medicine, one area of restorative dentistry has lagged behind. Color, a crucial aspect of esthetic dentistry, often has been treated as an art rather than as a science. Even at academic conferences, both dentists and dental technicians tend to focus more on the beauty of their work than on the science behind it.

However, in many other fields, color is considered a science. Engineers, for example, use spectrophotometers to analyze the color of materials such as paint, plastic, and fiber, utilizing reflectance values, absorption coefficients, and scattering coefficients.

In contrast, dentistry has no iron-clad standard or scientific basis for accurate color determination. Although dental shade guides have improved in the last decade, their results are still subjective, relying largely upon many factors, including the individual dentist's perception of color and the surrounding light conditions. It also is not uncommon for the actual color corresponding to the shade guide number to differ from one guide to another. In fact, studies show that perfect matches between tooth color and the shade tab are quite limited.<sup>1</sup>

Furthermore, the accuracy of color-measuring instruments available to dentists is often unreliable. Some dentists simply use point-and-shoot digital cameras to record and report color. These digital cameras are not designed to measure color, and their accuracy is sketchy. This problem is not limited to lower-quality cameras. Even when photographs taken by high-end single-lens reflex (SLR) digital cameras are analyzed in Photoshop® the only way to communicate color is through the red-green-blue (RGB) model. This is not acceptable in the 21st century.

The necessary modern technology is also lacking in many laboratories. Although dental spectrophotometers can accurately determine, analyze, and communicate color, that advantage is largely nullified due to the outdated color-matching process used on the ceramic restorations. In order to tailor the thickness and background color of the restorations to each individual case, technicians must rely on their own experience to reproduce the color on the restoration. There must be better laboratory techniques than the subjective, trial-and-error methods involving shade guides.

The solution is computer color matching, a technology widely used in other industries to analyze and formulate color. This objective method uses a spectrophotometer to measure tooth color and create a ceramic database by applying the Kubelka-Munk Theory of Reflectance.<sup>2</sup> Computer software can then calculate an individual "recipe" containing the specific thickness and background color for each case.

The field of dentistry has seen some tremendous advances in recent years. But we must realize that color science technology is still stuck in the last century. To move dentistry forward, there is an urgent need to develop a more scientific, precise methodology.

### References

1. Bayindir F, Kuo S, Johnston WM, Wee AG. Coverage error of three conceptually different shade guide systems to vital unrestored dentition. *J Prosthet Dent.* 2007;98:175-85.
2. Kubelka P, Munk F. Ein Beitrag zur optik der farbanstriche. *Zeits Techn Physik.* 1931;12:593-601. Available from: <http://web.eng.fiu.edu/~godavart/BME-Optics/Kubelka-Munk-Theory.pdf>.

# When No-Interest payments aren't affordable,

## Do you have an attractive alternative?

### Let's talk!

**Springstone Has No-Interest\* Plans PLUS the Best Rates\* for Extended Plans**

<b>Case Size</b>	<b>12 Month No-Interest Payment</b>	<b>Our Extended Plan LOWEST Payment</b>
\$5,000	\$417	\$102 60 mo. @ 7.99% APR*
\$10,000	\$834	\$181 72 mo. @ 8.99% APR
\$20,000	\$1,667	\$334 84 mo. @ 9.99% APR

- Fixed rates as low as **3.99% APR\***
- Terms to 84 months
- Plans to \$40,000

\* For plan details, please visit [springstoneplan.com](http://springstoneplan.com).

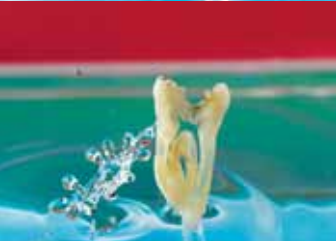
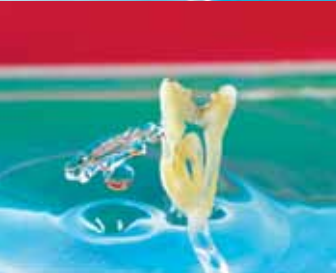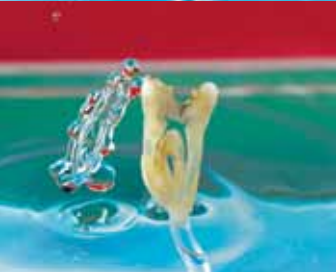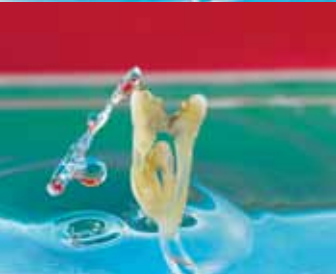**Call** 800-630-1663  
**Visit** [springstoneplan.com](http://springstoneplan.com)






BEHIND THE COVER

# The Many Dimensions





# of COLOR



The often-stated three dimensions of color—hue, value, and chroma (HVC)—are inadequate to describe the psychological perception of color, which is the subject of continuing philosophical debate. The sensual experience of color, however, is not limited to these three basic dimensions; but rather, incorporates many dimensions.

These include translucency, opalescence, fluorescence, reflectance, complementary chromaticity, “after images,” synesthesia, and color constancy. Artists such as van Gogh, Kandinsky, Miro, and Dali have exploited these dimensions to create exceptional works of art. The photographs here and on the cover exhibit more than just HVC; therefore, they communicate a sense of vitality, vividness, and vivacity.

In dentistry, merely using HVC is insufficient to convey a lifelike appearance. For a ceramic crown or composite filling to mimic natural teeth, it should also possess translucency, fluorescence, opalescence, and reflectance, among other qualities. It is encouraging to see that the monochromatic, “bright, white, right” porcelain smile makeovers of the last few decades are becoming a relic of dental history, being replaced by restorations that display vitality and lifelike characteristics similar to the natural dentition.

To read Dr. Ahmad’s two clinical essays, please turn to page 44.

*Cover photography: Irfan Ahmad, BDS. Cover images shot with a Leica S2 (Leica Camera AG; Solms, Germany), with a Leica Apo-Macro Summarit-S 1:2,5/120-mm lens. The camera was set at f/8 at two seconds, and images were captured in DNG (RAW) format. The images were not manipulated in any way; they appear here exactly as they were perceived by the camera’s digital sensor. The illumination was by two Metz mecablitz 54 MZ-4i digital compact flashes (Zirndorf, Germany).*



# Hiding In Plain Sight

Understanding and Working with  
Survivors of Intimate Partner Violence

John S. Leite, PhD

**Domestic violence is the leading  
cause of injury to women between  
the ages of 15 and 44.**



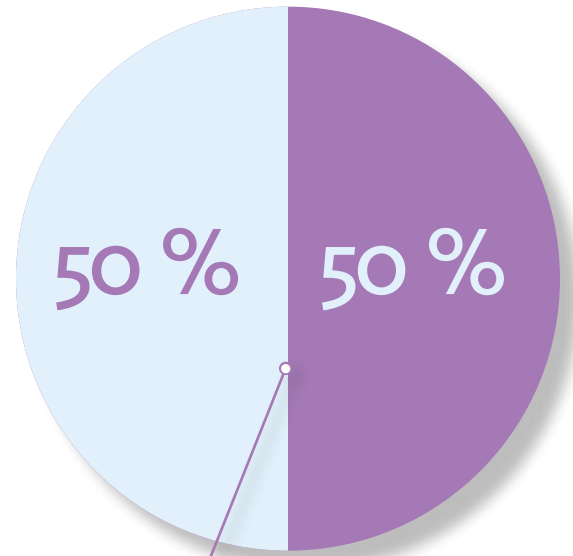
## Abstract

The incidence of domestic violence is at epidemic proportions in the United States. The American Medical Association (AMA) and the American Dental Association (ADA) have encouraged healthcare professionals to recognize and respond appropriately to signs of abuse in their patients. Many members of the AACD donate services to victims of domestic violence through the Give Back a Smile™ (GBAS) program. Working with domestic abuse patients provides the dental clinician with a unique challenge in understanding the psychology of abuse victims, staff/patient interactions, and expectations in regard to providing services to this population. This article will help dental professionals to understand the magnitude of the problem, the unique psychology of the abusive relationship, and how these dynamics can impact the behavior of patients in the provision of services.





# 5 million cases of domestic violence are reported each year.



## Introduction

The U.S. Centers for Disease Control recently released the results of an exhaustive government survey about rape and domestic violence against women in the United States. The data indicate that violence against women not only continues to be a major problem in our society but may also be far more common than previous researchers thought.<sup>1</sup>

What is domestic violence? It is a continuum of behaviors including physical violence, threats, intimidation, isolation, economic and financial control, and psychological and sexual abuse. Domestic violence cuts across all socio-economic levels, cultures, religions, sexual orientations, marital status, ages, and genders. Whereas women with money have more access to private healthcare resources and, as such, are underrepresented in statistics, poorer women tend to use community resources and thus are overrepresented in statistics.

## Statistics

More than five million cases of domestic violence are reported each year; approximately 85% of victims are female. One in five women report being raped, while one in four report being beaten by their partner. Domestic violence is the leading cause of injury to women between the ages of 15 and 44. Domestic violence accounts for 50% of all female deaths by homicide. In addition, 50% to 70% of abusers in domestic violence cases abuse the children living in their homes.<sup>2</sup>

## Dentists Can Help

The ADA and the AMA have encouraged healthcare professionals to recognize, treat, and respond appropriately to signs of abuse in the patients they encounter. This is especially pertinent to dentistry. Recent research indicates that dentists and dental hygienists are the least likely to suspect, intervene, and report domestic violence amongst all healthcare professionals.<sup>3</sup> This lack of awareness and action is especially surprising since dental professionals have a unique opportunity to observe and respond to indications of domestic violence in the patients they treat.

- ▶ Domestic violence-related female deaths
- ◀ Other female deaths by homicide

**50% to 70% of abusers in domestic violence cases abuse the children living in their homes.**



## Recent research indicates that dentists and dental hygienists are the least likely to suspect, intervene, and report domestic violence amongst all healthcare professionals.

The epidemic nature of domestic violence in our culture makes it critical that we develop an increased sensitivity to the signs and symptoms of abuse so that intervention and treatment are routine, rather than rare. Dental professionals have a unique opportunity to be at the forefront of this movement. Dentists develop strong, long-lasting relationships with their patients that can create a safe environment for personal disclosure. Dentists can also observe subtle changes over time that may suggest risk factors are present. Victimized patients can often be identified by their general demeanor and physical presentation as well as by their injuries.

Two out of three people in this country visit a dentist at least once a year. Ninety-four percent of victims of domestic violence have had head, neck, or facial injuries. Seventeen percent of rape victims who sought healthcare following the rape saw a dentist as part of the medical response to their injuries. Nine percent of women who sought medical care for assault by a domestic partner saw a dentist.<sup>4</sup> One national survey indicated that 87% of dentists never screened for domestic violence and only 18% screened when patients had visible signs of trauma on their heads and necks.<sup>5</sup>

### Evolutionary History of Domestic Violence

Emerging data from the field of evolutionary psychology and neurology has much to offer in helping us understand the pervasive enigma of domestic violence.<sup>6</sup> For thousands of years survival was a matter of violence. The evolved behavioral patterns, and neurological bases for them, that helped us survive in a much more threatening environment have led to many relationship dynamics that are exceedingly unhealthy.

Our brain's primary goals are survival and reproduction. While violence is abhorred today, violent males were valued in ancestral times for their protective function. Aggressive, ruthless men typically made the best warriors and leaders throughout human evolutionary history. Testosterone is a primary hormone related to violent behavior. Recent research has shown that women are more attracted to males with high testosterone features when they are ovulating than at other times in the menstrual cycle. This occurs at a subconscious level. It is as if our brain nudges us toward a selectiveness that made sense in prehistoric times but not today.

One barrier to women leaving abusive relationships is related to the paternity of her children. Research data reflects that the biggest threat to a woman's biological children comes not from the biological father but from a stepfather. Data indicate that the risk of injury or death to a child is 40 to 100 times more likely at the hands of a stepfather than from a biological father.<sup>7</sup> A woman's tolerance for a certain level of non-lethal violence in her mate may be the result of an evolved protective mechanism for children.

87% of dentists never screen for domestic violence.

Only 18% screened when patients had visible signs of trauma on their heads and necks.



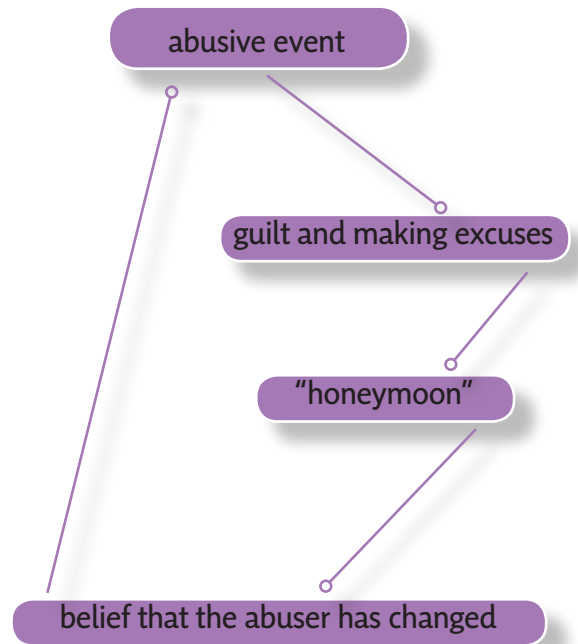
A woman's tolerance for a certain level of non-lethal violence in her mate may be the result of an evolved protective mechanism for children.

## The Cycle of Abuse

Many people, lay and professional alike, have a difficult time understanding how anyone could stay in an abusive relationship, and this may lead to negative attitudes toward such patients. Understanding this dynamic is critical in working empathically with people who have experienced domestic violence. Many abused women are their abuser's primary defender and frequently fall back on "but I love him" as their explanation for remaining in the abusive relationship without understanding that this is part of the cycle of violence.

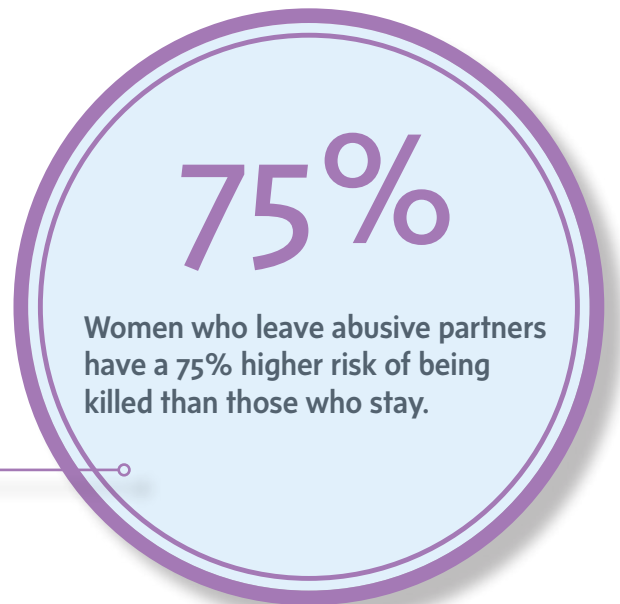### Stages

The first stage of the cycle, the *abusive event*, results in physical and dental injuries for which the victim may be urged to seek help. This is followed by the abuser feeling *guilt and making excuses*. In this second stage, the abuser either apologizes profusely, swearing it will never happen again, or blames the victim for the abusive event, thus creating self-doubt and anxiety for the victim. The third stage is the *honeymoon*, during which the abuser is very loving and kind, showering the victim with gifts to keep her in the relationship. The fourth stage involves the triumph of hope over reason, in which the victim *believes the abuser has changed* and frequently rejects professional help and intervention. However, the abuser has not really changed; he has simply paid "overhead" (i.e., the cost of doing business as usual). The belief that the abuser has changed leads the victim to trust the abuser again and thus creates the set-up for the cycle of violence to repeat itself with another abusive event.



## Obstacles to Leaving

A prevalent myth exists in the views of untrained clinicians as well as the general public that may hinder the further exploration or reporting of suspected abuse: It is the idea that women are easily able to leave an abusive relationship. Many see the decision to stay as a "choice" amongst other viable options, whereas, for the majority of women, there are significant reality-based blocks as well as powerful psychological blocks to leaving or taking any other action to protect themselves or their children. Many women report a fear of losing their children, rejection from family and friends, and the fear of being killed as reasons for staying with their abusers. This fear is well founded; data indicate that the most dangerous time for a woman in an abusive relationship is when she attempts to leave. Women who leave abusive partners have a 75% higher risk of being killed than those who stay.<sup>6</sup>



### Psychological Side Effects

The psychological side effects of ongoing abuse contribute to passivity, self-doubt, social withdrawal, and conflict avoidance. These side effects include depression, low self-esteem, anxiety, an impaired ability to trust, and fear of intimate self-disclosure. In addition, a fear of authority figures, such as healthcare professionals, makes it difficult for many women to confide in the very people who might be able to help them. Abusive partners frequently isolate their victims from family and friends who might support them and often control access to services that might help them. One reason many people see domestic violence as a problem more prevalent in the economically disadvantaged and not as one that affects

## **It is important to think of a survivor as someone who has used survival skills to cope with a threatening, traumatic environment.**

all socio-economic levels, is that most women who have limited financial resources and little social support simply have no place to go to escape the abusive relationship.

### **From Victim to Survivor**

When a person is able to escape the cycle of abuse and leave a violent relationship, the problems are hardly over. The psychological and physical abuse a victim experiences leaves deep wounds that are difficult to heal. A significant body of research indicates that women who are abused by their romantic partners are at high risk for the development of post-traumatic stress disorder (PTSD). The prevalence of PTSD among battered women is high, from 45% to 84%.<sup>8</sup> PTSD symptoms include intrusive re-experiencing of the violence (flashbacks or nightmares), avoidance, withdrawal, emotional numbing, hyper-vigilance, anxiety, and depression.

### **Coping Skills**

Survivors of domestic violence are frequently in a “danger mode” (e.g., high alertness and anxiety). Lack of concentration, impatience, and irritability are all common in this mode. Some neurological research suggests that exposure to chronic stress and the subsequent state of chronic physiological hyper-arousal and anxiety that occurs changes the hard-wiring of the brain and makes later behavioral change more difficult.<sup>9</sup>

It is important to think of a survivor as someone who has used survival skills to cope with a threatening, traumatic environment. What we tend to refer to as “symptoms” really need to be viewed as adaptations or coping skills. These coping skills, which enabled survival, continue long after the original threat is gone. Every “symptom” helped the victim survive in some way and provides security in subsequent life events and interactions with others, regardless of the presence of any threat.

### **Helping Survivors**

Survivor coping skills will significantly affect personal interactions, especially with strangers. Dental professionals working with the Give Back a Smile program provide a wonderful service to women who have been able to leave an abusive relationship and are attempting to rebuild their lives. However, the volunteer in the GBAS program remains a stranger and may have a hard time understanding the behavior of the abuse survivor. The patient may be suspicious, distant, have a flat affect, or show a lack of gratitude possibly bordering on a sense of entitlement. We all want to be appreciated for the things we do, especially those of us who volunteer our contributions. However, the normal “yardstick” just does not apply when working with trauma victims. The psychological wounds that occur from domestic violence and the resulting behavioral patterns can take years to resolve.

It is important for GBAS volunteers to remember that most patients, even those who have not been abused, feel vulnerable. This “normal” vulnerability can be a trauma trigger for a patient with an abuse history, regardless of how long ago the trauma occurred. One of the wonderful aspects of volunteering in GBAS is that these special patients typically

**A significant body of research indicates that women who are abused by their romantic partners are at high risk for the development of post-traumatic stress disorder (PTSD).**

**Every “symptom” helped the victim survive in some way and provides security in subsequent life events and interactions with others, regardless of the presence of any threat.**



have a highly positive outcome, as opposed to their previous history. The experience a survivor of domestic violence has in the Give Back a Smile program can be an important step on their road to recovery.

References

1. Study finds violence against women increases. Commercial Appeal. 2011 Dec 15. Available from: <http://www.commercialappeal.com/news/2011/dec/15/violence-against-women-increases/>.
2. Kessman J. Domestic violence, identifying the deadly silence. Texas Dent J. 2000;117(10):42-7.
3. The connection between dentistry and family violence intervention. Available from: <http://www.ojp.usdoj.gov/ovc/publications/bulletins/dentalproviders/pg3.html>.
4. Love C, Gerbert B, Caspars N, Bronstone A, Perry D, Bird W. Dentists' attitudes and behaviors regarding domestic violence. J Amer Dent Assoc. 2011 Jan;132(1):85-93.
5. Newton A. The dentist's role in domestic violence prevention. Available from: <http://www.agd.org/support/articles/?ArtID=3388>.
6. Kanazawza S. Why do some battered women stay." Available from: <http://www.psychologytoday.com/blog/the-scientific-fundamentalist/200804/why-do-some-battered-women-stay>.
7. Buss DM. The murderer next door. New York: Penguin Books; 2005.
8. DeJonghe ES, Bogat GA, Levendosky AA. Women survivors of intimate partner violence and post-traumatic stress disorder: prediction and prevention. J Postgrad Med. 2008 Oct-Dec;54(4):294-300.
9. What is physiological trauma? Available from: <http://www.sidran.org/sub.cfm?contentid=88&sectionid=4>. **jCD**



Dr. Leite earned his PhD from Virginia Polytechnic Institute and State University. He owns Cordova Psychological Associates, PLC, located in Cordova, Tennessee.

Disclosure: The author did not report any disclosures.

# Ultra Thin Ultra Conservative Ultra Beautiful

## Aurum's Cristal® Veneers


- As thin as .3 mm, based on your precise preparations.
- Exclusive veneering techniques allow for subtle changes in customized contour, fit or shade.
- Full palette of shades available.
- Incisals can be layered with translucent powders for exceptional esthetics.

Unmask the natural beauty of your patient's smile!

Visit us at [www.aurumgroup.com](http://www.aurumgroup.com)



IN NEVADA, UTAH, NEW MEXICO AND ARIZONA: 1-877-254-5334  
IN WASHINGTON, OREGON, MONTANA AND IDAHO: 1-800-423-6509  
OTHER NORTH AMERICAN LOCATIONS: 1-800-661-1169

 Designed and Manufactured in the United States



# IPS e.max<sup>®</sup> CAD from Aurum Ceramic

Experience the Beauty  
and Precision!

For aesthetically sensitive cases, no material performs like IPS e.max<sup>®</sup> CAD. No other laboratory can match Aurum Ceramic<sup>®</sup> in making the most of your IPS e.max<sup>®</sup> CAD restorations.

- A perfect fit in your practice... for strength, precision and aesthetics.
- Beautiful, durable monolithic all-ceramic restorations - Crafted by the leader in Comprehensive Aesthetic and Implant Dentistry.
- Unique optical techniques create the ultimate IPS e.max<sup>®</sup> CAD result.
- Milled utilizing Core3d Centres<sup>®</sup> digitally advanced, five-axis milling technology. Officially validated with Ivoclar Vivadent Inc.
- Indicated for everything from single units to full mouth aesthetic cases.



## See the difference for yourself!

Download our reprint of a Case Study (including laboratory/clinical protocols and pictorial review) to see the beauty and precision that can be achieved with IPS e.max<sup>®</sup> CAD milled by Core3d Centres<sup>®</sup>!

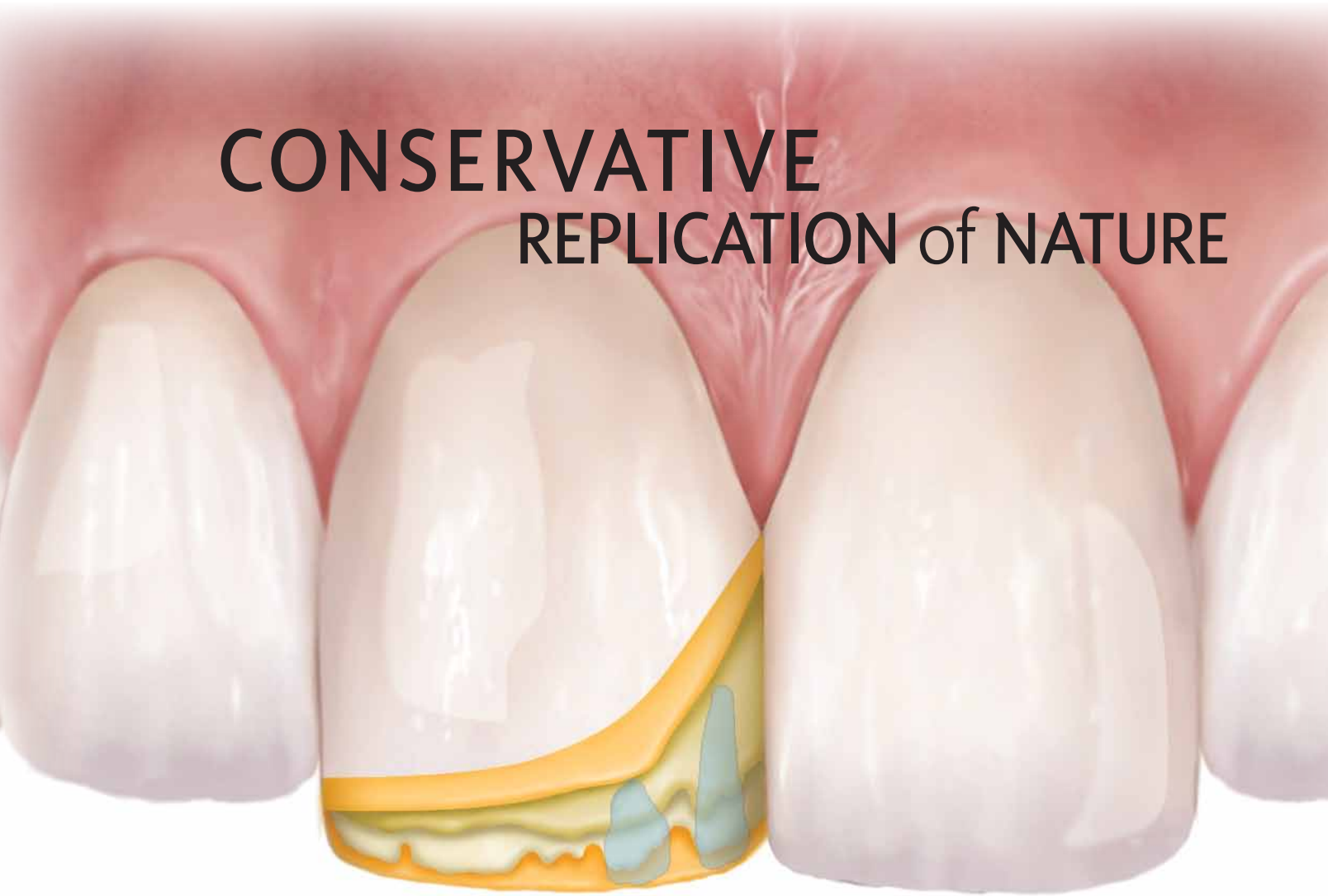

Visit [www.emaxfromcore3d.com/article](http://www.emaxfromcore3d.com/article)  
or Call Toll Free!

Visit us at [www.aurumgroup.com](http://www.aurumgroup.com)



# CONSERVATIVE REPLICATION of NATURE



// Cosmetic dentistry in the form of composite bonding is very similar to the craftsmanship imparted by art restorers. //

# with a Class IV Direct Composite

## Understanding Stratification to Emulate Nature's Optics

Todd C. Snyder, DDS, AAACD

Illustrations by Zach Turner

### Introduction

The ability to recreate historical artworks is considered by many to be almost impossible. However, after many years of training, art restoration experts can renovate and enhance works of art without many people being able to detect their work. Cosmetic dentistry in the form of composite bonding is very similar to the craftsmanship imparted by art restorers, maybe even more difficult, in that we try to recreate three-dimensional artwork—the color and translucency of teeth. The dentist, acting as an “art restorer,” attempts to recreate every nuance of that portion of tooth structure that is missing or damaged to appear as though nothing had ever occurred.

Cosmetically inclined dental patients have a myriad of treatment options available to alter and enhance the appearance of their teeth. The abundance of treatment and material variations allows for truly customized recreations and artistic interpretation, offering the clinician the ability to create amazing and often dramatic outcomes. The patient discussed in this article desired to conservatively restore the appearance of her existing teeth. The advantage of direct composite resin is that further removal of tooth structure is minimal. She wanted to whiten her teeth, replace the existing bonding on her fractured front maxillary central incisor (tooth #8), and modify the facial dimple on tooth #9.

## Patient History

A 44-year-old woman presented with a recent fracture on the mesio-incisal of tooth #8. Her previous dentist had recently inadequately restored the fracture (the bonding had failed within days of the initial restoration). She had gone back to the dentist on an emergency basis for the bonding to be redone. The dentist then placed a large bulk of composite with little to no finishing or polishing, simply to address the urgency of the disfigured tooth. The dentist told the patient she would have to return for them to finalize the procedure. She was very upset and sought out a new dental office for proper cosmetic treatment.

The patient was in good health with no medical issues. She had sealants and numerous posterior composites, but all of them appeared intact. There was a 2-mm overjet and 3-mm overbite with a Class I occlusion. The maxillary midline was shifted to the left approximately 3 mm and had a slight slant. The mandibular midline also was shifted about 2 mm to the left. Generalized gingival recession was present, along with some abfraction lesions in the posterior dentition. Radiographs showed no decay. An oral tissue assessment was performed visually and with the aid of a VELscope Vx (LED Dental; Burnaby, BC, Canada), which showed all tissue to be within normal limits. The temporomandibular joints had no pain-related issues; however, the patient did have some joint noise on her left side upon opening. We recommended that she have a nightguard fabricated to prevent potential joint deterioration and damage to her teeth and dental restorations.

## Diagnosis and Treatment

The patient presented with localized, mild periodontal disease, plaque and calculus, some inflamed tissue, and bleeding upon probing. She stated that she had had a cleaning within the past six months and did not want one at the present time. Mild fremitus was noted in the maxillary and mandibular anterior dentition. The obviously hurried, emergency composite was unsightly and needed to be replaced properly. Furthermore, the patient had a developmental dimple or pit on the facial of #9 (Figs 1-3). She had some recession due to trauma from occlusion, clenching, and parafunctional habits. Additionally, there were numerous black triangles between her teeth, in particular the interproximal of #8 and #9. However, the existing restoration did not extend through the contact so we did not address that problem. Improved hygiene may reduce inflammation and a slight enlargement of gingival embrasures. Additionally, #8 was noted as being slightly shorter than #9 due to poorly placed composite and apically positioned gum line (Figs 1-3).

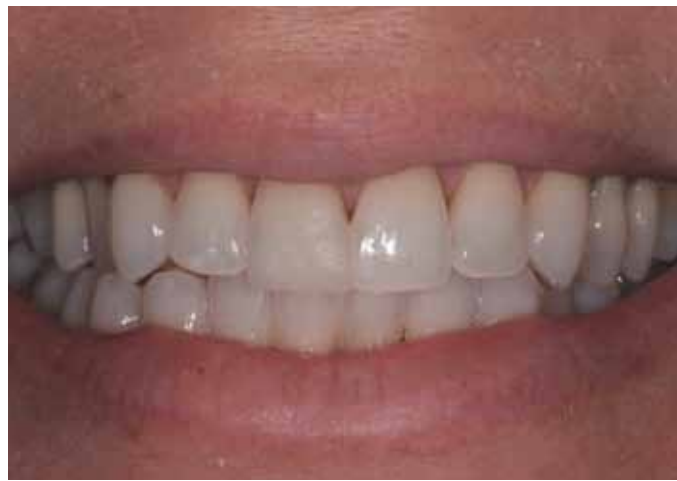

Figure 1: Preoperative image, 1:2 view.

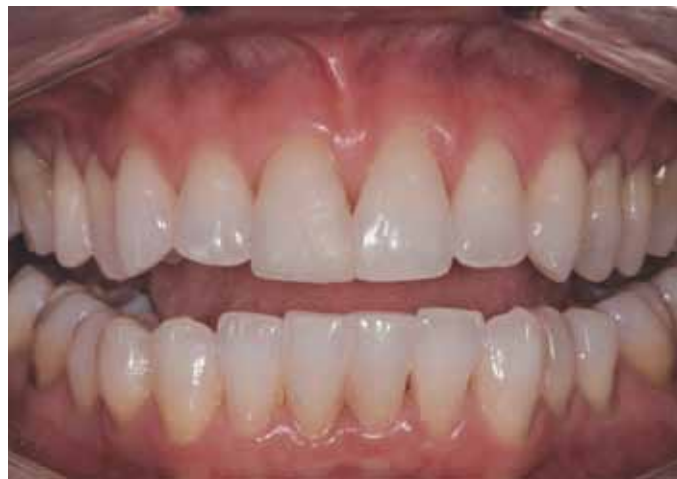

Figure 2: Preoperative retracted image, 1:2 view.

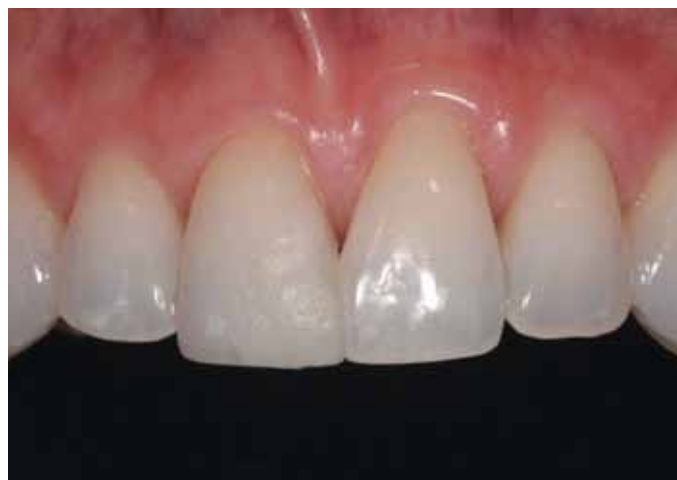

Figure 3: Preoperative image, 1:1 view.



The plan was to persuade the patient to have a thorough cleaning of the periodontal tissue prior to treatment. After stabilizing the periodontal tissue, the patient would be given a home whitening system. Upon completing the whitening we would allow the tooth color to stabilize for two weeks prior to replacing the failing bonding on #8 (mesial, incisal, facial, lingual), and the facial defect on #9.

## Treatment

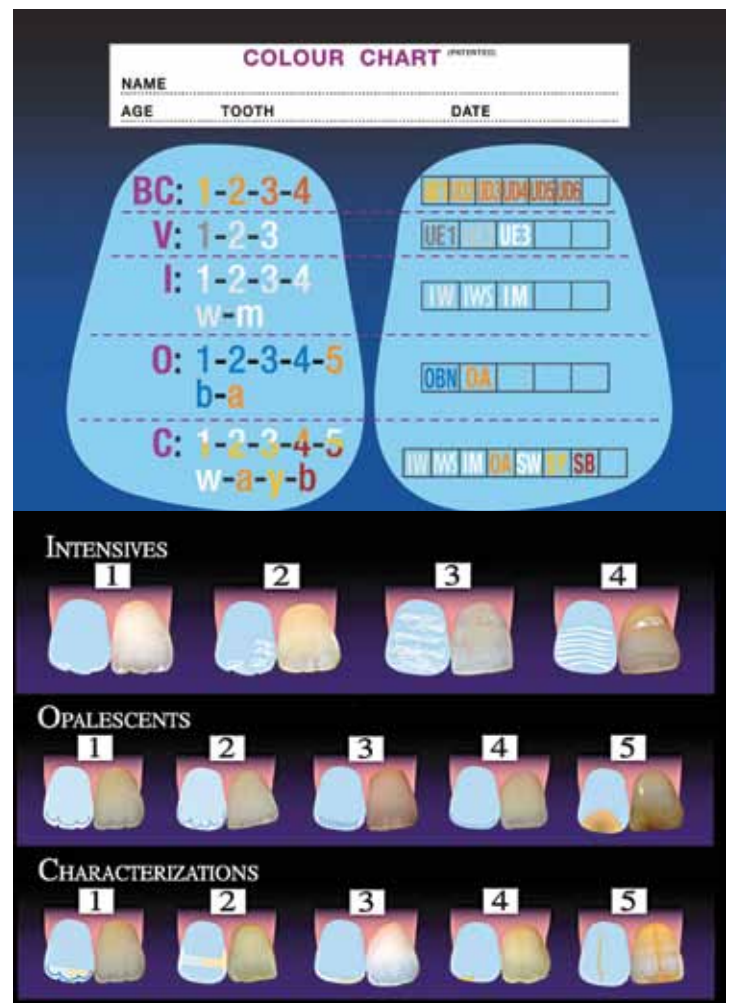
### Shade Selection

The front teeth requiring treatment were cleaned with a Piezon device (EMS Corp.; Nyon, Switzerland), followed by hand instrumentation and polishing with an extra-fine prophyl paste. Oral hygiene instructions were given in printed format to the patient. She then whitened her teeth for two weeks at home with a 15% carbamide peroxide gel custom whitening tray system (Mint Opalescence, Ultradent; South Jordan, UT). After she completed the home whitening procedure her teeth were allowed to stabilize for 10 days. Tooth #8 was anesthetized, (2% lidocaine w/1:100,000 epinephrine). Shade measurements were taken at this point utilizing the Optilume Trueshade (Optident; Ilkley, UK) device, which provides a constant color temperature of 5500K during illumination. Using the color chart (Fig 4) created and patented by Dr. Lorenzo Vanini (Micerium S.p.A.; Avegno, Italy), the various shades of composite necessary to complete the case were chosen, in addition to characterizations, opalescents, and intensives (tints). A color map was then fabricated indicating where each was to be placed (Figs 5 & 6).<sup>1</sup> Next, the various shades of composite material that had been chosen were applied to the tooth and cured to check their validity, as some color shifting can occur during polymerization. Black and white photography can also aid in the evaluation of value and translucency (Fig 7). Upon approval of the various shades of composite materials, the restoration work could begin.

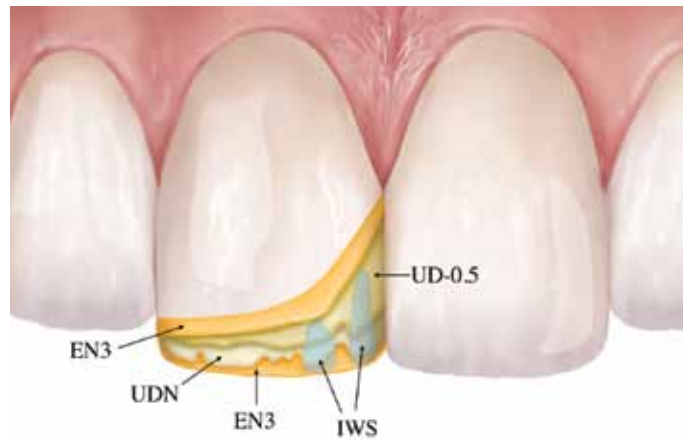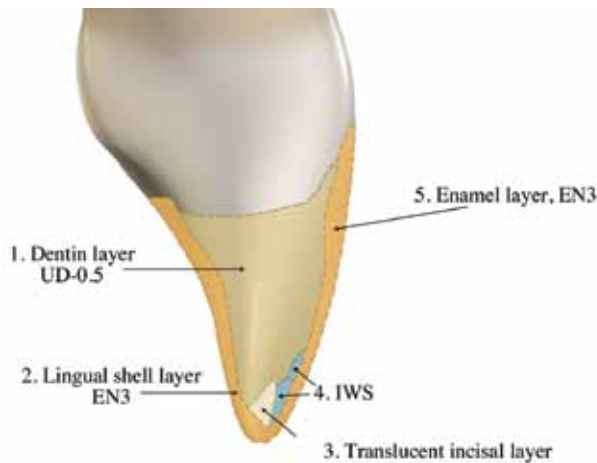
### Removal of Old Composite

The first step was to use diamond burs to remove all of the old composite restoration. A long bevel was not used, but rather a very small, short chamfer bevel was created on the facial margins only.<sup>2</sup> This was followed by air abrasion (Crystal Mark Inc.; Glendale, CA) of the preparation and beyond the margin slightly to clean off any debris and prepare the enamel surface for bonding. This also creates additional micro-mechanical retention to assist with long-term bond strength (Fig 8).

// The abundance of treatment and material variations allows for truly customized recreations and artistic interpretation. //



**Figure 4:** Color chart (printed with permission from Dr. Lorenzo Vanini).



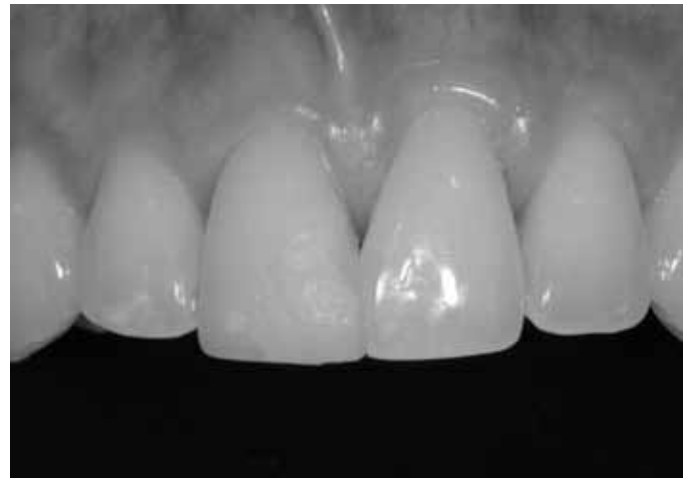**Figures 5 & 6:** A color map can be fabricated indicating where each shade of composite is to be placed.

### Enamel Etching

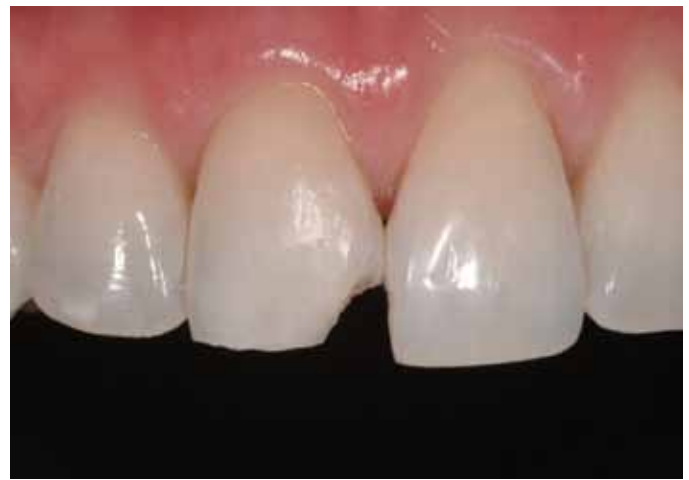Next, a clear mylar matrix was placed between the teeth to facilitate etching the enamel of #8 without etching #9. The prepared enamel was etched with 37% phosphoric acid (Bisco; Schaumburg, IL) for 15 seconds, rinsed for five seconds and dried lightly, leaving the surface moist.<sup>3</sup> This was followed by the application of Clearfil SE Protect per manufacturer's directions (Kuraray Corp.; Tokyo, Japan). The bonding agent and etchant had been chosen for their anti-matrix metalloproteinase (MMP)<sup>4</sup> activity in addition to their excellent physical properties. The clear mylar matrix was removed to allow direct contact of the composite to the adjacent #9. Waxed floss was carefully rubbed against the mesial contact of #9, taking care not to touch any portion of the adhesive surface or tooth structure of #8. This was done so that the composite could be built against #9 without creating a gap. The adhesion between #9 and the composite bonding on #8 would be minimal to nonexistent due to the protocol previously mentioned. Next, the missing dentin was replaced in the incisal third with a material that best approximated the current dentin tooth color and optical reflective/refractive index.<sup>5-7</sup>

### Composite Layering

ENA HRI (Micerium S.p.A.) shade UD-0.5 had been chosen as the dentin replacement. This was placed by hand, sculpting the missing dentin with a feathering effect toward the incisal and leaving adequate room in the mesial, facial, and lingual aspects for the enamel layer of composite to be added. This increment was cured for 40 seconds using the Optilux 501 halogen curing light (Demetron/Kerr; Orange, CA). The mesial, interproximal, and lingual areas were built out next with ENA HRI shade EN3 for the enamel



**Figure 7:** Gray-scaled image for value and translucency evaluation.



**Figure 8:** Preparation design after removal of existing composite.

layer. This layer was cured for 40 seconds. Space was left facially for additional composite layering, as the enamel replacement at this point was only to create the lingual portion of tooth and the mesial contact. Translucent areas were created facially along the mesial line angle and the incisal using ENA HRi UDN. ENA HRi IWS was used for some superficial white color enhancements along the incisal edge. The composite effects were then cured for 40 seconds. Every layer was placed by hand without the use of a stent, which was believed to be unnecessary due to the existing tooth structure remaining (stents, however, can be useful for larger cases).

The final layer of composite was placed to mimic the enamel shape and texture of the adjacent tooth using ENA HRi EN3. The overall contour of the restoration was achieved mostly during placement of the composite with hand instruments (Micerium S.p.A.) and brushes (#2 and a "rake," both synthetic, from the local crafts store) so that contouring with rotary instruments would be lessened. Some final contouring was accomplished with ENA diamond finishing burs. Additional final contouring on the lingual was done using 12 fluted, football-shaped finishing burs (Brasseler USA; Savannah, GA). The facial was finessed with various grits of finishing discs (Kerr/Hawe; Orange, CA). This was followed by ENA Shiny A and B diamond polishing pastes (3 $\mu$  and 1 $\mu$  respectively), which were applied using goat hair brushes, while Shiny C paste (aluminum oxide) was used last on a felt wheel to impart a final high shine.<sup>8,9</sup>

The dimple on #9 was treated next. Air abrasion was used again to roughen the tooth structure as well as to remove any plaque or debris. The dimple and surrounding area were etched, bonded, and cured in the same manner as previously mentioned. ENA HRi EN3 was used as a single increment to fill the small dimple. This was cured and polished in the same sequence of steps as #8.

After treatment was completed, the patient had a cleaning done by her regular dentist. Photographs of her teeth were taken a few weeks after the hygiene had improved (Figs 9-12).

## Summary

Restoring a defect in an anterior tooth can be one of the most difficult cosmetic procedures to perform in dentistry. The ability to recreate tooth structure using composite materials to achieve the same structural outline, morphology, and texture is very challenging. Additionally, the cosmetic dentist must mimic the same chroma, value, hue, and translucency; this re-

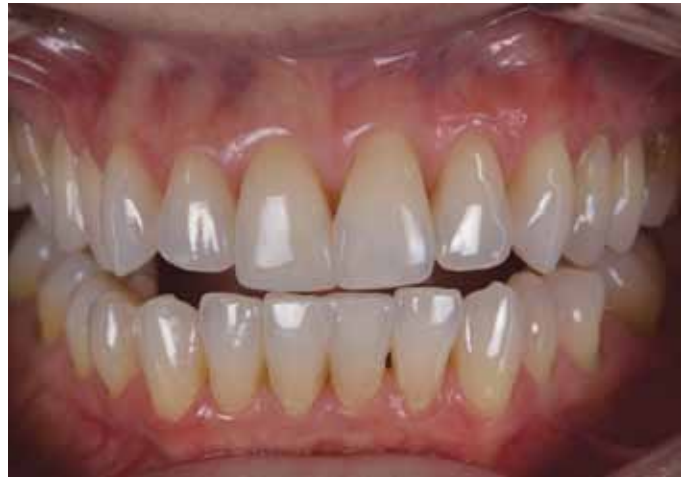

Figure 9: Postoperative retracted image, 1:2 view.

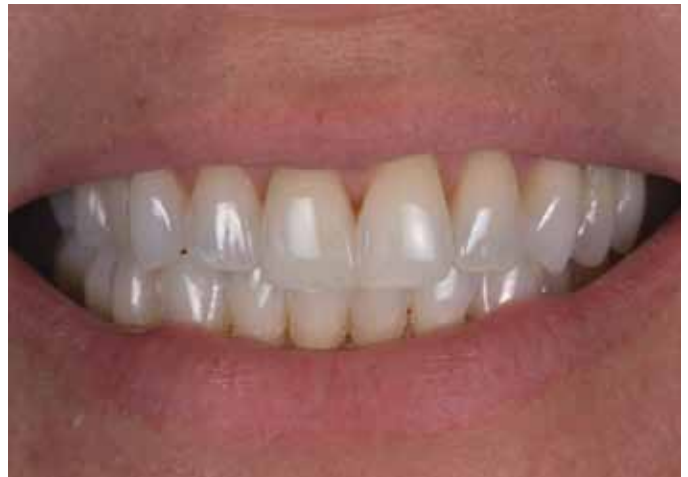

Figure 10: Postoperative image, 1:2 view.

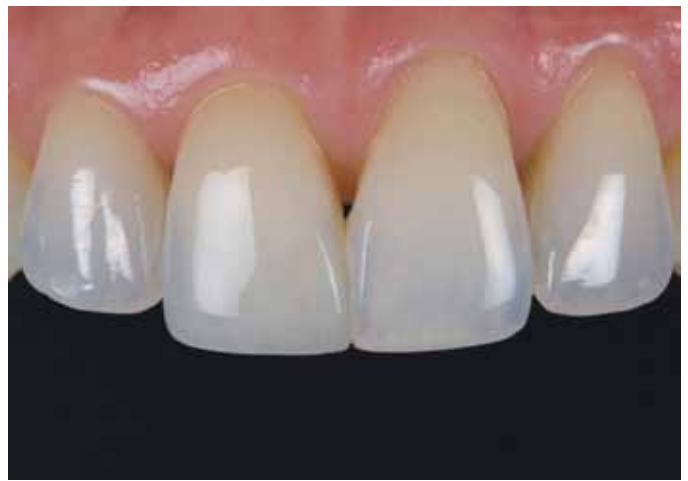
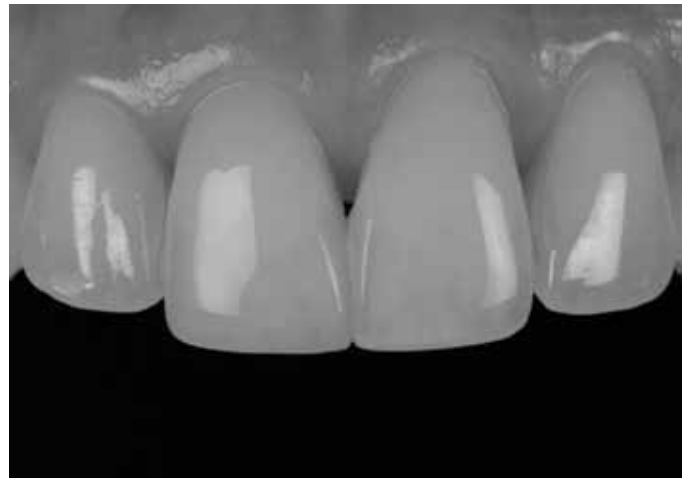
Figure 11: Postoperative retracted image, 1:1 view.

quires patience, proper color evaluation, and practice. Using bonding procedures in conjunction with modern materials, we can act as dental “art restorers” to enhance and recreate the lost appearance of a tooth, bringing back its original brilliance.

## References

1. Vanini L, Mangani FM. Determination and communication of color using the five color dimensions of teeth. *Pract Proced Aesthet Dent*. 2001;13(1):19-26; quiz 28.
2. Bargheri J, Denehy GE. Effect of enamel bevel and restoration length on Class 4 acid-etch retained composite resin restorations. *J Am Dent Assoc*. 1983 Dec;107(6):951-2.
3. Kanca J. Improving bond strength through acid etching of dentin and bonding to wet dentin surfaces. *J Am Dent Assoc*. 1992 Sept;123(9):35-43.
4. Pashley DH, Tay FR, Imazato S. How to increase the durability of resin-dentin bonds. *Compend Contin Educ Dent* [Internet]. 2011 Sept. Available from: <http://www.dentalaegis.com/cced/2011/09/how-to-increase-the-durability-of-resin-dentin-bonds>.
5. Buda M. Form and color reproduction for composite resin reconstruction of anterior teeth. *Int J Periodontics Restorative Dent*. 1994 Feb;14(1):35-47.
6. Fahl N, Denehy GE, Jackson RD. Protocol for predictable restoration of anterior teeth with composite resin. *Pract Periodontics Aesthet Dent*. 1995 Oct;7(8):13-21; quiz 22.
7. Terry DA, McLaren E. The interproximal zone: a Class III restoration. *Contemp Esthetics*. 2001;5(11):46-56.
8. Terry DA. Finishing and polishing for function, esthetics, and longevity. *Esthet Tech*. 2002;2:3-13.
9. Vanini L. Conservative composite restorations that mimic nature: a step-by-step anatomical stratification technique. *J Cosmetic Dent*. 2010; 26(3):80-98. **JCD**



**Figure 12:** Postoperative retracted image (gray-scaled), 1:2 view.

// The ability to recreate tooth structure using composite materials to achieve the same structural outline, morphology, and texture is very challenging. //



Dr. Snyder is an Accredited Member of the AACD. He practices in Laguna Niguel, California.

Disclosure: The author did not report any disclosures.





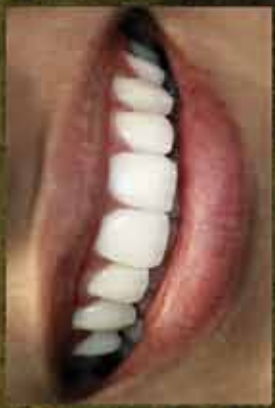smiles inc.

**BEYOND  
IMAGINATION**

**BRAD JONES FAACD**

One Of Only Four Ceramists In  
The World To Hold This Honor

***Second Tier Now Available***



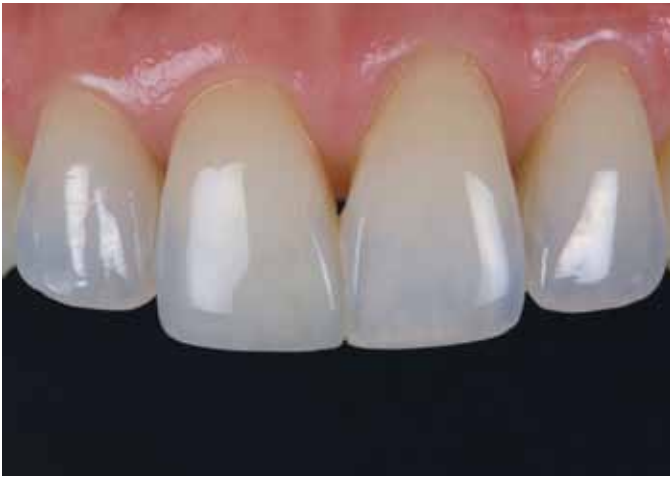[www.whoisbradjones.com](http://www.whoisbradjones.com)

888-259-9090

# Examiners' Observations

## Key Insights for Accreditation Case Type IV

J.A. Reynolds, DDS, AAACD



**Figure 1:** Retracted postoperative 1:1 view.

**“This case is all about the clinician’s skills.”**

Of the five case types required for members in the process (MIP), Types IV and V involve application of direct resin. Both test the MIP’s ability to conservatively obtain a seamless solution for various esthetic deficiencies. As the MIP is working through these cases, special attention must be given to creating natural depth of color and translucency along with mimicking the natural texture and luster of the surrounding natural dentition.

Case Type IV is an anterior direct resin case that can be defined as a diastema closure of greater than 1 mm or a Class IV fracture repair involving at least 10% of the facial surface volume of any maxillary anterior tooth.

This case is all about the clinician’s skills. Dentists often enjoy the luxury of having a talented ceramist fabricate beautiful indirect restorations that make them heroes; however, with this case, the clinician stands alone. These direct resin cases are unique and sometimes challenging learning tools and the value of self-evaluation through the prescribed AACD photography is enormous.<sup>1</sup> It can be a humbling experience to critique one’s cases via digital photography. Case Type IV offers the individual the opportunity to demonstrate knowledge of natural tooth form...from the natural layering of the dentin and enamel to the appropriate surface effects needed to produce an undetectable restoration. There is a wide range of composite resins available in dentistry today and whichever material is chosen, familiarity with handling, polishability, translucency, and opalescence are a must.<sup>2</sup>



Five AACD Accreditation Examiners evaluate each case using a grading system whereby points may be deducted based upon specific criteria. These criteria are overseen by the American Board of Cosmetic Dentistry® and are used to make the process more objective.<sup>3</sup> Examiners are required to stay current with all Accreditation protocols and undergo intense calibration before each examination session. This calibration ensures a level “playing field.”

Dr. Snyder did an excellent job of meeting the expectations of the patient and examiners and the results were well within the “zone of excellence” that Accreditation exemplifies. As a result, his case passed unanimously with only minor deductions noted by the examiners (see side bar).

As previously mentioned, Case Type IV is mainly a test of the clinician’s ability to handle resin; therefore, many important factors of global smile design are not considered by the examiners. For example, in Dr. Snyder’s case, the two central incisors are far from symmetrical in length and there is a black triangle in the midline, yet no points were deducted.

Case selection is always important in navigating the Accreditation process successfully. Members in the process are not given extra credit for taking on difficult restorative scenarios. Dr. Snyder chose a relatively straightforward Class IV fracture and knocked it out of the park.

## References

1. American Academy of Cosmetic Dentistry. Photographic documentation and evaluation in cosmetic dentistry: a guide to Accreditation photography. Madison (WI): The Academy; 2009.
2. Fahl N. Jr. A solution for everyday direct restorative challenges. *J Cosmetic Dent.* 2010 Fall;26(3):57-9.
3. American Academy of Cosmetic Dentistry. Diagnosis and treatment evaluation in cosmetic dentistry: a guide to Accreditation criteria. Madison (WI): The Academy; 2001. **jCD**

## Minor Deductions Noted:

- Criterion #43 focuses on proper development of line angles. An asymmetry exists on the mesial lobe of #8 as it relates to #9 (Fig 1). The reflective zones shown with the camera flash give rise to visual tension.
- Criterion #51 deals with proper management of the underlying tooth color as one is trying to blend the new resin material with the natural tooth structure. The restoration on #8 exhibits slightly more opacity and lack of linear translucency as compared to #9.
- Criterion #31 is all about presenting your case correctly and consistently photographically. Examiners look more favorably on cases that present with correct exposures, lighting, and composition. In his postoperative photographs, Dr. Snyder elected to use portrait-style lighting with softboxes, which can distort the visual appearance of the teeth. These shots are more artistic than diagnostic. Members in the Accreditation process are encouraged not to use this type of lighting.

**“Examiners are required to stay current with all Accreditation protocols and undergo intense calibration before each examination session.”**



Dr. Reynolds is an AACD Accredited Member and has been an AACD Accreditation Examiner since 2003. A 1981 graduate of the University of Tennessee, Dr. Reynolds practices in Franklin, Tennessee.

Disclosure: The author did not report any disclosures

# STRATIFICATION: An Essential Principle in Understanding Class IV Composite Restorations

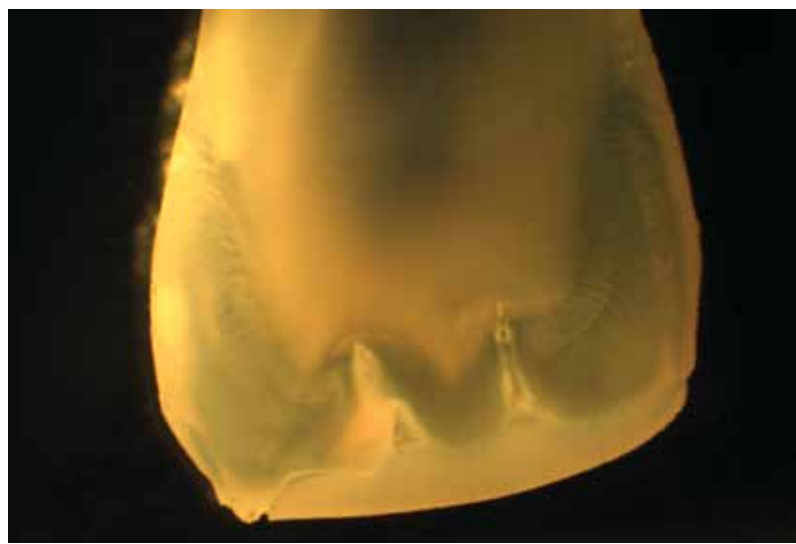
## Tips for Accreditation Case Type IV

Scott W. Finlay, DDS, FAGD, FAACD

### Introduction

Segmental restoration of teeth with composite resin is a common procedure and a valuable service to provide patients. This conservative restorative solution requires that a glass-reinforced resin blend invisibly with the adjacent tooth structure.<sup>1</sup> When we study the histological cross sections of natural teeth, we can appreciate the complexity of structure that we are trying to replace (**Fig 1**). Enamel is very crystalline, with specific—although varying—orientation. It has very little chroma, but does have a significant impact on how the light is reflected.<sup>2</sup> Dentin, on the other hand, is a very dense and amorphous layer that absorbs light and has the largest influence on chroma. In understanding the shades of teeth and attempting to restore what is missing, we want to use materials that are similar in their light-refractive qualities to the missing tooth (i.e., replacing dentin with a dentin substitute and enamel with an enamel substitute).<sup>3</sup>

Although there are limits to the correlation between the optical properties of natural tooth structure and resin, the conceptual application of the properties of stratification will go a long way in creating restorations that invisibly blend into the surrounding dentition. Most commercially available resin systems offer a series of resins that vary in opacity. Chromatic or achromatic enamel shades are the most translucent. Dentin shades are more opacous and have greater impact on the chroma of the tooth.<sup>4</sup>



**Figure 1:** The light-refractive properties of each of the layers of stratification within a natural tooth have an effect on the visual perception of shades and depth of color.

// The mastery of stratification is a key principle in the successful restoration of teeth with both resin and ceramic materials. //

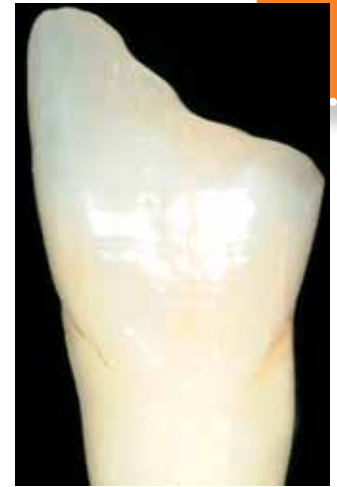

## Process

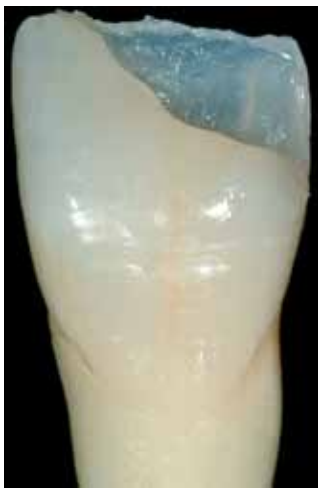A CLASS IV FRACTURE REQUIRES an understanding of the components of the optical properties of the adjacent tooth structure to create an invisible restoration (Fig 2). A series of two bevels is helpful in visually blending the cavo-surface into the surrounding tooth structure. The primary bevel involves the first 2 mm of the preparation. The secondary bevel continues from this point and tapers into the tooth's final facial contours (Fig 3).



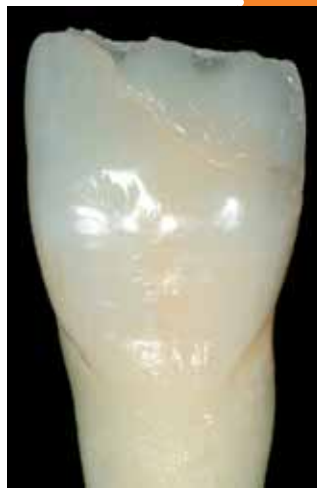**Figure 2:** It is necessary to understand the components of the optical properties of the adjacent tooth structure.



**Figure 3:** It is helpful to have two bevels to visually blend the cavo-surface into the surrounding tooth structure.



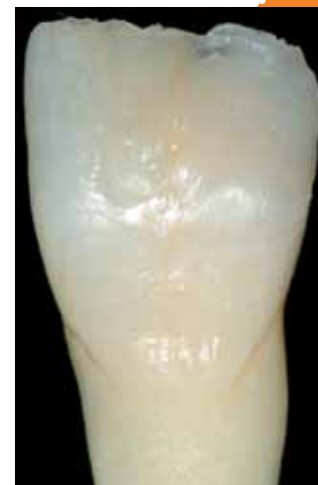**Figure 4:** A lingual shell of semi-translucent enamel shade composite defines the outline of the final tooth.



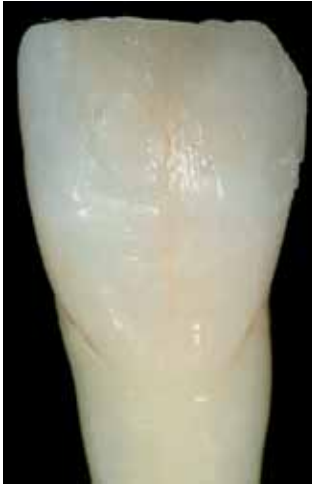**Figure 5:** A dentin shade is sculpted.

A LINGUAL SHELL OF SEMI-TRANSLUCENT ENAMEL shade composite defines the outline of the restored tooth. This is best developed utilizing a lingual putty stent created preoperatively from a diagnostic wax-up, or a composite mock-up intraorally (Fig 4). A dentin shade (which typically has the highest opacity in most resin systems) is then sculpted to reproduce the natural contours of the dentinal lobes observed in the adjacent tooth structure or adjacent teeth (Fig 5).

A CHROMATIC OR BODY SHADE RESIN is helpful in eliminating any visual recognition of the cavo-surface. This demarcation should disappear before the final translucent layer is applied. Also, if any maverick colors, fracture lines, or internal characterizations are to be applied, this must be accomplished during preparation of this layer (Fig 6).



**Figure 6:** A chromatic or body shade resin is helpful in eliminating any visual recognition of the cavo-surface.



**Figure 7:** A final layer of enamel resin is applied.



**Figure 8:** It is important to replicate the surface texture and polish that exist in the natural tooth surface.

A FINAL LAYER OF ENAMEL RESIN that mimics the translucency of the adjacent tooth structure is applied (Fig 7). Once the general contours of the tooth have been created, it is important to replicate the same surface texture and polish in the restorative material as exist in the natural tooth surface (Fig 8).

“The conceptual application of the properties of stratification will go a long way in creating restorations that invisibly blend into the surrounding dentition.”

The achievement of Accreditation requires a level of excellence that demonstrates a broad knowledge and skill set in the restoration of teeth to their natural state. The mastery of stratification is a key principle in the successful restoration of teeth with both resin and ceramic materials.

**Acknowledgment**

*The author thanks Lee Culp, CDT, AAACD (Lakewood Ranch, FL) for the use of Figure 2.*

**References**

1. Terry DA. Dimensions of color: creating high diffusion layers with composite resin. *Compend Contin Educ Dent.* 2003 Feb;24(2 Suppl):3-13.
2. Vanini L. Light and color in anterior composite restorations. *Pract Periodontics Aesthet Dent.* 1996 Sep;8(7):673-82.
3. LeSage BP. Aesthetic anterior composite restorations: a guide to direct placement. *Dent Clin North Am.* 2007 Apr;51(2):359-78, viii.
4. Villarroel M, Fahl N, De Sousa AM, De Oliveria OB Jr. Direct resin restorations based on translucency and opacity of composite resins. *J Esthet Restor Dent.* 2011 Apr;23(2):73-87. **jCD**



Dr. Finlay is an AACD Accredited Fellow and has been an AACD Accreditation Examiner since 2008. A 1986 graduate of the University of Maryland, Baltimore College of Dental Surgery, Dr. Finlay practices in Arnold, Maryland.

Disclosure: The author did not report any disclosures.

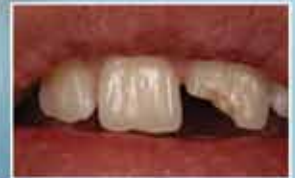

# BEAUTY, IT'S IN THE EYE OF THE BEHOLDER

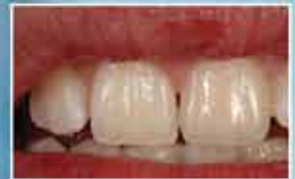Recreate natural beauty with Estelite Omega. Unleash the **MICHELANGELO IN YOU.**



## CLASS IV RESTORATION *Performed by Dr. Newton Fahl, Jr.*



BEFORE



AFTER

## ESTELITE OMEGA REDEFINING ESTHETIC RESTORATIONS.

Restorations that mimic the opalescence of natural teeth require a superior composite that emulates nature. Estelite Omega was developed in collaboration with Dr. Newton Fahl Jr., a world-renowned master in esthetic dentistry. Omega provides a full spectrum of opacities, with only 11 shades, for simpler restorative procedures. The answer is finally here for Clinicians that have yearned for the recreation of hue, chroma, and value with a simpler restorative composite.



**DR. NEWTON FAHL, JR.** - developed in collaboration with




**DO MORE WITH LESS** - 11 shades creates a full spectrum of opacities



**LONG LASTING POLISH RETENTION**



**1.3% LOW SHRINKAGE** with other advanced technical properties



**VISIT** [WWW.ESTELITEOMEGA.COM](http://WWW.ESTELITEOMEGA.COM)  
to register for specific courses and techniques.  
**CALL TOLL FREE: 888.698.3373**

**STOP BY BOOTH #613**  
**at the 2012 AACD MEETING**  
for EXCLUSIVE SAVINGS of up to \$200!



# AACD CONGRATULATES the Accreditation



ACCREDITED  
FELLOWS



Susan Hollar, DDS  
Arlington, TX  
Member since: 1990



C. Lee Wyant, DDS  
Little Rock, AR  
Member since: 1996



# "Class of 2012"!

*It is achievable!*

## ACCREDITED MEMBERS



David K. Chan, DMD  
Vancouver, WA  
Member since: 2001



Todd L. Cochran  
La Mesa, CA  
Member since: 2006



C. Kent Decker, CDT  
Clyde, NC  
Member since: 2007



Chiann Fan Gibson, DMD  
Naperville, IL  
Member since: 2004



Gesica T. Horn, DDS  
North Oaks, MN  
Member since: 2006



Phillip A. Kemp, DDS  
Brentwood, TN  
Member since: 2000



Lonnie Lee, CDT  
Oldsmar, FL  
Member since: 2008



Rebecca K. Pitts, DMD\*  
Lake Mary, FL  
Member since: 2001



Lauren J. Shanard, DDS  
Williston, VT  
Member since: 2004



Todd C. Snyder, DDS  
Laguna Niguel, CA  
Member since: 1996



Aliasger Tunkiwala, BDS, MDS  
Mumbai, India  
Member since: 2005



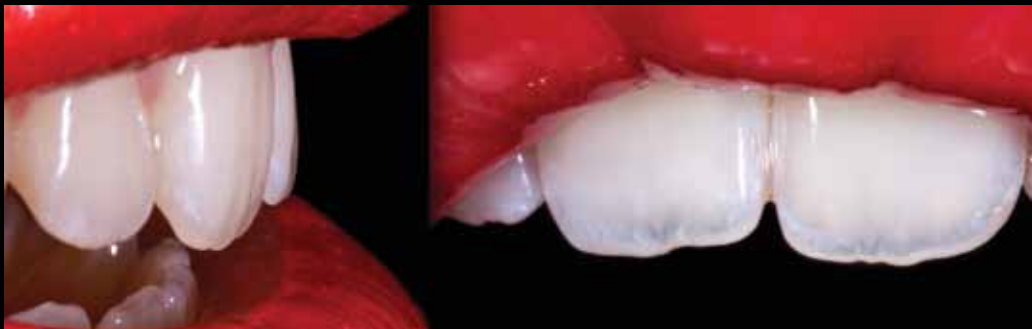Ossie R. Vereen, CDT, MDT  
Seattle, WA  
Member since: 1997

\*Dr. Pitts has just received her Accredited Laboratory Technician status. She achieved Accredited Dentist status in March 2007 and became an Accredited Fellow Dentist in December 2007.

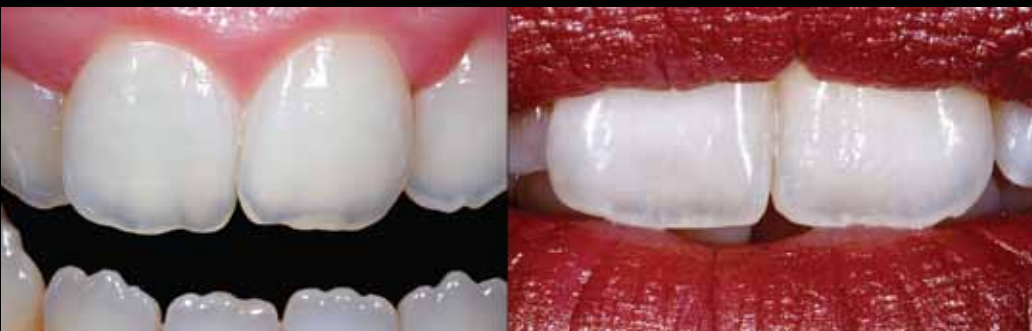# Words Cannot Express



Lips are the frame of the teeth



Natural beauty



Innate allure



# Everything

## Vision: The Art of Seeing The Invisible

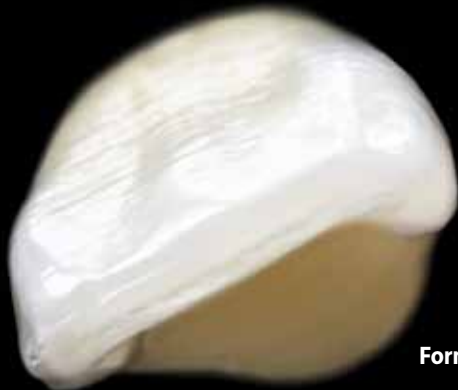Claude Sieber, MDT

**O**ur profession is constantly evolving, and we must be flexible in terms of accepting new techniques and technologies. Digital photography has become a great communication tool for dentists and laboratory technicians, enabling us to move at a faster pace and in a more accurate direction.

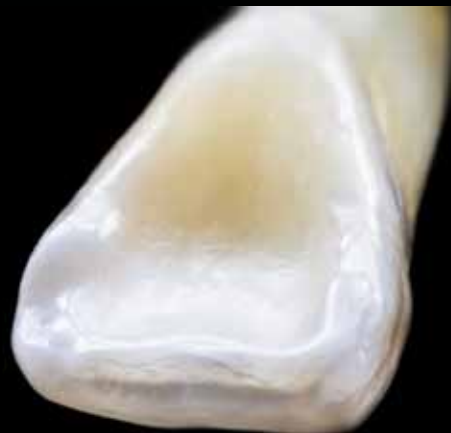Photography teaches us to see and observe light. Without adequate light, there is no image. Photographs can guide us through our work. The essential thing is to have a good eye and a steady hand.

Some people have limited skill but believe that machines can reproduce teeth with the same beauty that a human being can. But even the best camera needs a great photographer to produce beautiful images. Just as dentists still need and want a skilled technician, patients still need and want personalized dental work.

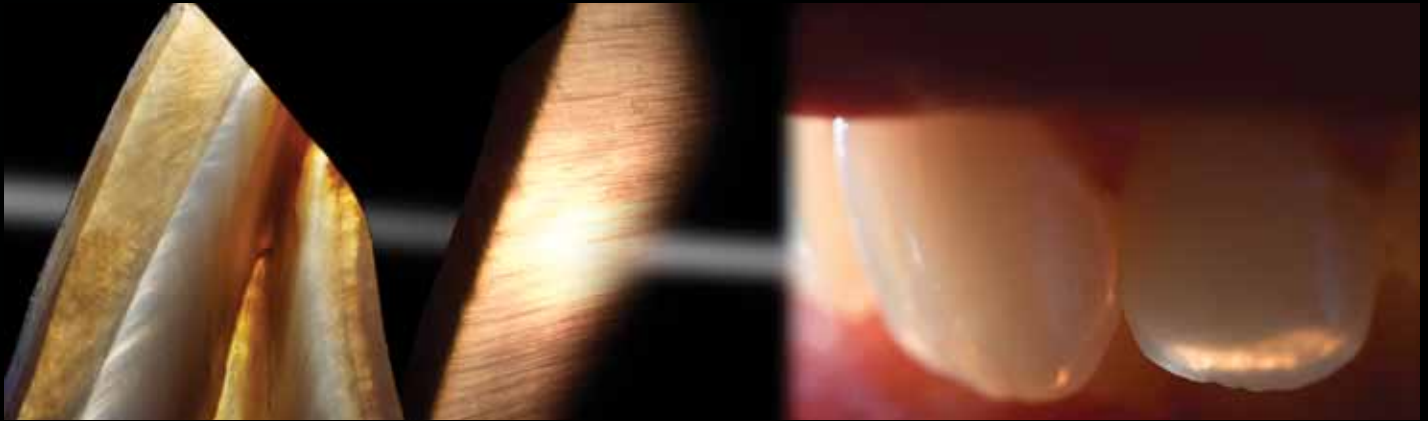
We should not lose individuality and emotion in our work; originality and creativity are essential. We must continue to observe and use our talents and knowledge to replicate nature.



**Form and surface**



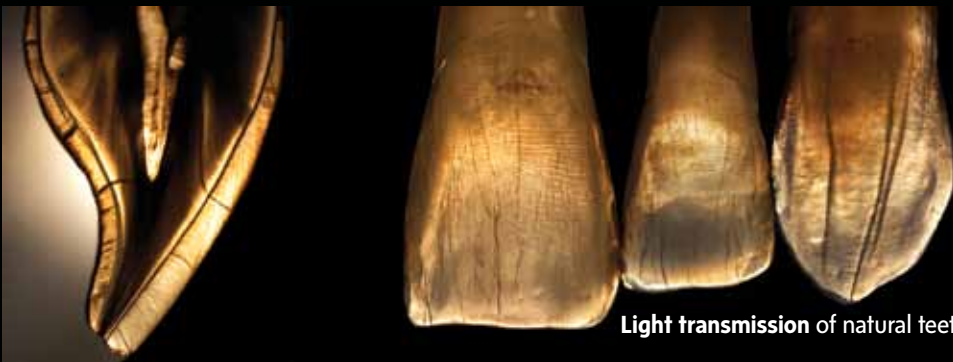*We should not lose individuality and emotion in our work;  
originality and creativity are essential.*



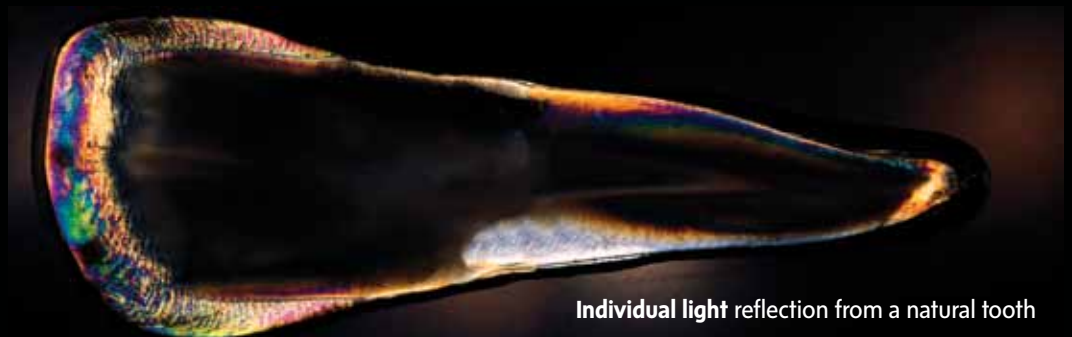**Opal effect**



**Inner structure**



**Light transmission of natural teeth**



**Individual light reflection from a natural tooth**

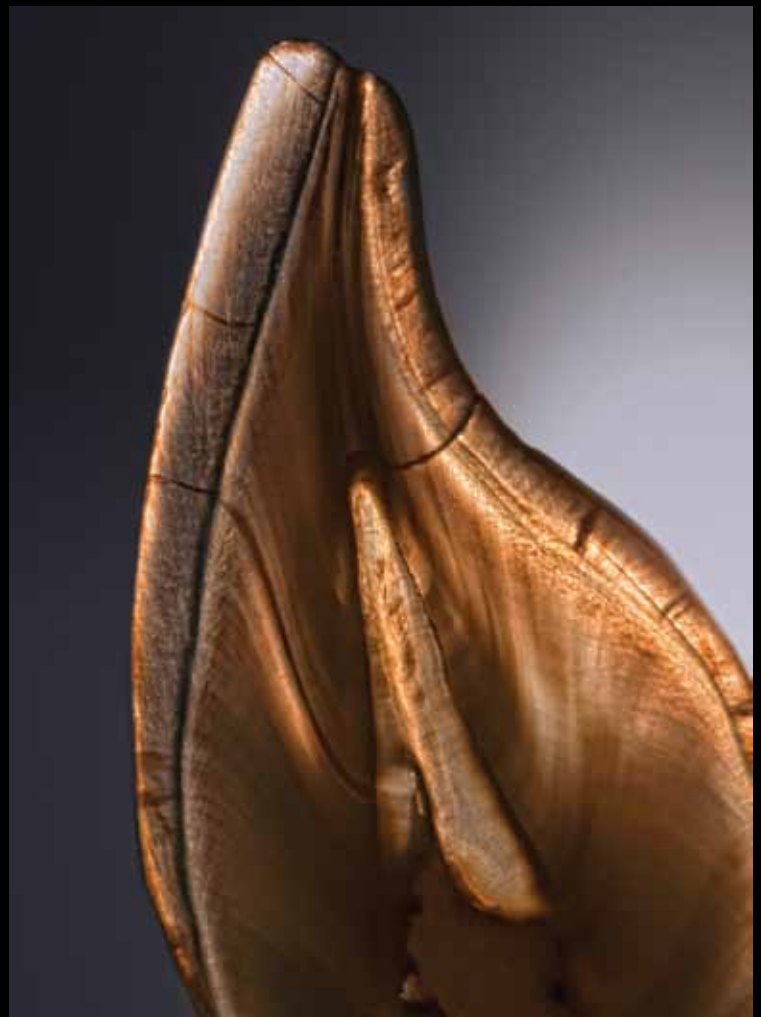
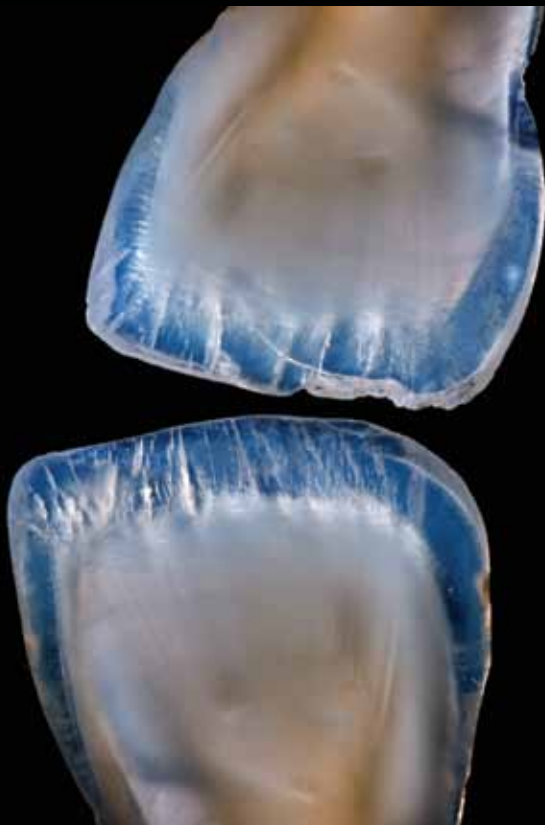
Inspired by nature



Stimulated by nature

Translucency and transparency



Opalescent effect of a cross-sectioned natural tooth



## VISUALLY SPEAKING

When it comes to dental esthetics and photography, new techniques offer new possibilities, but the same rule applies: If there is no light, you cannot expect good results. I try to demonstrate this fundamental truth during my lectures, and often people are very moved by the images presented.

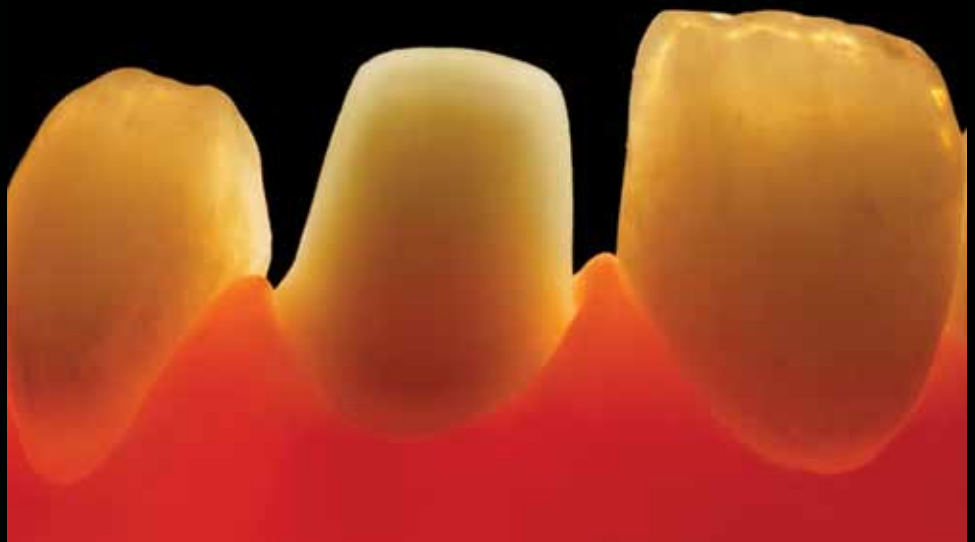
Ultimately, you have to believe in what you do. Additionally, you have to enjoy your work and demonstrate a passion for your chosen profession. Commitment and passion lead to satisfaction and success. Remember: Vision is the art of seeing the invisible.



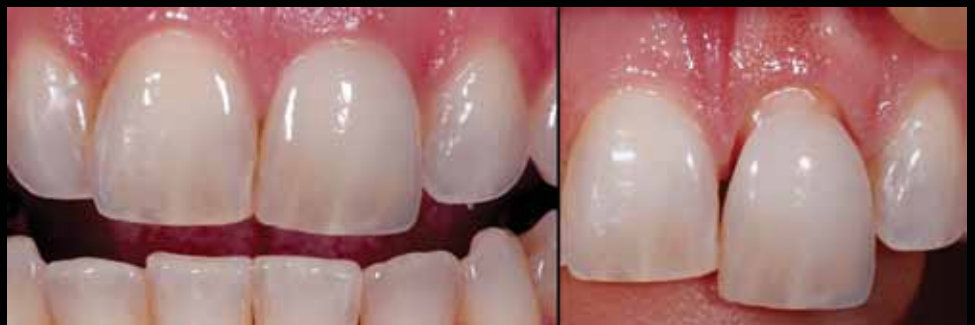Mr. Sieber owns a specialized dental laboratory and training facility dedicated to the advancement of expert dental ceramists in Basel, Switzerland. He teaches ceramics and photography. His Web site is [www.claudesieber.com](http://www.claudesieber.com)

Disclosure: The author did not report any disclosures.

Images © Claude Sieber.



**Light transmission** on an all-ceramic coping



**Single tooth restoration**

**Without emotion  
there is no beauty**





> THE SURPRISING CAUSES OF BAD BREATH



> HOW TO GET THE PERFECT SMILE FOR SPECIAL OCCASIONS



> MIRACLE SMILE MAKEOVER TREATMENTS

— THE ONLY —  
**BEAUTY MAGAZINE WITH  
 COSMETIC DENTISTRY  
 EDITORIAL**  
 — IN EVERY ISSUE —



**NEW BEAUTY**<sup>®</sup>  
**& AACD** | A BEAUTIFUL  
 PARTNERSHIP

To learn more, call 866-NEWBEAUTY or visit [www.newbeauty.com](http://www.newbeauty.com)

# minimum intervention, **MAXIMUM SATISFACTION**



- 
- Trauma during the period of mixed dentition is a frequent occurrence in children. ● ●



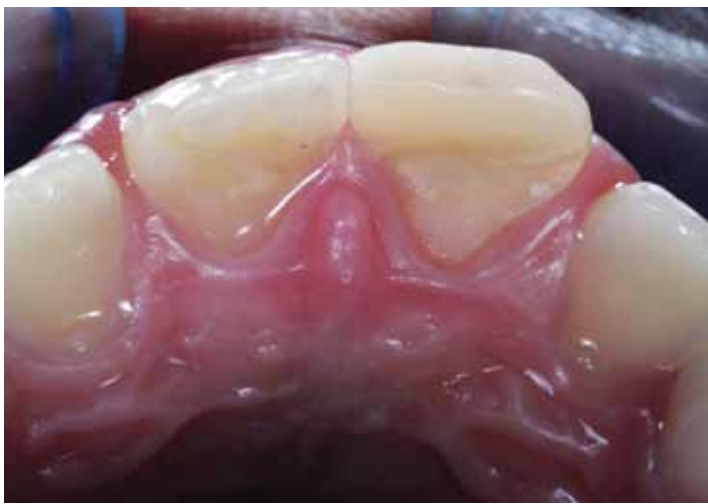
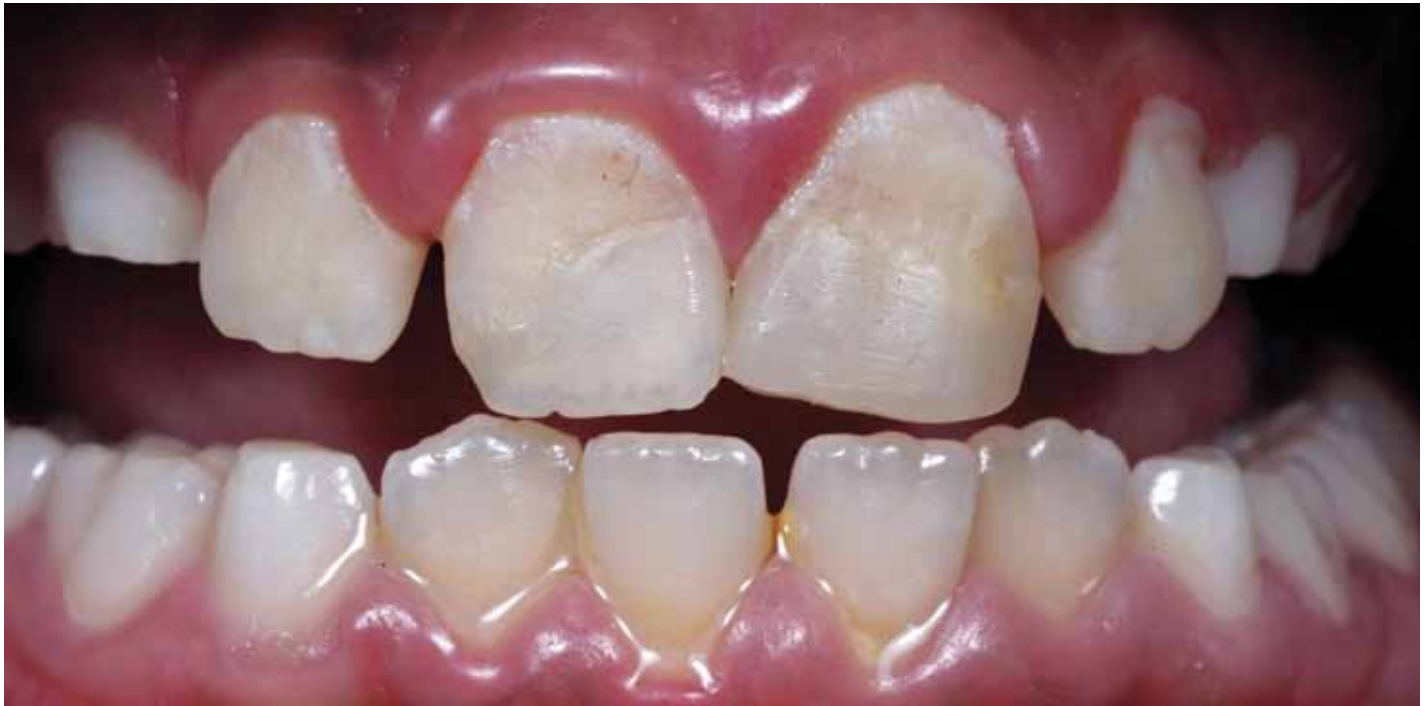
# Reconstruction Guided by a Fragment

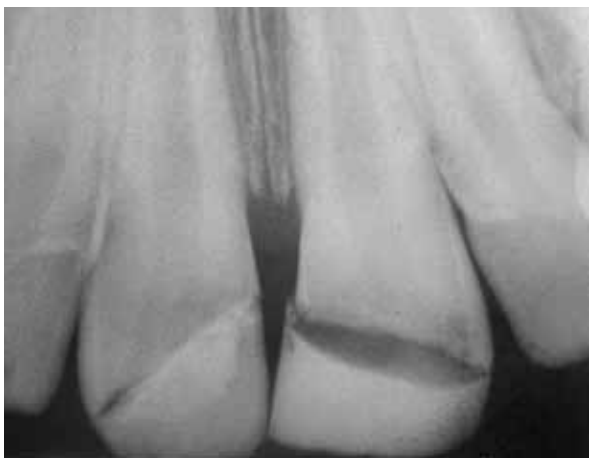Irfan Ahmad, BDS

## Introduction

Trauma during the period of mixed dentition is a frequent occurrence in children, usually involving the maxillary incisors.<sup>1</sup> In these circumstances, further preparation of the traumatized teeth for restorative reasons can be a case of “adding insult to injury.” The rationale for treatment should be a minimally invasive approach, including preservation and retaining as much natural remaining tooth abutment as possible.



**Figures 1 & 2:** The patient's fractured maxillary central incisors.



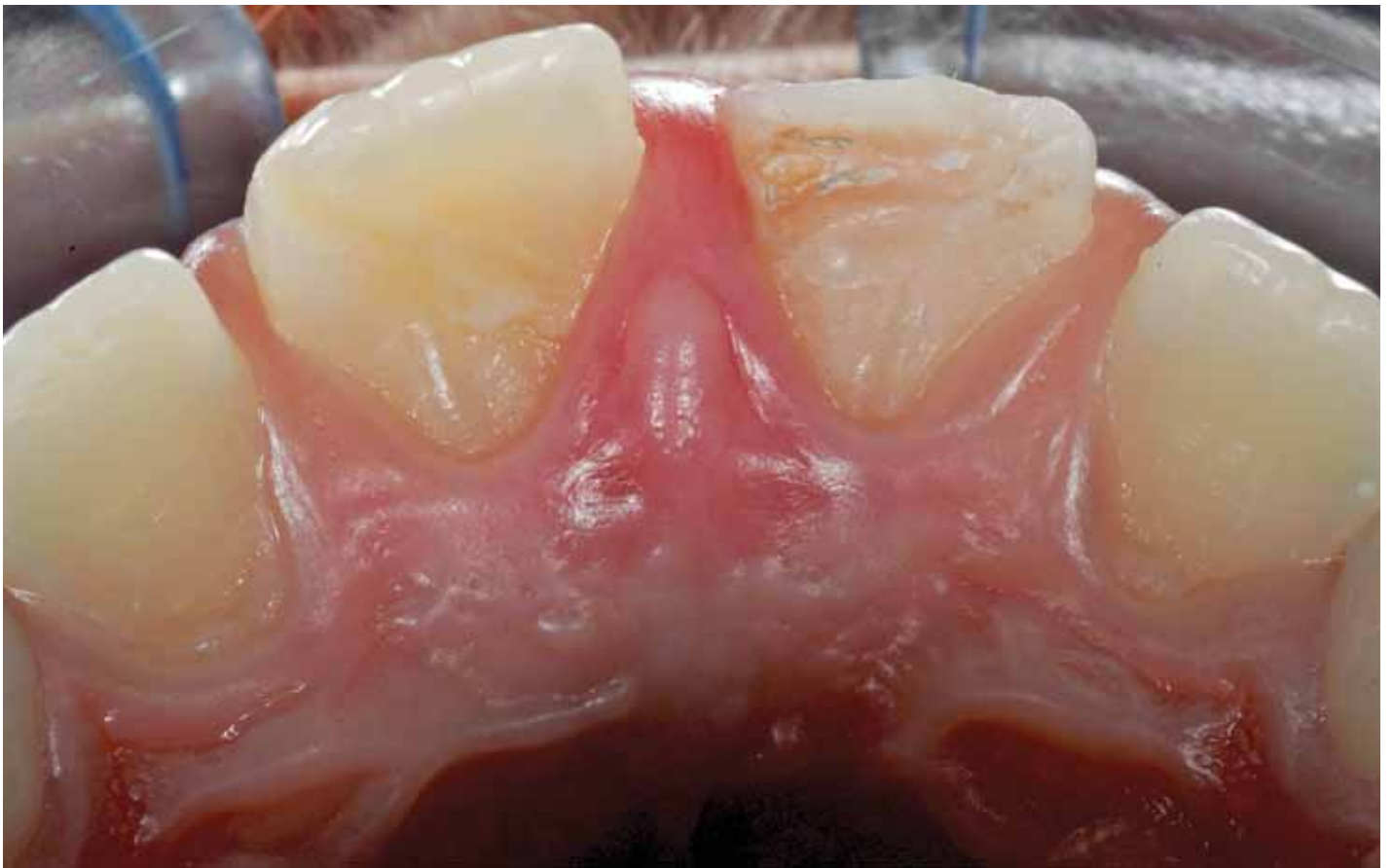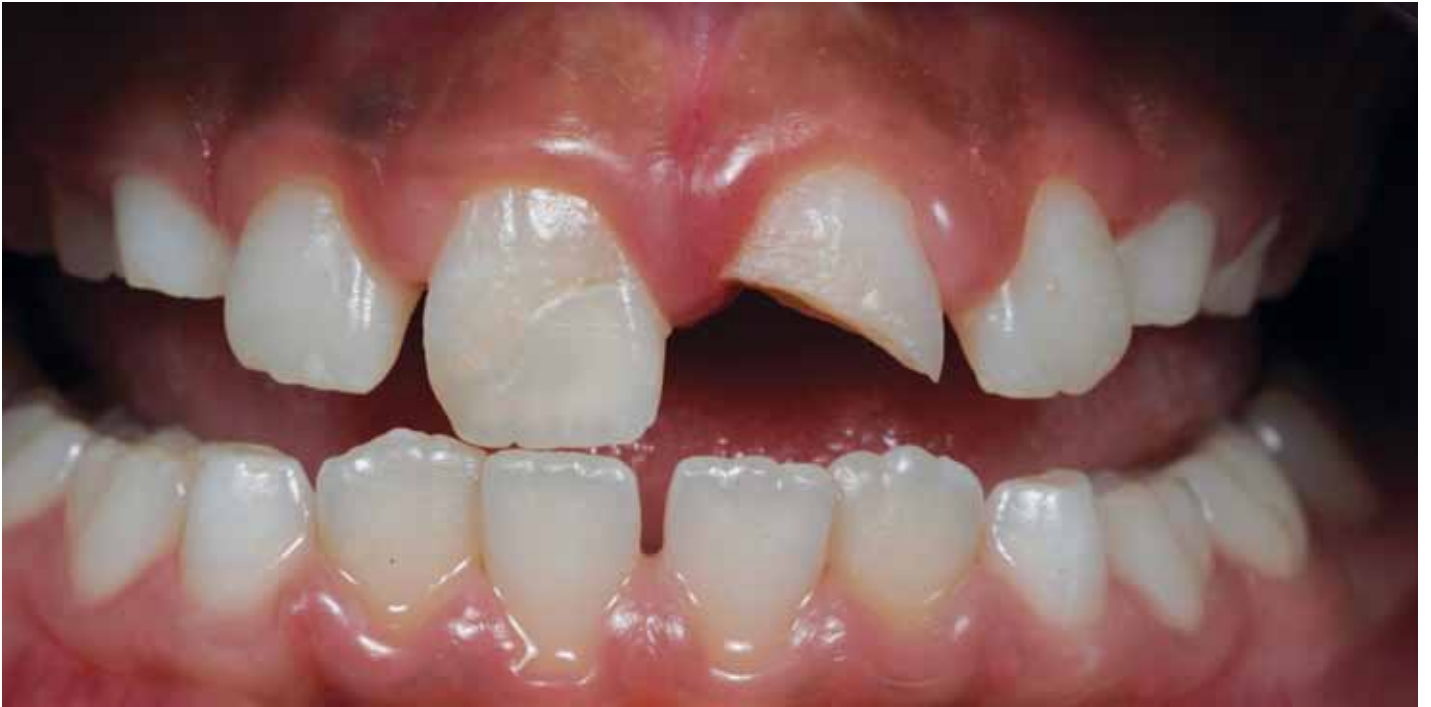**Figure 3:** Radiograph showing poor adaptation of the composite fillings with the remaining tooth substrate.

### Patient History and Diagnosis

A 12-year-old boy presented with fractured maxillary central incisors (Figs 1 & 2). He went to the emergency department of a local hospital, where tetanus inoculation was verified and composite resin was used to reattach the right central incisor fragment and build up the lost incisal fragment of the left central incisor.

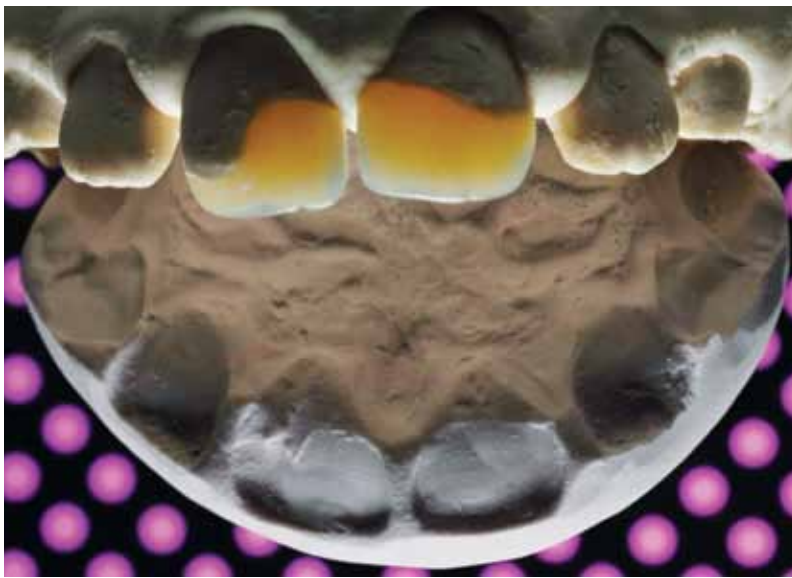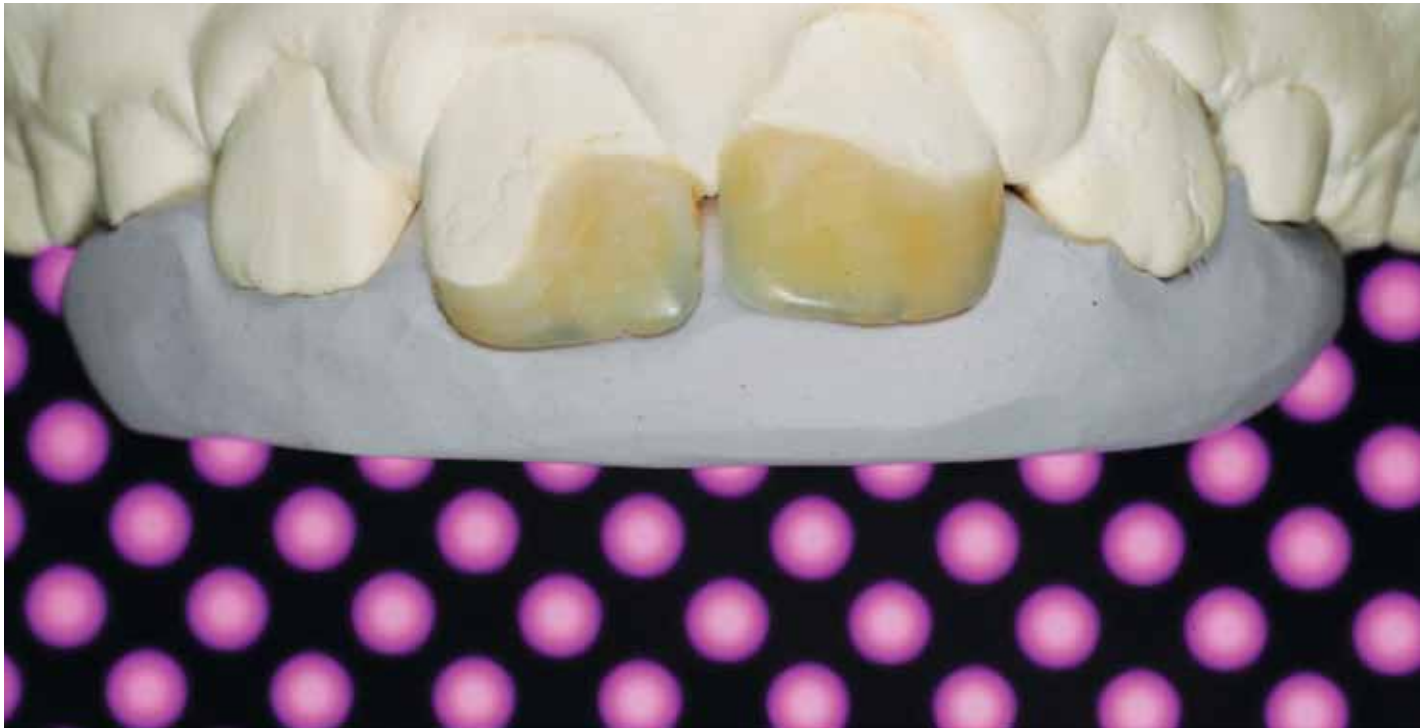
A subsequent radiograph showed poor adaptation of the composite fillings with the remaining tooth substrate (Fig 3). The periodontal ligament was intact, with no root fractures, and a typical solid cortical bone appearance consistent with acute dental trauma. Buccal palpation elicited tenderness at the apex of the left central incisor. However, root canal treatment was deferred to allow natural regeneration of the pulpal tissues (thermal vitality tests following acute trauma are futile due to transient paraesthesia of nerve fibers).<sup>2</sup>

A week later, after prophylaxis, gingival health was evident, and the left composite filling had dislodged. The buccal tenderness associated with the left central had subsided, and the exposed dentin was sealed with a dentin-bonding agent. Notice the mamelons, incisal halo, and translucency of the reattached incisal tooth fragment on the right central incisor, which would serve as an excellent guide for characterization during the composite buildup on the left central incisor (Figs 4 & 5).



**Figures 4 & 5:** Gingival health was evident, and the left composite filling had dislodged.





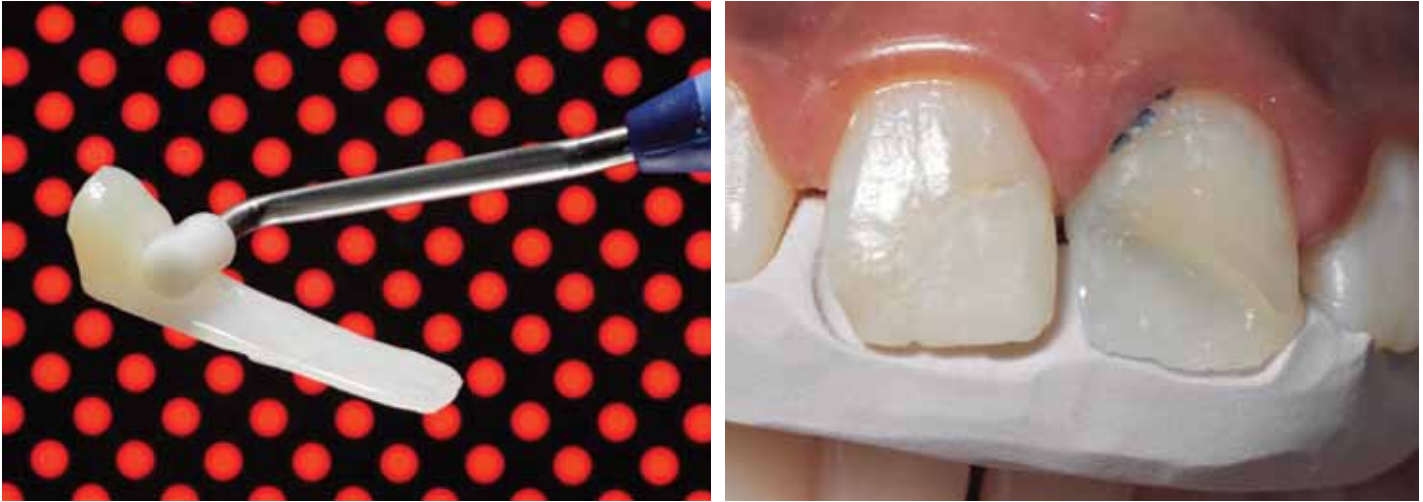
**Figures 6 & 7:** A maxillary median diastema was incorporated and a silicone index of the wax-up was sectioned.

## Treatment

A diagnostic wax-up is invaluable in assessing esthetics. In this case, a maxillary median diastema (which was present before the accident) was incorporated. A silicone index of the wax-up was sectioned,<sup>3</sup> ensuring that a ledge was present at the incisal edge to support the intraoral composite buildup (Figs 6 & 7).

A nanohybrid composite (Herculite Ultra, Kerr; Orange, CA) was chosen for its superior esthetic<sup>4</sup> and mechanical properties.<sup>5</sup> It allows excellent surface gloss after polishing, as well as advantageous optical properties such as translucency, opalescence, and fluorescence.<sup>4</sup> Using a rubber dam when building up anterior teeth, where esthetics are a paramount concern, can be disadvantageous due to excessive dehydration of teeth, making accurate shade assessment during incremental layering a challenge. Therefore, in this instance, isolation was limited to dry gingival retraction cord and judicial aspiration.<sup>6</sup> To preserve the maximum amount of remaining tooth substrate, preparation was minimal, limited to roughening of the fractured edge with a diamond bur. After application of the dentin-bonding agent, the silicone index was used as a template for the initial layer of incisal shade. The thickness of the initial layer depends upon the total buccal-palatal thickness of the tooth being treated and the anticipated thickness of the subsequent layers of composite. In this instance, the initial layer was rolled to a thickness of approximately 1 mm using a CompoRoller (Kerr) to build up the palatal aspect of the left central incisor (Figs 8 & 9).





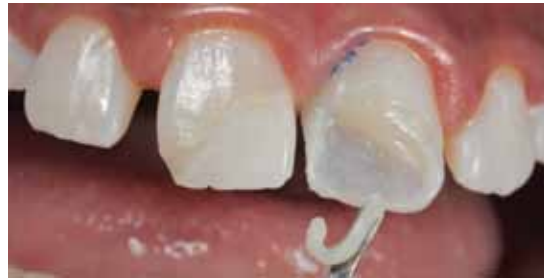**Figures 8 & 9:** A CompoRoller was used to build up the palatal aspect of the left central incisor.

A thin layer of composite (dentin shade A1) was placed at the incisal edge, incorporating the mesial and distal aspects to emulate the incisal halo effect (Fig 10).

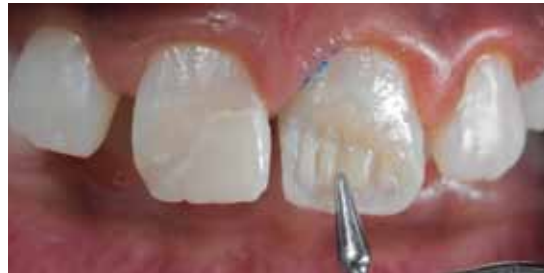A suitably shaped instrument was used to place dentin shade A2 for the mamelon effect within the coronal reconstruction of the left central incisor (Fig 11).

The final covering layers, enamel A1 and incisal shades, were sculpted with conical and cylindrical CompoRoller tips (Fig 12). The final contouring and finishing/polishing of the left central incisor buildup was postponed for one week, allowing evaluation of the shade and characterizations.

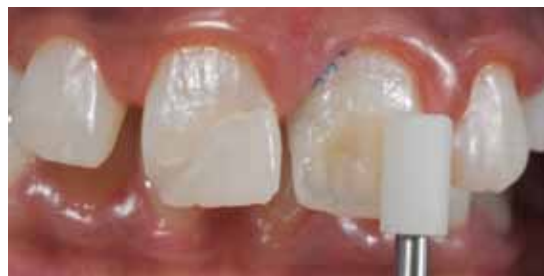Salvaged useable fragments of fractured teeth (Fig 13) are ideal for reconstructing teeth to their former morphology and esthetics and, of course, preserving natural tooth substrate. However, if the remaining intraoral tooth substrate has discolored due to breakdown of the pulpal blood vessels, there may be a color transition between the tooth and the reattached fragment. Depending on the amount of remaining tooth, this is usually not a concern since the cervical aspects of teeth are darker than the incisal parts. To improve fracture resistance, reattached fragments should be rehydrated in saline for 30 minutes prior to bonding with the remaining intraoral tooth substrate.<sup>7</sup> In this case, the silicone index was used to verify location, and the fragment was “linked” to the remaining tooth abutment with an incisal shade composite on the palatal aspect.



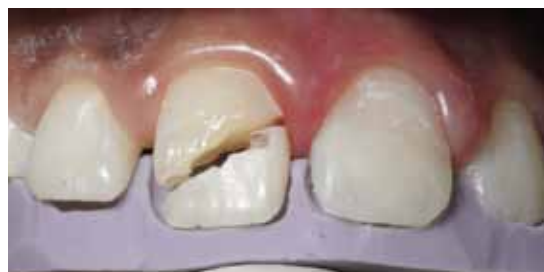**Figure 10:** A thin layer of dentin composite was placed at the incisal edge.



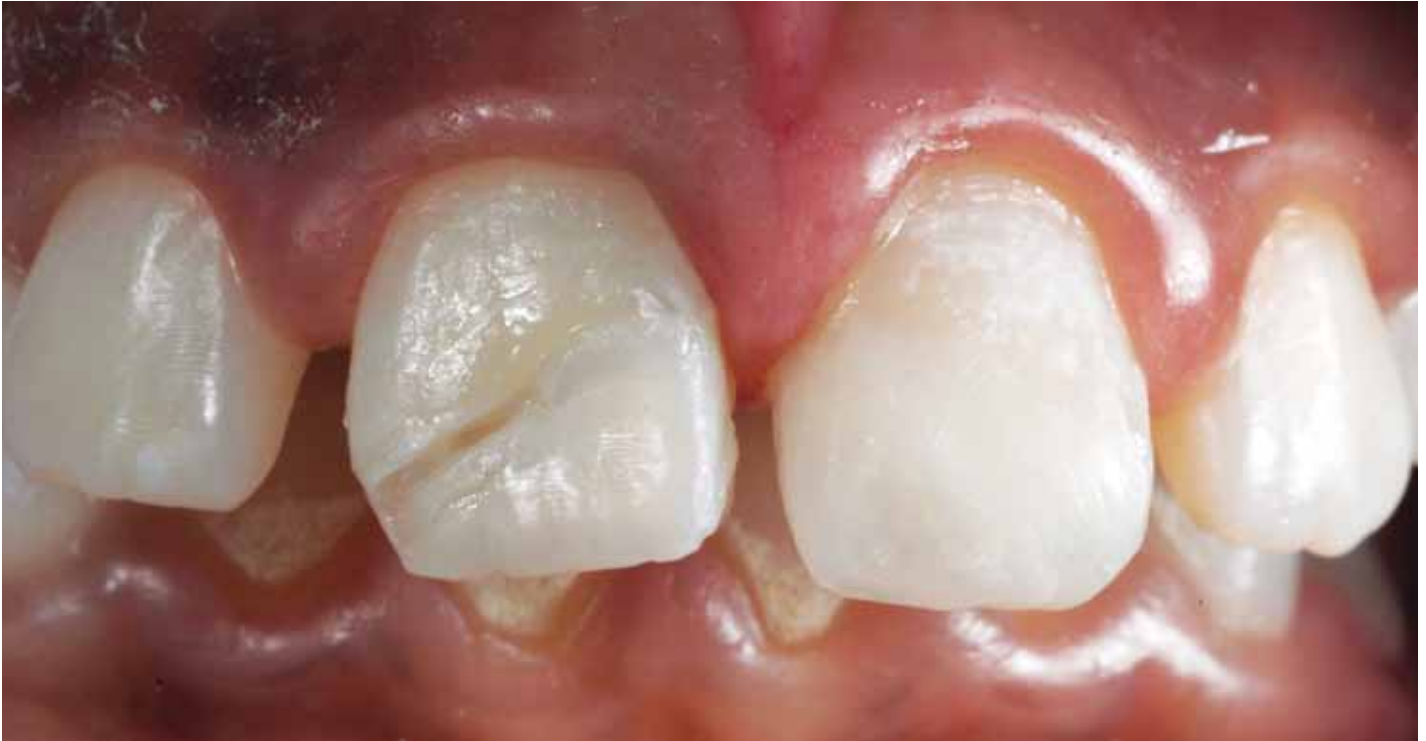**Figure 11:** Dentin composite was placed for the mamelon effect.




**Figure 12:** Sculpting of final covering layers.



**Figure 13:** Salvaged useable fragments of fractured teeth are ideal for reconstructing teeth to their former morphology.



**Figure 14:** The chasm between the remaining tooth and reattached fragment was filled with a combination of dentin and enamel shades to create an undetectable color transition.



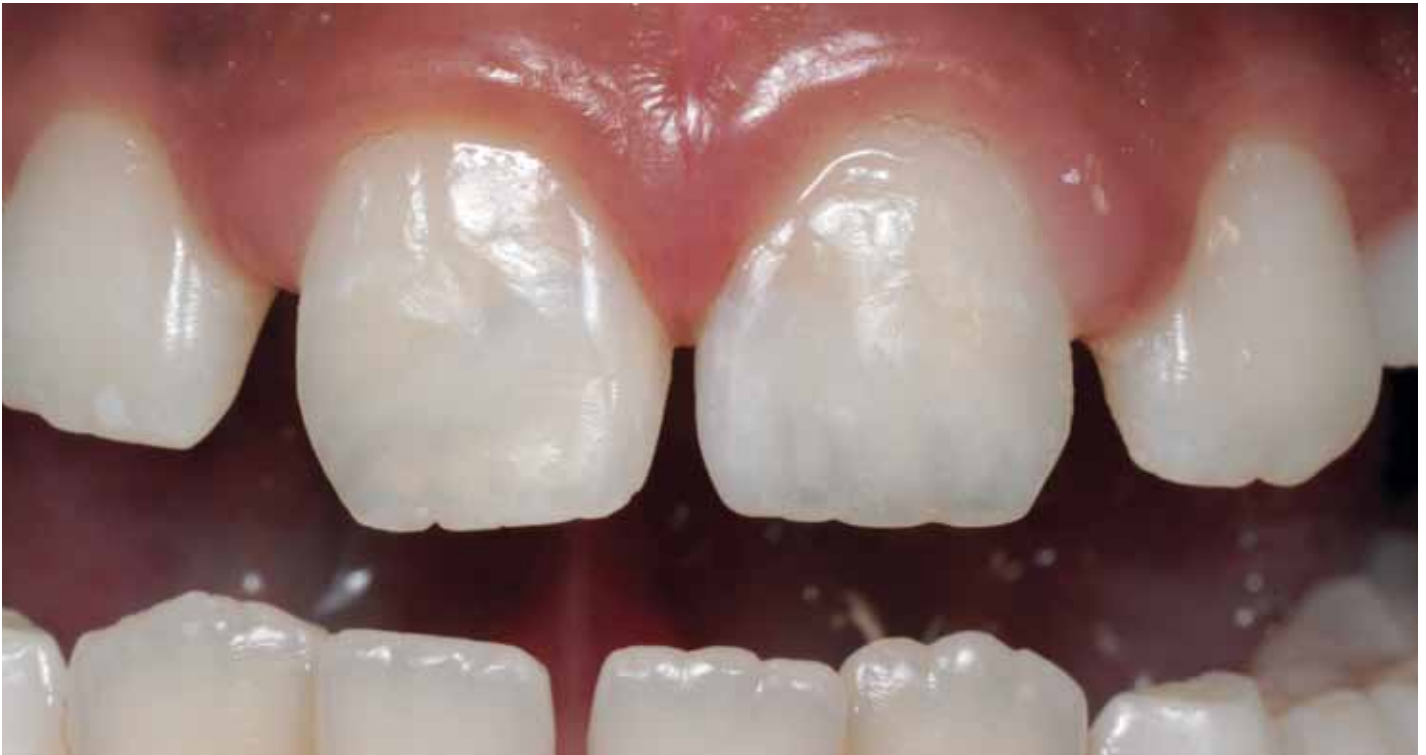**Figure 15:** Aluminum oxide abrasive discs.

The chasm between the remaining tooth and reattached fragment was filled with a combination of dentin A2 and enamel A2 shades to create an undetectable color transition (Fig 14).

Finishing and polishing should achieve a high gloss and smooth surface roughness (Ra)<sup>8</sup> of less than Ra = 0.2 mm (critical threshold for bacterial adhesion and biofilm formation)<sup>9</sup> for good marginal adaptation, reduced microleakage, and retaining morphology and occlusal contacts for improved wear resistance. Clinically, this is accomplished with aluminum oxide abrasive discs (Fig 15); diamond-coated interproximal strips, silicone tips, and polishing paste, using slow hand-piece speeds (< 10,000 min<sup>-1</sup>) to avoid melting the surface layer of the composite resin.

- 
- First, it is clinically difficult to produce a facsimile by direct free-hand composite buildups. ●
-



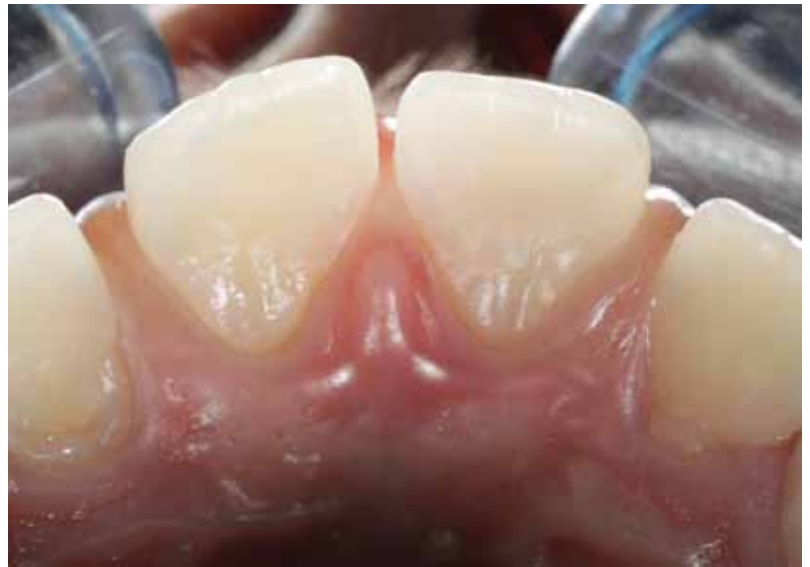

## Results

The postoperative result, two weeks later, shows impeccable gingival health, correct anatomical form of the composite buildup on the left central incisor, seamless transition between the composite and natural tooth substrate, dentin mamelons, together with an incisal halo, opalescence, and incisal edge translucency, which mimics the reattached natural tooth fragment on the right central incisor (Figs 16 & 17).

It is worth noting that the composite buildup on the left central incisor is similar, but not identical, to the morphology of the right central incisor. The reasoning for this is two-fold. First, it is clinically difficult to produce a facsimile by direct free-hand composite buildups. Second, it is unusual to find identical teeth in any one individual dentition, and slavishly copying an existing tooth appears contrived and artificial. Nature is creative, rather than perfect. Finally, any artificial prostheses or restoration should broadly conform to the existing dentition by blending with the surrounding teeth.

The pre- and postoperative full-face images (Figs 18 & 19) show restitution of dental esthetics that are in harmony with the surrounding lips, achieved by minimum intervention and yielding maximum satisfaction.



**Figures 16 & 17:** Two weeks postoperative.





Figures 18 & 19: Pre- and postoperative full-face images.

## References

1. Belcheva AB, Indzhova KN, Manolova MS, Stefanov RS, Mil-eva SP. Prevalence of crown fractures of permanent incisors in schoolchildren aged 7-11 years from Plovdiv. *Folia Med (Plovdiv)*. 2008 Apr-Jun;50(2):43-9.
2. Jafarzadeh H, Rosenberg PA. Pulse oximetry: review of a potential aid in endodontic diagnosis. *J Endod*. 2009 Mar;35(3):329-33.
3. Terry D, Leinfelder KF, Geller W. *Aesthetic & restorative dentistry: material selection & technique*. Stillwater (MN): Everest Publishing Media; 2009.
4. Yu B, Ahn JS, Lim JI, Lee YK. Influence of TiO<sub>2</sub> nanoparticles on the optical properties of resin composites. *Dent Mater*. 2009 Sep;25(9):1142-7. Epub 2009 May 1.
5. Rodrigues SA Jr, Ferracane JL, Della Bona A. Flexural strength and Weibull analysis of a microhybrid and a nanofill composite evaluated by 3- and 4-point bending tests. *Dent Mater*. 2008;24(3):426-31.
6. Raskin A, Setcos JC, Vreven J, Wilson NHF. Influence of the isolation method on the 10-year clinical behaviour of posterior composite restorations. *Clin Oral Invest*. 2000;4:148-52.
7. Capp CI, Roda MI, Tamaki R, Castanho GM, Camargo MA, de Cara AA. Reattachment of rehydrated dental fragment using two techniques. *Dent Traumatol*. 2009;25(1):95-9.
8. Paravina RD, Roeder L, Lu H, Vogel K, Powers JM. Effect of finishing and polishing procedures on surface roughness, gloss and color of resin-based composites. *Am J Dent*. 2004 Aug;17(4):262-6.
9. Ono M, Nikaido T, Ikeda M, Imai S, Hanada N, Tagami J, Matin K. Surface properties of resin composite materials relative to bio-film formation. *Dent Mater J*. 2007 Sep;26(5):613-22. **JCD**



Dr. Ahmad's practice, The Ridgeway Dental Surgery, is located in Harrow, Middlesex, UK. He may be contacted at [iahmadbds@aol.com](mailto:iahmadbds@aol.com).

Disclosure: The author presents sponsored lectures for various manufacturers, but he did not receive any financial remuneration for this article.



• COMPLETELY INTEGRATED • COLOR CODED • WEAR RESISTANT • TOP RATED

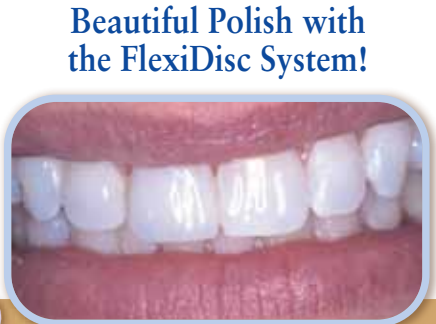
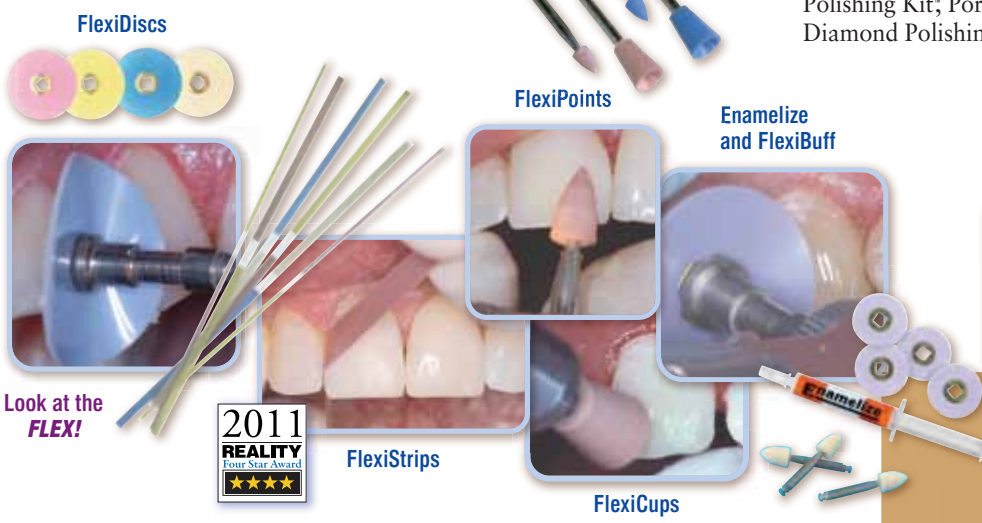
# Top Finishers™

Every  
Patient.  
Any  
Restoration.



- **FlexiDiscs® (regular and mini center)**  
Better, Easier and Cheaper! Thin, highly flexible and resilient discs recommended as top choice for over 20 years.  
"Rates even with leading disc but half the price."
- **FlexiStrips™**  
contour and polish all interproximal surfaces exceptionally.  
"Ultrathin modification makes these strips easy-to-use."
- **FlexiCups™ and FlexiPoints™**  
Wear Resistant! These rubber cups and points polish gingival margins and hard to reach areas and impart labial characterization.  
"#1 rated rubber polishing instruments."
- **Enamelize™ and FlexiBuff™**  
The Final Polish! Doctors are amazed at the highly polished surface after using Enamelize, FlexiBuff and Felt FlexiPoint.  
"Great choice and a terrific value."
- **And More!**  
FlexiDiamond Strips®, NANO/Microhybrid Diamond Polishing Kit; Porcelain Diamond Polishing Kit; Porcelize™ Diamond Polishing Paste, and mandrels.



Beautiful Polish with the FlexiDisc System!

Look at the FLEX!



TRY OUR 30 DAY RISK-FREE GUARANTEE.

to order Top Finishers  
**800-621-6729**  
WWW.COSMEDENT.COM

**COSMEDENT®**  
*Spreading Smiles*

© 2012 Dentistry and photography by: Bud Mopper, D.D.S., M.S., and Robert Margeas, D.D.S., F.A.G.D.





# Keeping It **REAL!**

**Beauty is appreciated by stimulating the higher senses of sight and sound, and has mystified both scientists and artists since the ancient Egyptians some 5000 years ago.**



# Mystifying Beauty

Irfan Ahmad, BDS

## Introduction

The definition of *esthetics*, or *beauty*, is perplexing. For a thing to be perceived as beautiful (or esthetic) it should arouse feelings of sensual pleasure, or goodness, or truth, for emotional release through esthetic expression. Although the quintessential ingredients of beauty are definable as order, unity, harmony, and balance, the “recipe” for achieving these qualities remains elusive. Beauty is appreciated by stimulating the higher senses of sight and sound, and has mystified both scientists and artists since the ancient Egyptians some 5000 years ago.

## Three Schools of Thought

### Geometric Theories

Dental esthetics is primarily concerned with “smile design,” usually of the maxillary anterior sextant. There are three schools of thought relating to dental esthetics: geometric, psychological, and perception theories. The first geometric theory, proposed by Lombardi in 1973,<sup>1</sup> stated that the repeated width proportion from the maxillary central incisor to the canine, as viewed from the frontal aspect, conformed to the “golden proportion” (GP) conceived by Pythagoras in 530 BC. Since the 1970s, the GP has been ubiquitously discussed in the dental literature and indelibly engrained in cosmetic dentists’ psyches. Nowhere is Vladimir Lenin’s adage “A lie told often enough becomes truth” more appropriate than with smile designs’ preoccupation with the GP. Since Lombardi, numerous authors have proposed other smile design guidelines<sup>2-7</sup> that aim for perfection by mathematical computations. However, it should be noted that “perfection” does not equal “esthetics.” A thing that appears “too perfect” is inherently perceived as artificial; for example, no two roses are identical, and no two individuals are “clones” (except identical twins). In the last decade most of the geometric theories have been repeatedly disproved, especially that of the GP, which is prevalent in only 10% of the population.<sup>8-11</sup>

### Psychological Theories

The second school of thought dealing with dental esthetics comprises the psychological theories such as dynesthetic,<sup>12</sup> morphopsychological,<sup>13</sup> and synesthetic.<sup>14</sup> These concepts aim to interpret dental esthetics from a psychological perspective, and are mainly opinions and hypotheses, often open to interpretation.

### Perception Theories

The third, and most recent, are the perception theories, which encompass population surveys and responses to various esthetic anomalies (by software image manipulation) for gauging responses from dental professionals and laypersons.<sup>15-17</sup> These are the most promising theories because they ask “what the patient wants,” rather than imposing “what the patient needs.” However, the sampled population is often limited to specific countries and particular groups; therefore, these theories are not universally applicable for every country or even regions in a specific country.

## No “One Size Fits All”

There are no “magic numbers,” no “Da Vinci code,” and no “Holy Grail” for deciphering dental esthetics. Geometric theories are a *framework* rather than a *formula*, psychological theories should be considered *pragmatic* rather than *dogmatic*, and perception theories as *subjective* as opposed to *objective*. Dental esthetics is a combination of all three theories for creating beauty that is specific for an individual, rather than a “one size fits all,” wall-to-wall porcelain or “piano keys” appearance of the maxillary anterior teeth. Therefore, the key to successful dental esthetics (or smile design) is incorporating minor imperfections that enhance the dental composition, giving a real or natural appearance, which is as unique as an individual’s persona.

The schematic representation in **Figure 1** shows smile design guidelines incorporating all three theories discussed above. Starting with a template, which can be an existing template (or dental composition) where no changes are necessary (e.g., a single crown, veneers or implant-supported restoration that is integrated within the existing dentition). The second type of template is where the prevailing dental esthetics require change (e.g., worn teeth with loss of vertical dimension due to tooth wear). The last type is when a new template is necessary (e.g., an edentulous arch or few teeth that are insufficient as a guide for rehabilitation). For both changed and new templates, any of the geometric theories are used as a starting point for either a diagnostic wax-up or computer simulation. Which geometric theory one chooses is irrelevant, since the difference between many of the theories can be as little as 0.5 mm, which is barely perceptible at a social distance of viewing.

**Figure 2** shows central incisors requiring esthetic improvement. However, due to the unacceptable morphology of the central incisors, a change in template was necessary. A diagnostic wax-up was made using one of the geometric theories, and a plaster cast of the latter (**Fig 3**) allowed a vacuum stent to be fabricated for making two acrylic temporary crowns (**Fig 4**). The patient was allowed to wear the temporary crowns for her input (psychological theories) and gauge response from family and friends (perception theories). Based on this input, the temporaries were periodically adjusted until the patient was satisfied. At this stage it is important to communicate to the patient any shortcomings in the final esthetics due to the prevailing clinical scenario. If the patient’s esthetic expectations are beyond clinical feasibility, this is the time to convey any compromises that are unavoidable, rather than facing the consequences when the definitive restorations are fabricated. Only after receiving acceptance from the patient should the clinician proceed with the permanent restorations. The final all-ceramic crowns (**Fig 5**) are similar, but not identical, to the wax-up and temporary crowns (**Figs 3 & 4**). The chip at the incisal edge of the natural left lateral is mimicked in the crowns on the central incisors, which enhances the natural appearance of the crowns and avoids a contrived, artificial appearance.

The schematic sequence shown in **Figure 1** was adopted for the smile design, incorporating geometric, psychological, and perception theories (**Fig 6 [see also Fig 14]**).



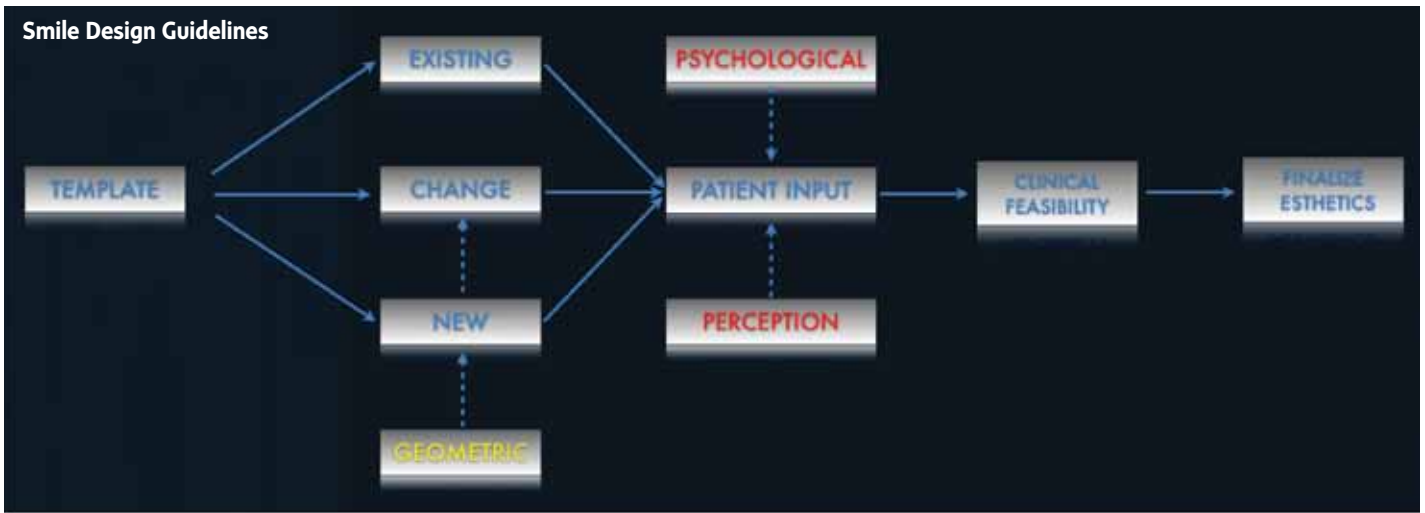


Figure 1: Schematic representation showing smile design guidelines incorporating the geometric, psychological, and perception theories.

### Case Presentation

A 30-year-old woman visited the author’s practice wishing to improve the appearance of her anterior teeth. Examination revealed an average maxillary lip line (75% to 100% of maxillary tooth exposure), uneven maxillary incisal plane, discolored teeth, stained large defective composite restorations, erratic maxillary gingival architecture, relatively healthy periodontium, missing filling in the mandibular right first central incisor, and a reversed overbite of the left mandibular lateral incisor and canine.

After discussing these esthetic anomalies with the patient, she declined orthodontic and periodontal plastic surgery, which would have corrected the reversed overbite and erratic maxillary gingival architecture. This emphasizes that patients are often less discriminating regarding minor esthetic anomalies compared to clinicians. Therefore, proposing therapy that is invasive and costly may be regarded as overtreatment, and marketing or selling cosmetic procedures is merely sensitizing patients to minor esthetic aberrations, which they would normally find acceptable or ignore. At times, naïveté or ignorance can be a blessing.

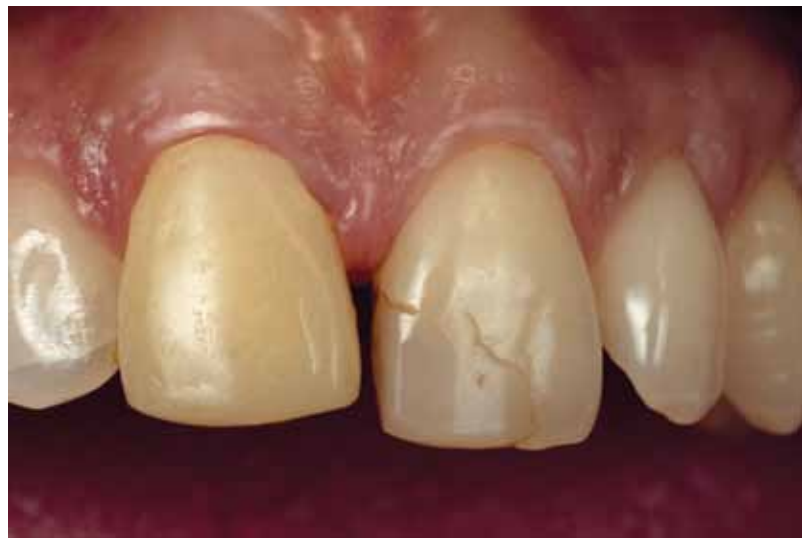
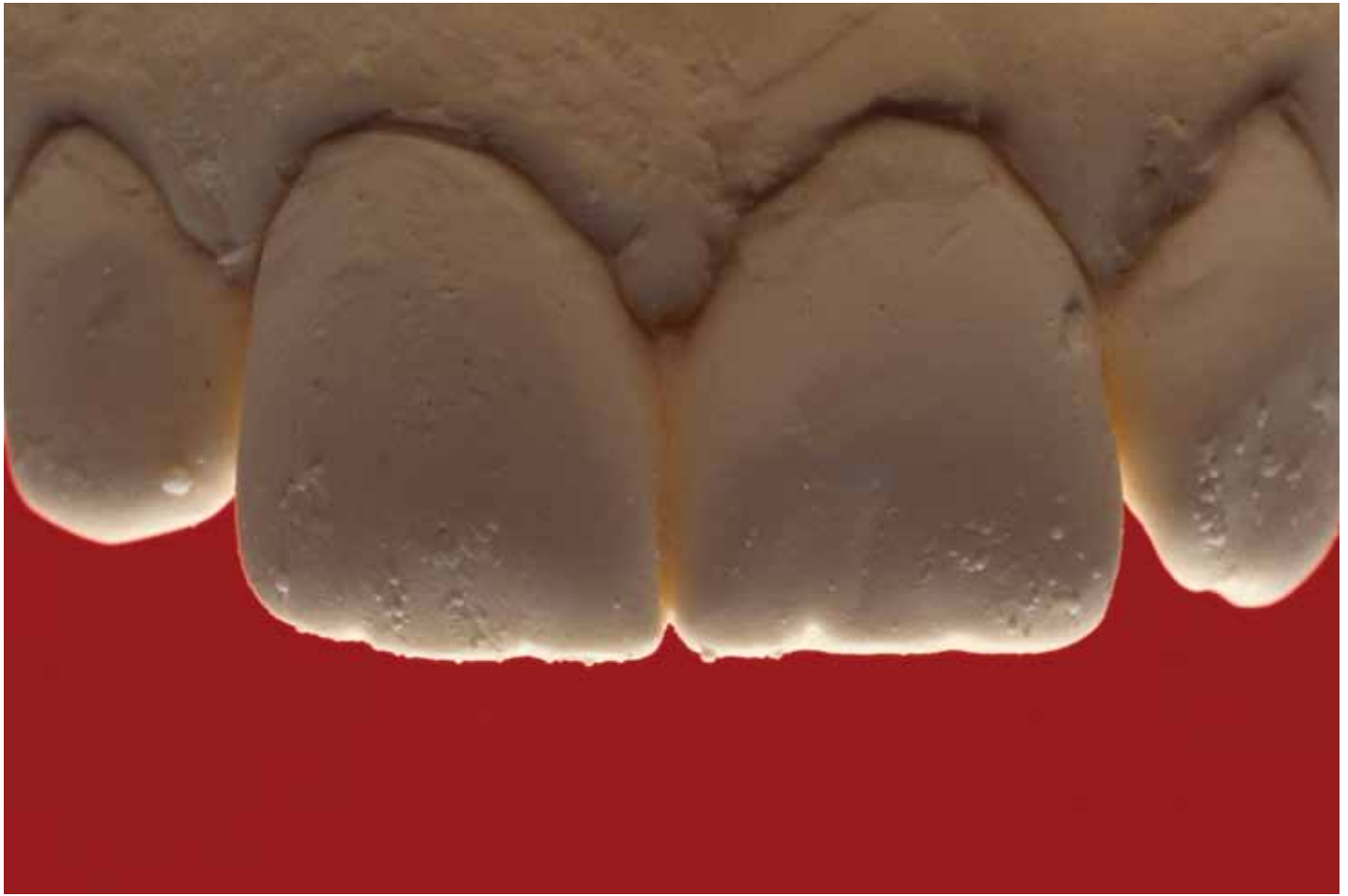
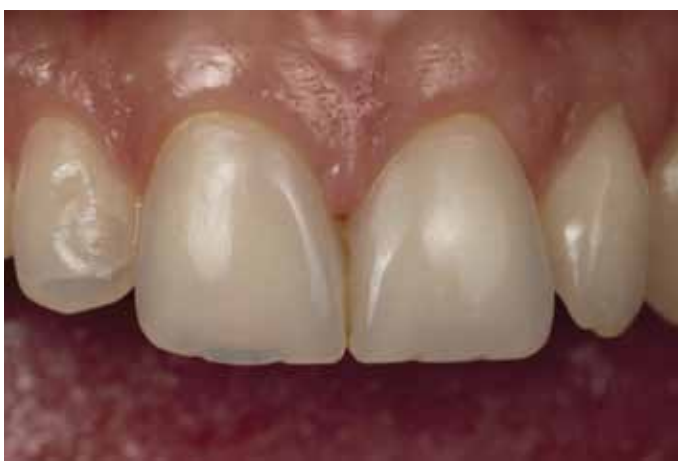Figure 2: Central incisors in need of esthetic improvement.

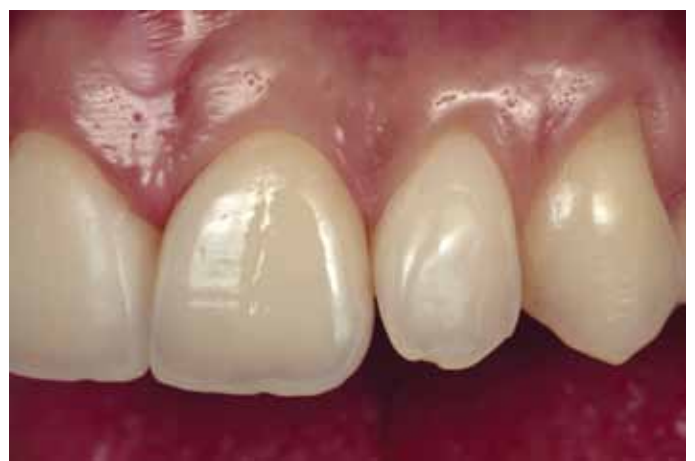A thing that appears “too perfect” is inherently perceived as artificial.



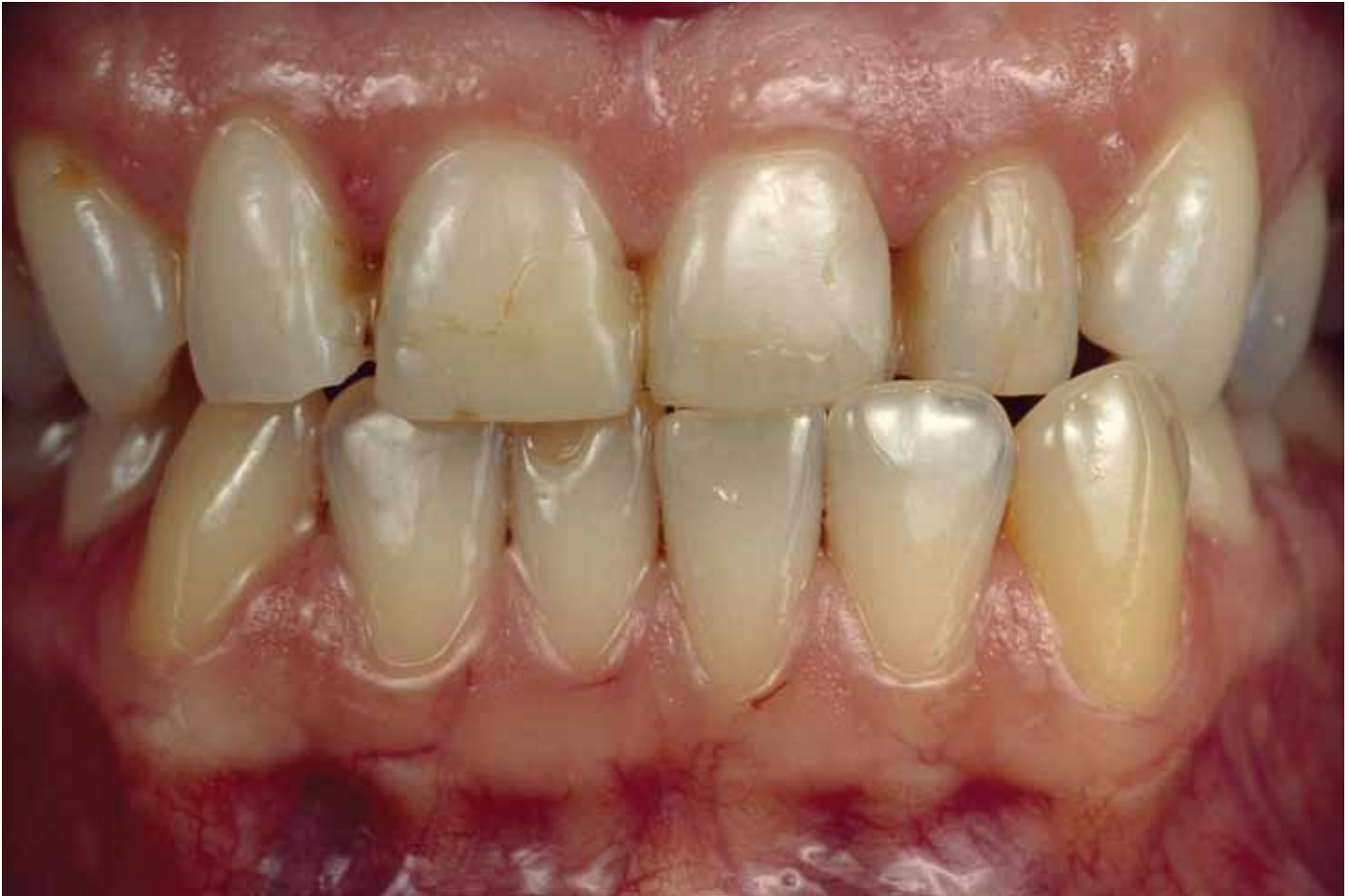**Figure 3:** Plaster cast.



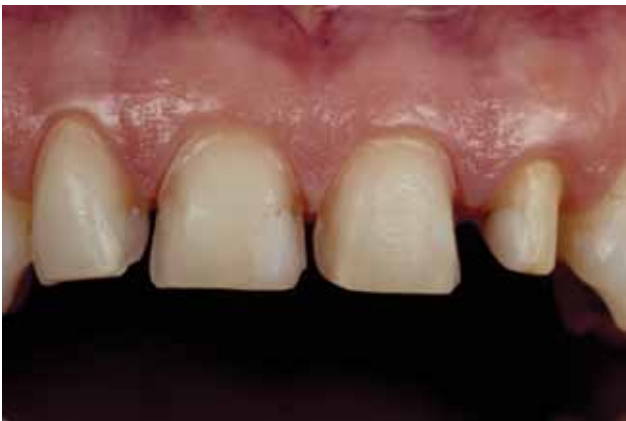**Figure 4:** Two acrylic temporary crowns.



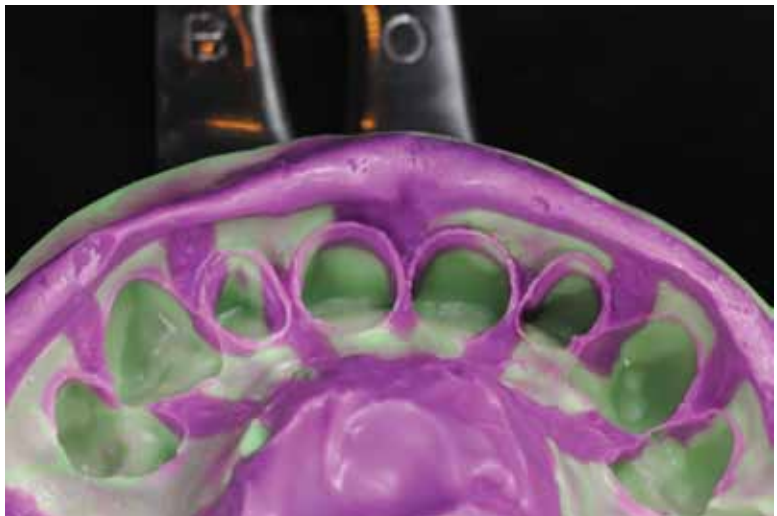
**Figure 5:** Final all-ceramic crowns.



**Figure 6:** The schematic sequence shown in Figure 1 was adopted for the smile design, incorporating the geometric, psychological, and perception theories.

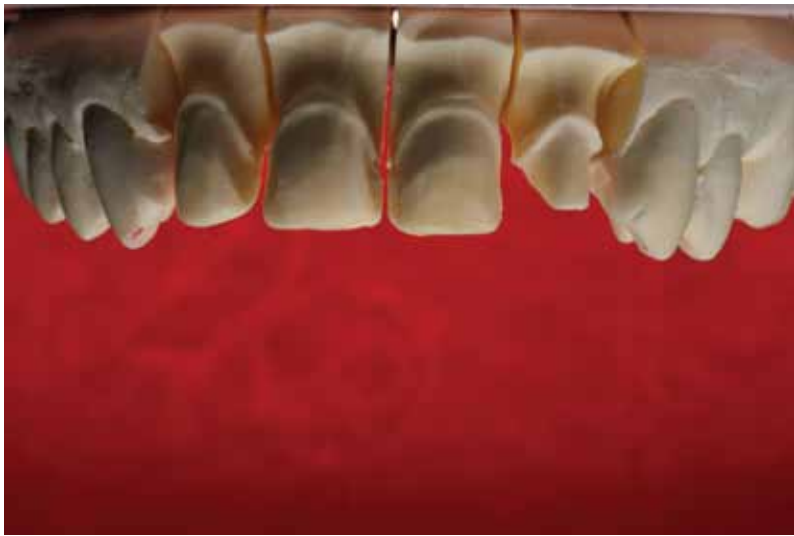

**Figure 7:** Preparation for PLVs on the right lateral and central incisors and a full-coverage crown on the left lateral incisor. Gingival health is apparent around all the prepared teeth, ready for impressions.

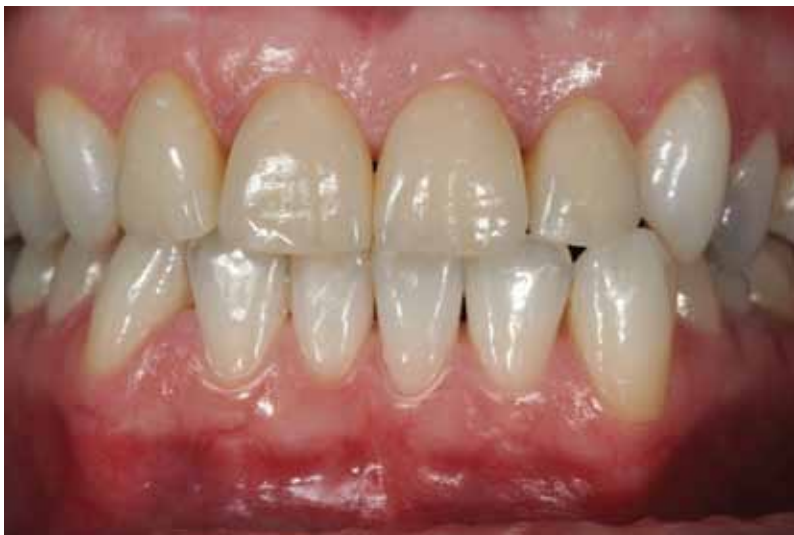

**Figure 8:** Impression with a PVS impression material capturing precise detail, particularly at the cervical margins.





**Figure 9:** Plaster cast of the prepared teeth. An area beyond the preparation finish line is faithfully reproduced to create the correct emergence profiles of the definitive ceramic restorations.



**Figure 10:** Obvious color mismatch of the restorations with the surrounding natural dentition at try in.

The key to successful dental esthetics (or smile design) is incorporating minor imperfections that enhance the dental composition...

### Treatment

A diagnostic wax-up of the maxillary incisors was done using one of the geometric theories, and intra-oral temporaries were fabricated to gauge patient input (psychological theories) and response from family and friends (perception theories). The definitive restorations were fabricated only after the patient was completely satisfied with the temporaries.

**Figure 7** shows preparation for porcelain laminate veneers (PLVs) on the right lateral and central incisors and a full-coverage crown on the left lateral incisor.

**Figure 8** depicts the impression with a polyvinyl siloxane (PVS) impression material capturing precise detail, particularly at the cervical margins.

A plaster cast of the prepared teeth, showing that an area beyond the preparation finish line was faithfully reproduced for creating the correct emergence profiles of the definitive ceramic restorations, is shown in **Figure 9**.

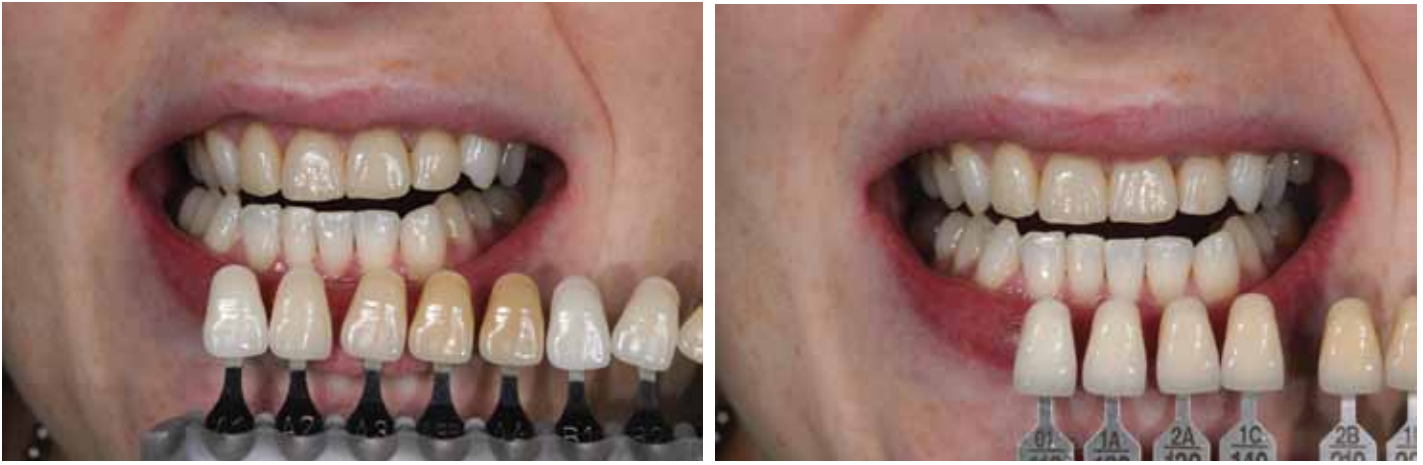Despite meticulous care and attention to detail, things can go wrong. At the try-in stage, the color mismatch of the restorations with the surrounding natural dentition (which had previously been bleached) was blatantly obvious (**Fig 10**). This was due to a lack of communication between the clinician and ceramist; in these circumstances, using opaque or bleach shades of a luting agent is futile. The only solution is a remake, which is frustrating for the patient, and costly and embarrassing for the clinician.

The filling in the mandibular right central incisor was replaced with a composite filling, and the mandibular left lateral incisor and the canine were adjusted to accommodate the occlusion.

Photographs were taken with two different shade guides as a reference for remaking all four restorations (**Figs 11 & 12**).

A four months' postoperative image shows the remade correct color restorations, which blend with the existing dentition, with an impeccably healthy periodontium (**Fig 13**).

Preoperative and six months' postoperative facial views (**Figs 14 & 15**) show improved, natural-looking anterior esthetics.



Figures 11 & 12: Reference photographs were taken with two different shade guides for remaking all four restorations.

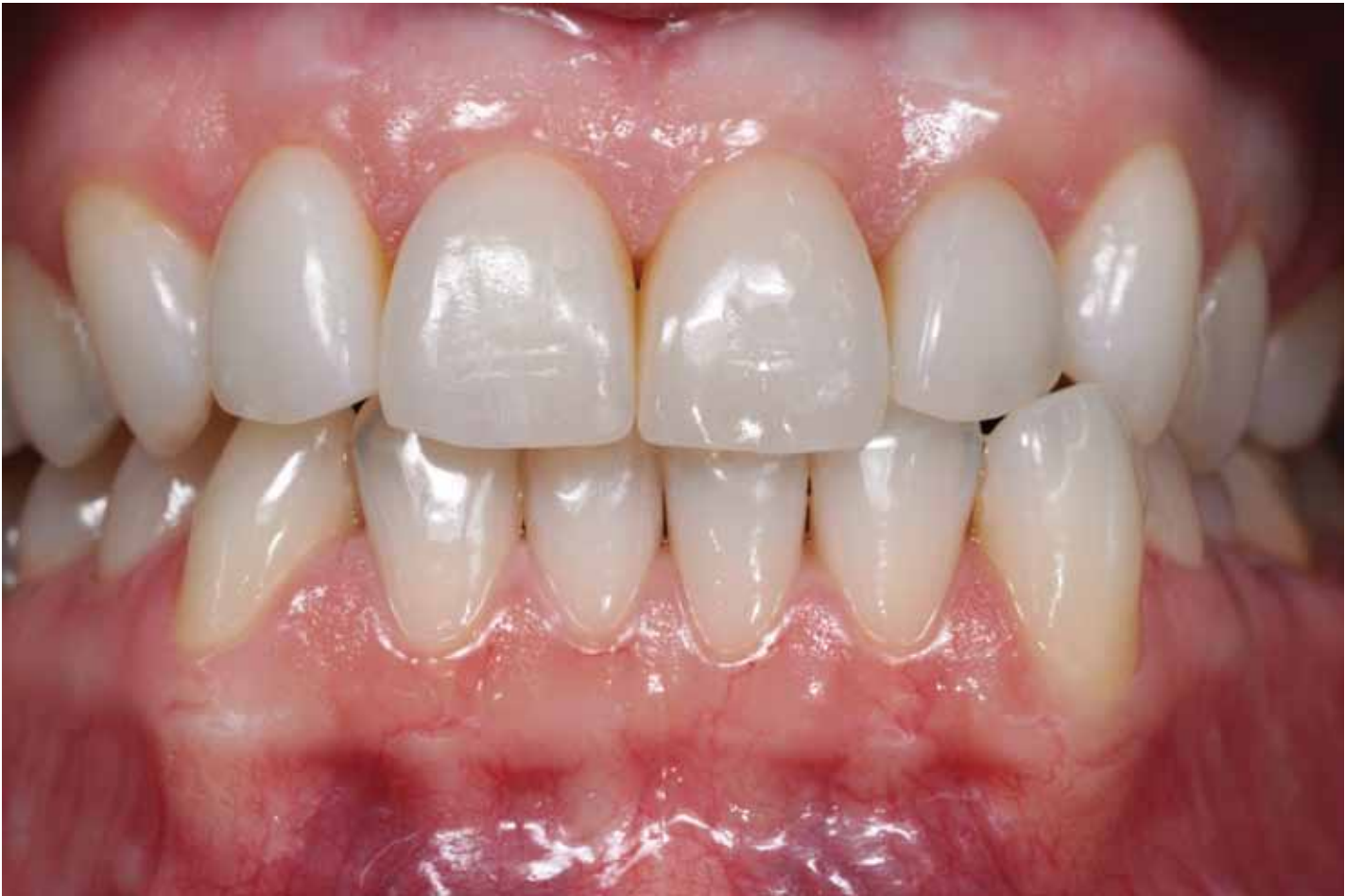
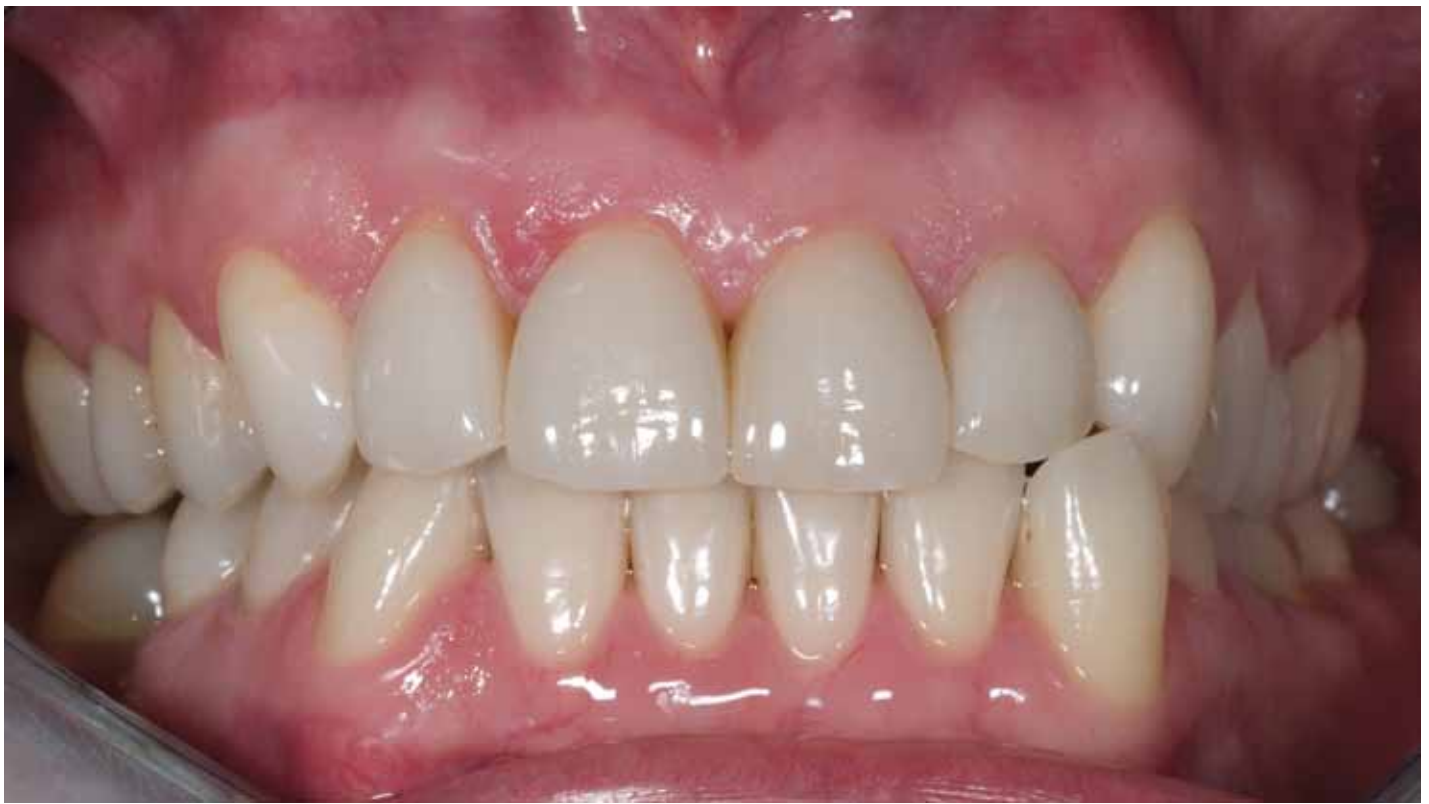
Figure 13: Four months' postoperative image showing the remade correct color restorations, which blend with the existing dentition, with an impeccably healthy periodontium. The crown on the left lateral has been shortened on its distal incisal aspect to accommodate the reversed overbite; combined with the erratic maxillary gingival architecture, this gives the appearance of a natural and real dentition, as opposed to a perfectly symmetrical (or artificial) smile.



**Figures 14 & 15:** Pre- and postoperative facial views. The improved anterior esthetics appear natural and real.



**Figure 16:** Four years postoperative, there is gingival recession around the mid-facial aspects of the right lateral and central incisors, and on the distal aspect of the left central incisor. However, the restorative margins are intact without chipping of the ceramic. Also, the porcelain and bleached natural teeth are color-stable.





**Figure 17:** Facial view four years after treatment. The distal incisal adjustment of the crown on the left lateral is visible, creating imperfection and enhancing the smile's natural esthetics.

### Results

Four years after treatment, there is gingival recession around the mid-facial aspects of the right lateral and central incisors, and on the distal aspect of the left central incisor (Fig 16). However, the restorative margins are intact without chipping of the ceramic. Also, there is color stability of the porcelain and bleached natural teeth. As long as the gingival health remains good, no further treatment other than periodic monitoring is warranted.

A full-face image of the patient four years after treatment is shown in Figure 17. The distal incisal adjustment of the crown on the left lateral is visible, creating imperfection and enhancing natural esthetics of the smile.

### Summary

Science is objective, with little leeway; whereas art is subjective, open to interpretation. Since esthetics is an art, not a science, the scientific community is likely wasting time trying to quantify rules and principles to decipher this entity. Hence, attempts to apply scientific rules and guidelines have failed to determine rigid principles for esthetics over the last 5000 years. Esthetic objectivity remains an elusive goal, and perhaps one that may never be reached.

## References

1. Lombardi RE. The principles of visual perception and their clinical application to denture esthetics. *J Prosthet Dent.* 1973;29:358-82.
2. Snow SR. Esthetic smile analysis of maxillary anterior tooth width: the golden percentage. *J Esthet Dent.* 1999;11:177-84.
3. Ward DH. Proportional smile design using the RED proportion. *Dent Clin North Am.* 2001;45:143-54.
4. Preston JD. The golden proportion revisited. *J Esthet Dent.* 1993;5:247-51.
5. Gillen RJ, Stewart RS, Hilton TJ, Evans DB. An analysis of selected normative tooth proportions. *Int J Prosthodont.* 1994;7:410-17.
6. Rosenstiel SF, Ward DH, Rashid RG. Dentists' preferences of anterior tooth proportion—a web-based study. *J Prosthodont.* 2000;9:123-36.
7. Radlinsky SV. Aesthetic deviation. *Br Dent J.* 2009;206(9):447.
8. Hasanreisoglu U, Berksun S, Aras K, Arslan I. An analysis of maxillary anterior teeth: facial and dental proportions. *J Prosthet Dent.* 2005;94:530-8.
9. Mashid M, Khoshvaghti A, Varshosaz M, Vallaei N. Evaluation of "golden proportion" in individuals with an esthetic smile. *J Esthet Rest Dent.* 2004;16:185-92.
10. De Castro MV, Santos NC, Ricardo LH. Assessment of the "golden proportion" in agreeable smiles. *Quintessence Int.* 2006;37:597-604.
11. Fayyad MA, Jaman KD, Aqrabawi J. Geometric and mathematical proportions and their relations to maxillary anterior teeth. *J Contemp Dent Pract.* 2006;(7)5:62-72.
12. Frush JP, Fisher RD. The dynesthetic interpretation of the dentogenic concept. *J Prosthet Dent.* 1958;8:558-81.
13. Rufenacht CR. *Fundamentals of esthetics.* 2nd ed. Hanover Park (IL): Quintessence Pub.; 1990.
14. Ahmad I. *A clinical guide to anterior dental aesthetics.* London: BDJ Books; 2005.
15. Kokich VO Jr., Kayak HA, Shaper PA. Comparing the perception of dentists and lay people to altered dental esthetics. *J Esthet Dent.* 1999;11(6):311-24.
16. Pinho S, Circa C, Faber J, Lenza MA. Impact of dental asymmetries on the perception of smile esthetics. *Am J Orthod Dentofacial Orthop.* 2007;132:748-53.
17. Ker AJ, Chan R, Fields HW, Beck M, Rosenstiel S. Esthetics and smile characteristics from the layperson's perspective. *J Am Dent Assoc.* 2008;139(10):1318-27. **jcd**



Dr. Ahmad's practice, The Ridgeway Dental Surgery, is located in Harrow, Middlesex, UK. He may be contacted at [iahmadbds@aol.com](mailto:iahmadbds@aol.com).

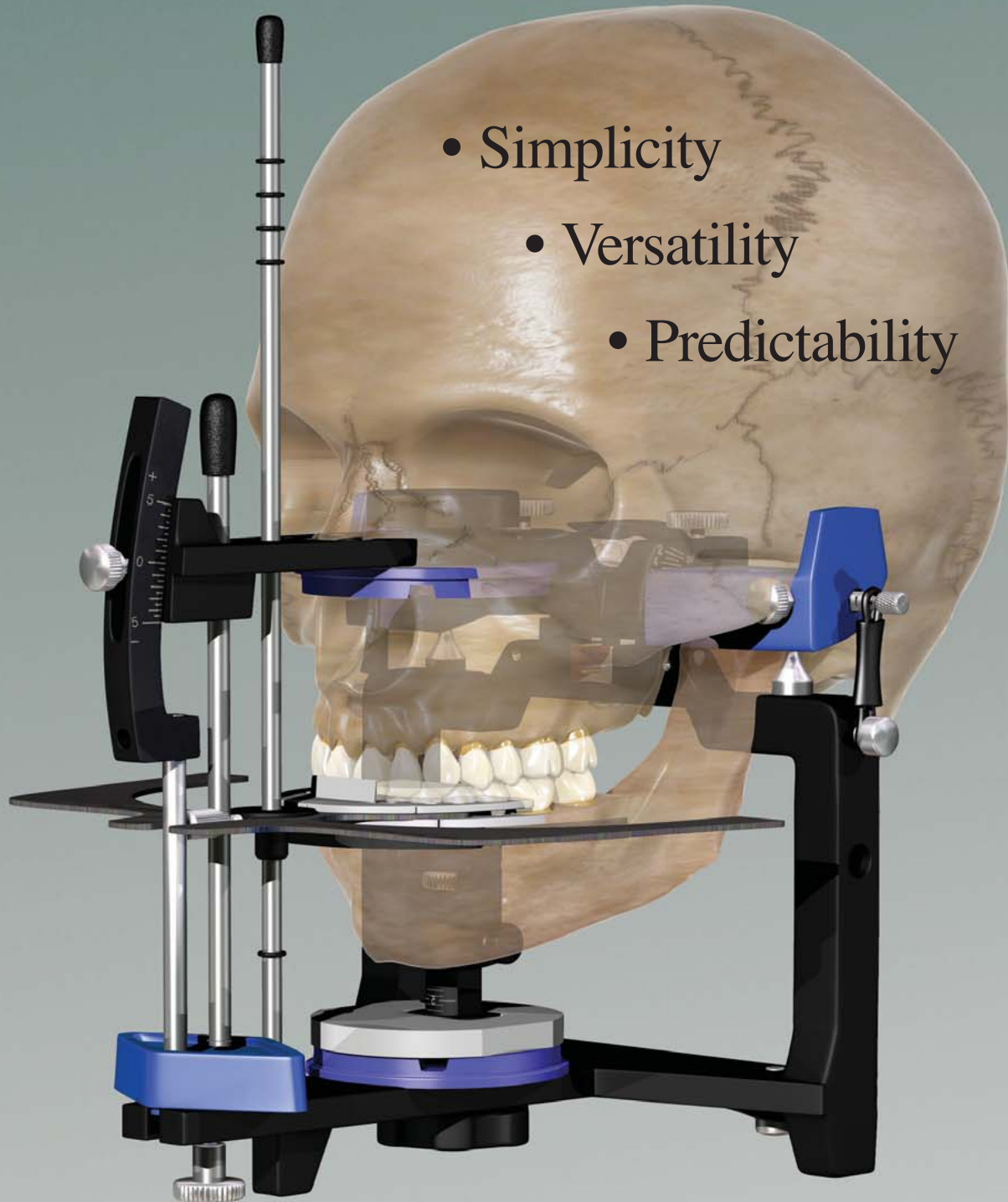
Disclosure: The author presents sponsored lectures for various manufacturers, but he did not receive any financial remuneration for this article.



# Articulator System

## KOIS DENTO-FACIAL ANALYZER

*Combining Esthetics & Function*



- Simplicity
- Versatility
- Predictability

Visit us at the A.A.C.D. Annual Meeting Booth # 610

[www.panadent.com](http://www.panadent.com) / 1-800-368-9777



# *Myths* vs. **REALITIES**

## Feldspathic Stacked Porcelain Veneers *and* Pressed Porcelain Veneers

Dario Adolfi, DDS, CDT

Mauro Fradeani, DDS

As responsible clinicians and ceramists, we are constantly searching for the best treatment options to deliver high-quality restorations to our patients. We all strive to create a delicate balance between hard and soft tissue for a synergistic outcome. New materials make it increasingly possible for us to present less invasive alternatives. In a quest for answers, the *jCD* asked distinguished educators Dr. Dario Adolfi and Dr. Mauro Fradeani to share their thoughts regarding the myths and realities of feldspathic stacked porcelain veneers and pressed porcelain veneers. Their comments will enlighten you, either providing another way of looking at this topic, or confirming what you already believe.



One of the advantages of this material is the potential to obtain high-quality restorations that achieve a perfect harmony between soft and hard tissues.



### Dr. Adolfi Dispels Myths Regarding Feldspathic Stacked Veneers

The use of laminate veneers is among the most documented approaches in the dental literature for improving smiles. One of the advantages of this material is the potential to obtain high-quality restorations that achieve a perfect harmony between soft and hard tissues. This is due to the physical properties of the ceramic, which remains stable over time—even inside an environment as adverse as the oral cavity. To achieve success and stability, bonding procedures must be planned and conducted carefully, leading to a perfect sealed interface between the tooth and ceramic.

To achieve a bonding interaction between dental hard tissue and ceramic, the structures must be capable of being altered to receive a material that combines the surfaces, thus creating a perfect interface.<sup>1</sup> The adhesive ability of the restorative material to be bonded to tooth structure is referred to as “biomimetic.”<sup>2</sup>



## Myth

Stacked feldspathic veneers lead to periodontal issues because they are usually over-contoured.

## Reality

Bulky veneers should always be avoided, because they may appear unnatural.<sup>3</sup> Therefore, prominent cervical contours must be carefully flattened to avoid over-contouring the final restoration.<sup>4</sup>

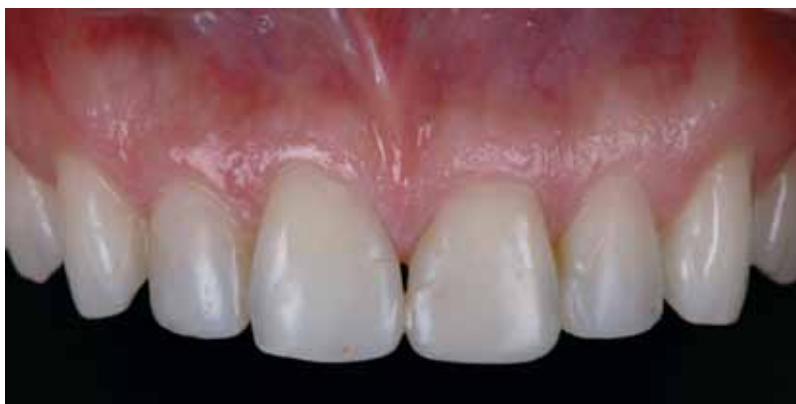Also, when the veneers are placed without preparation, periodontal problems can occur as a result of over-contoured teeth with unnatural emergence profiles.<sup>5</sup> For no-preparation veneers, the esthetic results are variable; some of these restorations can appear too bulky and over-contoured,<sup>6</sup> while others have relatively acceptable esthetics.<sup>4,6</sup>

A wax-up is indispensable for every esthetic dental plan. For cases where a minimal preparation is planned, the procedure must be done with the additive technique. Prior to planning a wax addition, the dentist must carefully consider the initial evaluation of the case, which addresses the teeth's characteristics, the patient's smile, patient's age, opposite arch, and gingival architecture.<sup>7</sup>

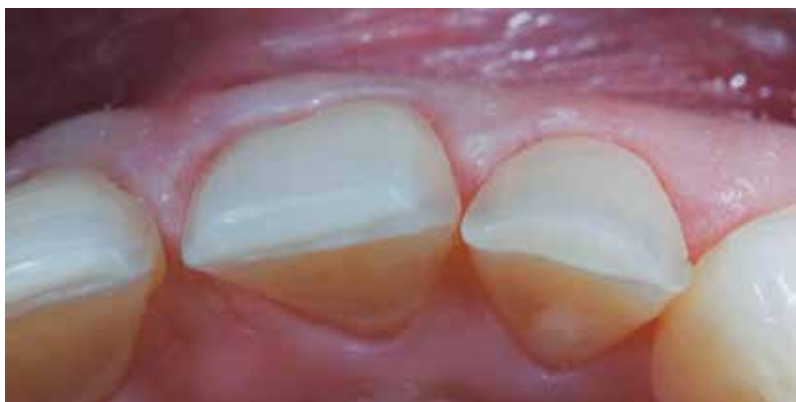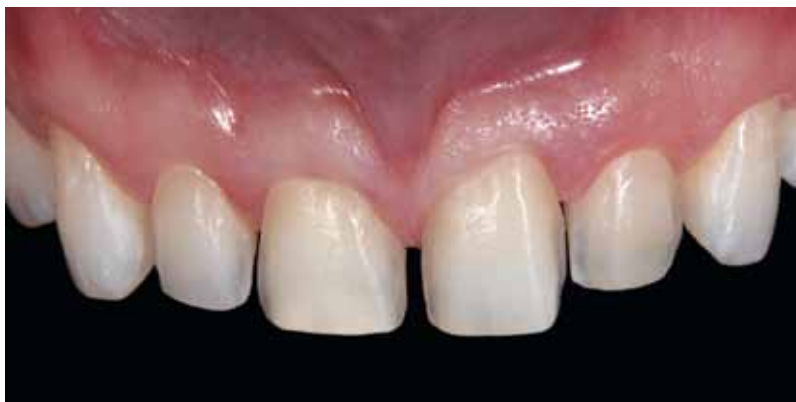To maintain a tooth's original shape, a clinician is often required to remove a slight to moderate amount of enamel when making preparations.<sup>8</sup> Some clinicians feel that a more optimal esthetic potential can be achieved when teeth are prepared with a light chamfer, especially at the gingival margin, which arguably prevents over-contouring in that region (Figs 1-2b).<sup>8</sup>

In the laboratory, it is very difficult to fabricate a veneer less than 0.3 mm thick.<sup>6</sup> Therefore, to preserve the health of the gingival tissues and prevent over-contouring, a slight 0.5-mm reduction of tooth surface has been found to work best.<sup>8</sup> Because feldspathic veneers are typically 0.5 mm, the lost tooth structure is replaced and the original emergence profile is nearly restored.<sup>9</sup> After cementation, the laminate veneers should mimic the patient's natural dentition (Fig 3).

However, in a study comparing teeth restored with porcelain veneers, both with and without preparation, it was reported that there were no differences in terms of periodontal health.<sup>10</sup>



**Figure 1:** Preoperative image of the anterior teeth showing extensive composite restorations.



**Figures 2a & 2b:** Facial and incisal views of minimal preparations with a light chamfer finish line; this practice guarantees correct tooth morphology and a natural emergence profile.

The #1 most comprehensive Botox/dermal filler training course in dentistry!  
Over 5000 dental professionals trained from 46 states and 25 countries!

# BOTOX® & DERMAL FILLER THERAPY

For Every Dental Practice



Join the AAFE today  
and save an extra  
\$200 on tuition

## Upcoming Courses:

16 AGD  
PACE CE  
Credits

*Featuring:*  
*Dr. Louis Malcmacher,*  
*Dr Peter Harnois,*  
*and the faculty of the*  
*American Academy*  
*of Facial Esthetics*

*Limited Attendance!*  
*Sign up before May 30*  
*- save up to \$700*

- April 27-28 – Seattle, WA
- April 27-28 – Detroit, MI
- May 2-3 – Newark, NJ
- May 4-5 – Houston, TX
- May 11-12 – Columbus, OH (Level I & II)
- May 18-19 – Orange County, CA
- May 18-19 – Ft. Lauderdale, FL
- June 8-9 – Atlanta, GA
- June 8-9 – Milwaukee, WI

*\*More 2012 dates can be found on our website*

Call Today!  
**1-800-952-0521**  
or visit: [www.FacialEsthetics.org](http://www.FacialEsthetics.org)

## OUR #1 SELLING BOTOX® AND DERMAL FILLER THERAPY DVD'S

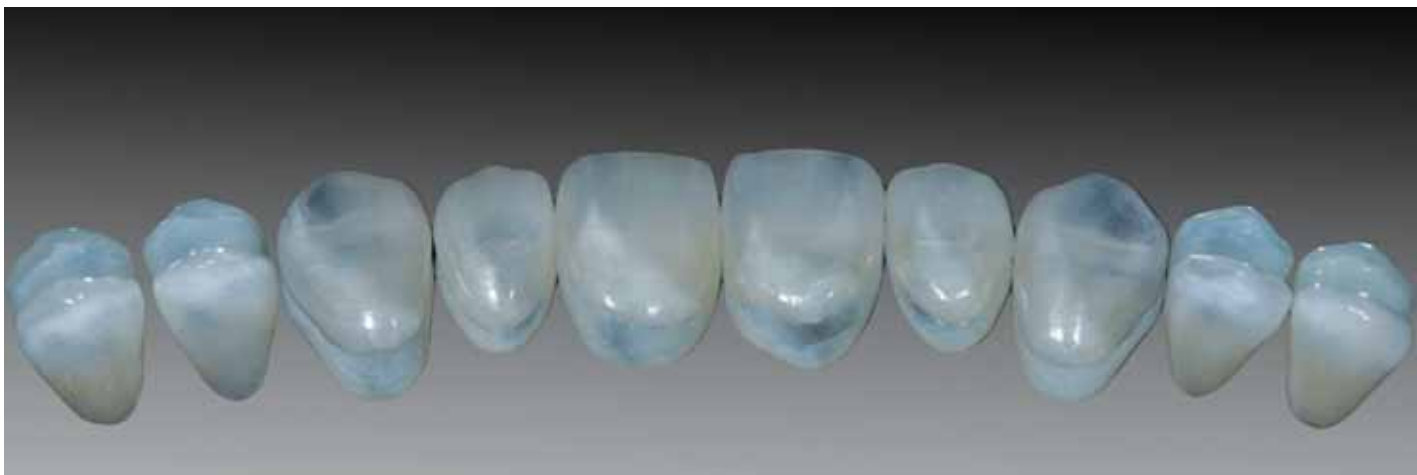### › BOTOX AND DERMAL FILLER THERAPY FOR TOTAL FACIAL ESTHETICS

These powerful and authoritative over the shoulder treatment DVD's will give you a solid foundation of minimally invasive total facial esthetic techniques.

Special to these DVD's! **Two hours of AGD PACE CE credit for each DVD!**  
Order now and save \$150 on the 3 volume DVD set!

Limited Time Offer - Order before May 30, 2012.





**Figure 4:** When placing the 10 lithium disilicate veneers in sequence and using special illumination, the thinness of the restorations is evident.

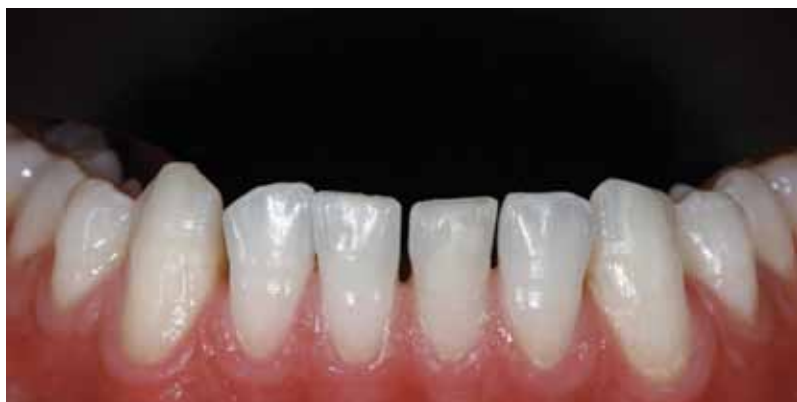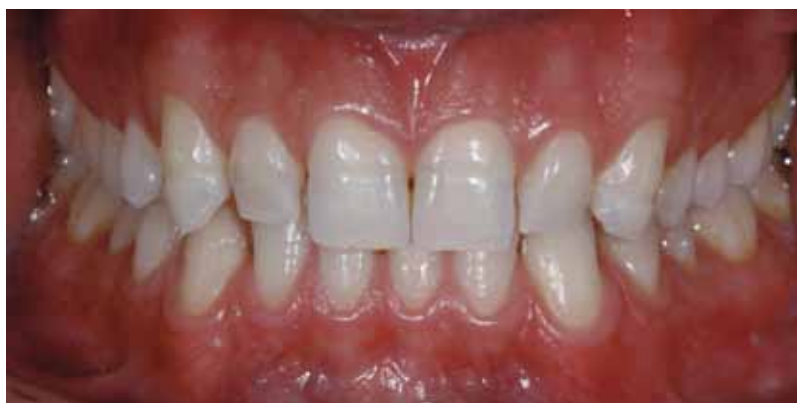### Myth

Feldspathic veneers are weak porcelain restorations that are more prone to failure due to chipping and fracture than pressed veneers.

### Reality

Many clinicians face difficulties during try-in and bonding procedures with feldspathic porcelain veneers. A major concern is their strength, which is only approximately 70 MPa to 90 MPa,<sup>11</sup> making feldspathic veneers more prone to failure before bonding than pressed veneers. The development and improvement of pressable lithium disilicate material with flexible strength of approximately 400 MPa has reintroduced the concept of less preparation for laminate veneers. Lithium disilicate permits the technician to build a pressed restoration as thin as 0.3 mm while still ensuring a strength of 400 MPa (Fig 4).

This ceramic can be carefully reduced, using rubber wheels and special burs, to less than 0.2 mm with proper resistance. Consequently, it can be placed and bonded with much less risk compared to traditional porcelain, which is made via the refractory die technique.<sup>1</sup> The final morphology of the restorations is injected with lithium disilicate, and all the characterization (fixation) is performed. The color and fitting can be evaluated and modified during the try-in procedures, with low risk of compromising the strength or fitting after many bakes. After fixation, two layers of glaze powder are applied to protect the characterization. Lithium disilicate is indicated for veneers with conventional preparation or no preparation to improve the esthetics and reestablish the anterior guidance (Figs 5a-6c). The disilicate-based materials maximize these benefits for laboratories and dentists.



**Figures 5a & 5b:** Enamel defects across the surfaces of the anterior maxillary and mandibular incisors. Note the diastemas between teeth and the discrete excess gingival tissue in the mandibular premolar areas.



## Myth

Feldspathic porcelains are too translucent to block out discolored teeth.

## Reality

Thin laminate veneers cannot easily mask severe staining and discoloration (such as severe tetracycline staining)<sup>12</sup> without adding thickness to the veneers. If thin veneers are constructed, the final result in these cases is often compromised due to the use of underlying opaque porcelain; the veneers typically exhibit a very high value and lack of vitality.<sup>4</sup>

Color discrepancy is due to the veneer's relative thinness and opaque quality; light passing through it can make the color of the underlying preparation show through.<sup>7</sup> If the patient requests a significant shade change, the dentist must overcome the color discrepancy by deepening the preparation and increasing the thickness of the restoration.<sup>4,13,14</sup> This enables the technician to block out the underlying tooth color and achieve the desired color change (Figs 7 & 8).<sup>12</sup>

## Myth

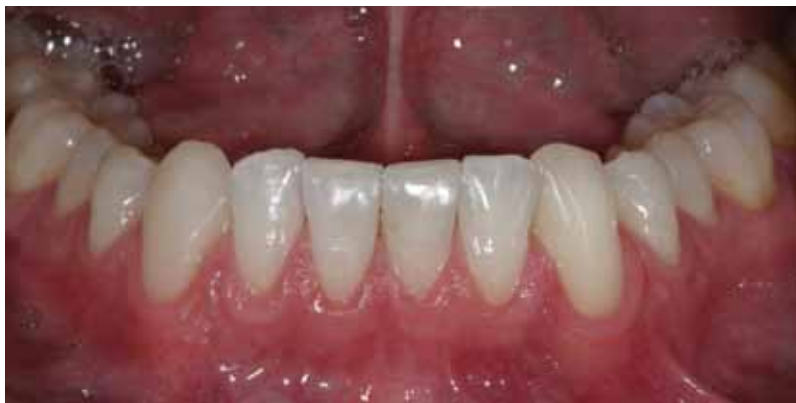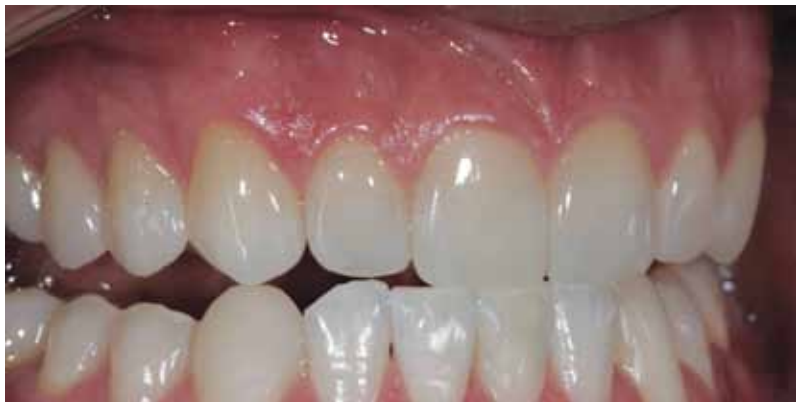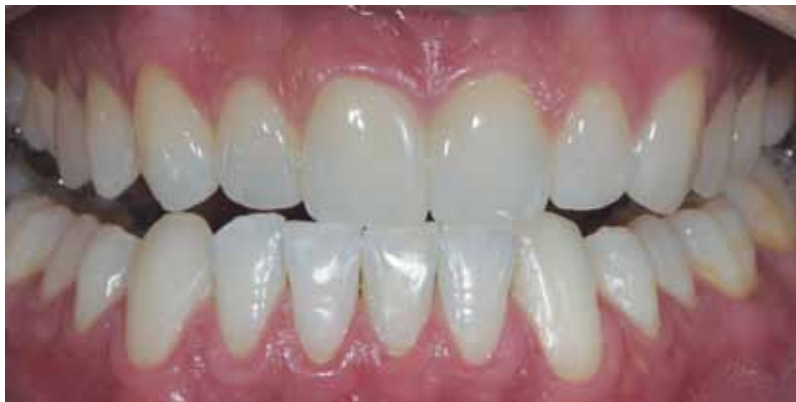The contraction stress generated from curing the adhesive composite or cement used for bonding the restoration can fracture a feldspathic veneer.

## Reality

Besides fixing a restoration in place, an important function of dental luting cements is to seal the gap between tooth and restoration. However, as a result of adhesion, curing contraction is hindered, creating stress.

Shrinkage stress in composite restorations, generated during setting, continues to be a major problem in adhesive dentistry.<sup>15,16</sup> Excessive shrinkage stress on the tooth cusps, caused by wall-to-wall contraction, may lead to cuspal distortion, marginal discrepancies, postoperative hypersensitivity, and microleakage.<sup>17,18</sup> Indirect, esthetic, bonded restorations can overcome these problems by limiting contraction stress of the polymerization reaction to the thin resin-cement layer.<sup>19,20</sup>

It is logical to assume that interfacial stresses will then be reduced for composites cured in cavities with minimally constrained surface areas.<sup>21</sup> A ceramic that is sufficiently and evenly thick, combined with a minimally thick luting composite, will provide the restoration with a favorable configuration and reduce the likelihood of cracks.

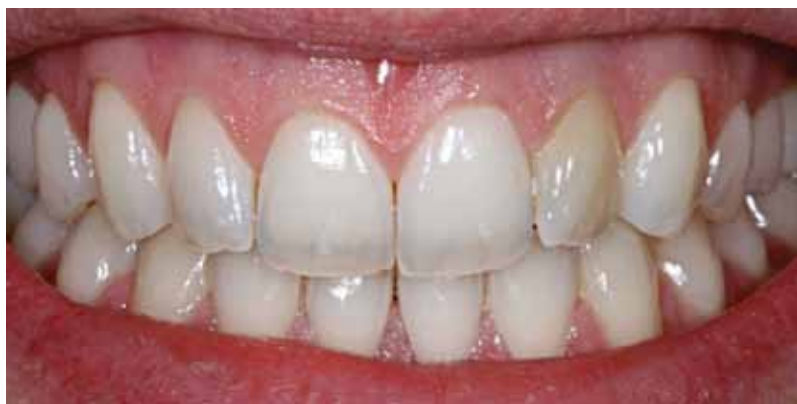

**Figures 6a-6c:** Final result after cementation. Note the tissue integration and importance of canine guidance to maintain occlusal stabilization.

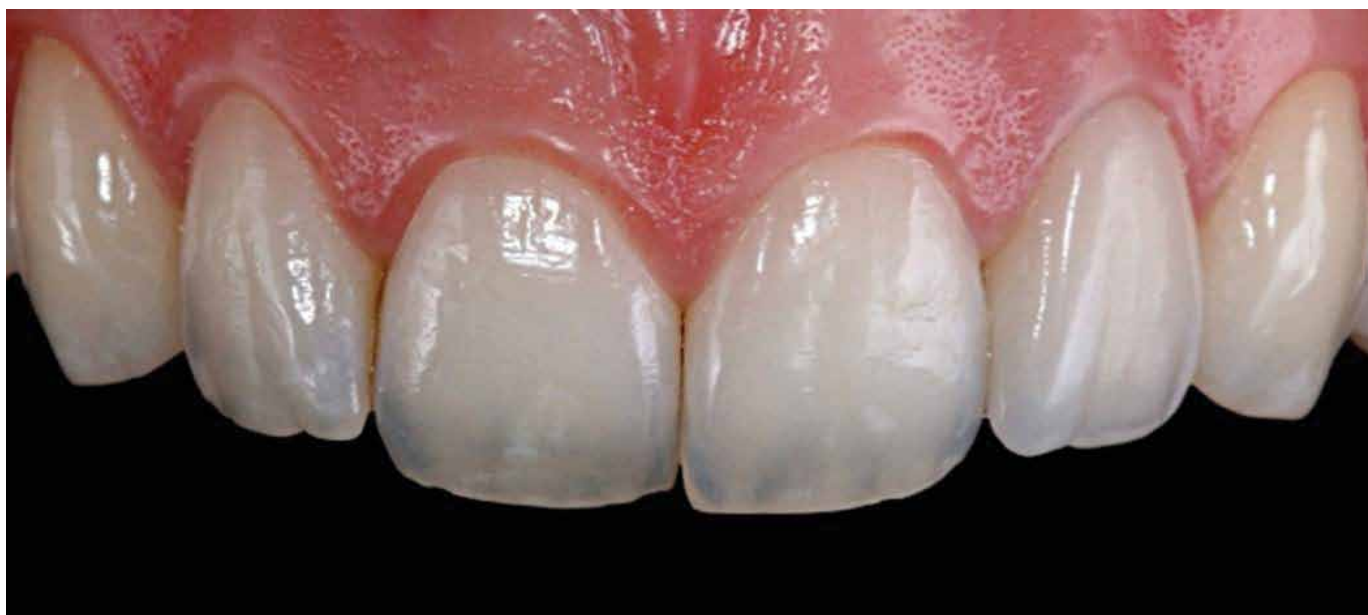## Conclusion

Medium- to long-term maintenance of porcelain veneer esthetics is excellent, patient satisfaction is high, and feldspathic porcelain veneers and lithium disilicate material have no adverse effects on the gingival health of patients with optimal oral hygiene.

An optimal bonded restoration can be achieved, especially if the preparation is located completely in the enamel, correct adhesive procedures are carried out, and a suitable luting composite is selected.<sup>22</sup> Based upon their high esthetic value and minimal preparation requirements, these materials allow dentists and technicians to provide esthetic treatments that are much less invasive—which is precisely what patients want.<sup>23</sup>



**Figure 7:** A lateral incisor with severe discoloration after endodontic treatment.

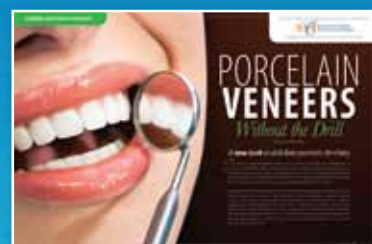
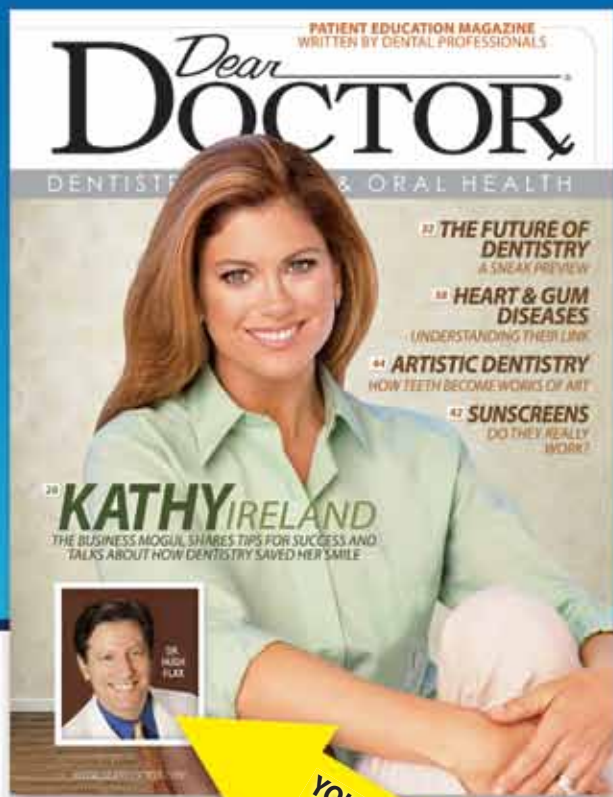
**Figure 8:** This final result was achieved due to deep preparation, which produced a veneer with adequate thickness. Selecting an appropriate shade of luting resin cement is important to obtain satisfactory esthetic results.

## References

1. Adolfi D, Andrade OS. Lithium disilicate veneers: a case report with no teeth preparation. *Spectr Dialogue*. 2011;10(9):18-35.
2. Magne P, Belser UC. Bonded porcelain restorations in the anterior dentition: a biomimetic approach. Hanover Park (IL): Quintessence Pub.; 2002.
3. Christensen GJ. Facing the challenges of ceramic veneers. *J Am Dent Assoc*. 2006 May;137(5):661-4.
4. Strassler HE. Minimally invasive porcelain veneers: indications for a conservative esthetic dentistry treatment modality. *Gen Dent*. 2007 Nov;55(7):686-94; quiz 95-6, 712.
5. DeLopez TE. Predictable pressed ceramic anterior restorations: clinical observations. *Dent Today*. 2002 Apr;21(4):68-73.
6. Christensen GJ. Has tooth structure been replaced? *J Am Dent Assoc*. 2002 Jan;133(1):103-5.
7. Gurel G. The science and art of porcelain laminate veneers. Hanover Park (IL): Quintessence Pub.; 2003.

# Cosmetic Dentistry Never Looked So Good!



## Promote Your Practice While Educating Patients.

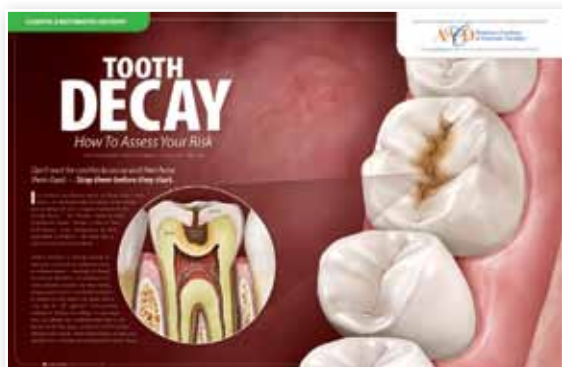
The American Academy of Cosmetic Dentistry (AACD) has partnered with *Dear Doctor – Dentistry & Oral Health* magazine to provide the very best in patient education. Now your practice can impress and educate patients while they are in your treatment room, reception area or at home with easy-to-understand articles, illustrations and answers to questions from real-world patients. But best of all, the magazines will feature your image on the cover immediately followed by full-page ads showcasing your practice.

Call **(866) 799-5014** today to receive *Dear Doctor* magazine in your office!

**Dear DOCTOR**<sup>®</sup>  
DENTISTRY & ORAL HEALTH

Learn more at [www.DearDoctor.com/aacd](http://www.DearDoctor.com/aacd)

*Dear Doctor* features articles endorsed by the





8. McLaren EA. Porcelain veneer preparations: to prep or not to prep. *Inside Dent*. 2006;2(4):76-9.
9. DiMatteo AM. Prep vs. no-prep: the evolution of veneers. *Inside Dent*. 2009;5(6):72-9.
10. Yu X, Oullet D, Ibsen R. Perio evaluation of long-term prep versus non-prep porcelain veneer restorations. *J Dent Res*. 1998;77(Spec. Iss.):954.
11. Giordano R. A comparison of all-ceramic restorative systems. *J Mass Dent Soc*. 2002 Winter;50(4):16-20.
12. Javaheri D. Considerations for planning esthetic treatment with veneers involving no or minimal preparation. *J Am Dent Assoc*. 2007;138(3):331-7.
13. Dozic A, Kleverlaan CJ, Meegdes M, van der Zel J, Feilzer AJ. The influence of porcelain layer thickness on the final shade of ceramic restorations. *J Prosthet Dent*. 2003 Dec;90(6):563-70.
14. Cavanaugh RR, Croll TP. Bonded porcelain veneer masking of dark tetracycline dentinal stains. *Pract Periodontics Aesthet Dent*. 1994;6(1):71-9; quiz 80.
15. Bowen RL, Rapson JE, Dickson G. Hardening shrinkage and hygroscopic expansion of composite resins. *J Dent Res*. 1982 May;61:654-8.
16. Hansen EK. Contraction pattern of composite resins in dentin cavities. *Scand J Dent Res*. 1982 Dec;90:480-3.
17. Peumans M, Van Meerbeek B, Lambrechts P, Vanherle G. The five-year clinical performance of direct composite additions to correct tooth form and position. part I: esthetic qualities. *Clin Oral Investig*. 1997 Feb;(1):12-8.
18. Pincus CR. Building mouth personality. *J South Calif Dent Assoc*. 1938;14:125-9.
19. Simonsen RJ, Calamia JR. Tensile bond strength of etched porcelain. *J Dent Res*. 1983;62:297, abstract 1154.
20. Horn RH. Porcelain laminate veneers bonded to etched enamel. *Dent Clin North Am*. 1983 Oct;27:671-84.
21. Ferracane JL. Developing a more complete understanding of stresses produced in dental composites during polymerization. *Dent Mater*. 2005 Jan;21:36-42.
22. Peumans M, Van Meerbeek B, Lambrechts P, Vanherle G. Porcelain veneers: a review of the literature. *J Dent*. 2000;28:163-77.
23. McLaren EA, LeSage B. Feldspathic veneers: what are their indications? *Compend Contin Educ Dent*. 2011 Apr;32(3):44-9. **JCD**



An optimal bonded restoration can be achieved, especially if the preparation is located completely in the enamel, correct adhesive procedures are carried out, and a suitable luting composite is selected.



Dr. Adolfi is the director of Spazio Education in São Paulo, Brazil. He also has a private practice in São Paulo.

Disclosure: The author did not report any disclosures.

// **Dentists must embrace the responsibility of understanding the myths and realities of the different ceramic materials available, their benefits, and their limitations.** //

### **Dr. Fradeani Discusses the Realities of Pressed Porcelain Veneers**

With the increase in cosmetic procedures, questions often arise regarding the least technique-sensitive yet most durable and esthetic veneering materials available. Depending upon the material in question, veneer preparations traditionally required anywhere from 0.3 mm to 1.5 mm of natural tooth reduction to provide successful restorations that appeared consistent with the surrounding dentition. Recently introduced materials, however, demonstrate many advantages compared with traditional materials. For instance, with some pressed ceramic materials, the clinician can provide a successful veneer restoration with a coping as thin as 0.16 mm.

Today's dentists often are too busy (or satisfied with the status quo) to invest the much-needed time to educate themselves about the myriad material properties, advantages, and nuances of each newly introduced material. However, to provide their patients with the most successful, minimally invasive treatments available, dentists must embrace the responsibility of understanding the myths and realities of the different ceramic materials available, their benefits, and their limitations.

## Myth

Pressed veneers require more aggressive preparation than other restorative modalities.

## Reality

Because a core is required upon which to layer porcelain and because porcelain can be layered from zero to virtually any thickness, it is true that pressed veneers have traditionally required more aggressive preparation. Until more recent materials were developed, blending pressable ceramic materials with surrounding dentition required extra room—and therefore tooth reduction—to provide space to esthetically apply veneering porcelain to the pressed ceramic.<sup>1,2</sup> To maintain the natural emergence profiles while achieving acceptable esthetics, more aggressive tooth preparation proved necessary.<sup>1,3</sup> While feldspathic veneers required only 0.3 mm to 0.5 mm reduction of natural tooth structure, some authors believe that pressed ceramics require a minimum of 0.75 mm.<sup>1,4</sup> However, many practitioners, including this author, who use such material, especially the more recent glass ceramics (lithium disilicate), observed that the monolithic version of this material can be thinned down to 0.2 mm to 0.3 mm without any clinical problem if it is bonded on enamel. Moreover, when considering veneer preparations, several factors must be considered, including space requirements, working thickness, and amount of dentin exposed.<sup>5</sup> As a result, case requirements vary from patient to patient and often veneer preparations—even for pressed ceramics—can be much thinner.

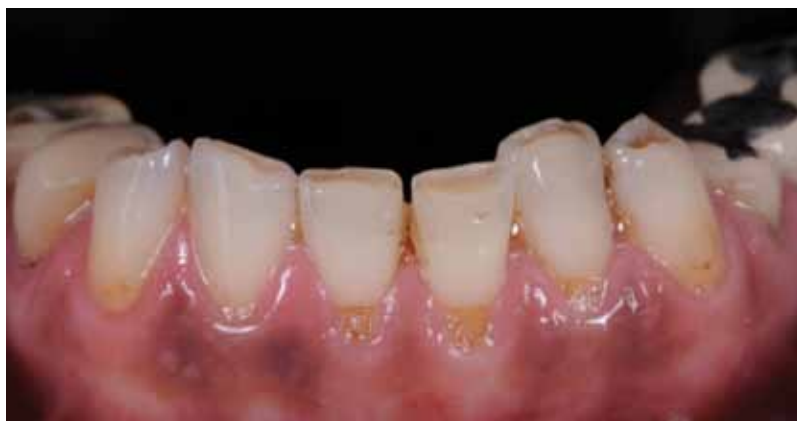In many cases, pressed veneers are used to add volume to the original teeth. In fact, this author uses pressed veneers quite often to add volume when patients request a fuller, more prominent smile. In such cases, most of the time the thickness exceeds 1 mm. In these cases it is possible to easily gain enough space for both the coping and veneering material.

## Myth

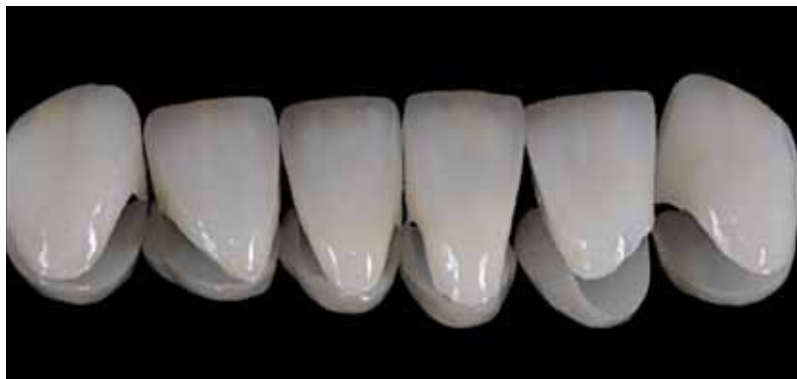Pressed veneers lack the capability to produce the life-like optical metamerisms that feldspathic porcelain can offer.

## Reality

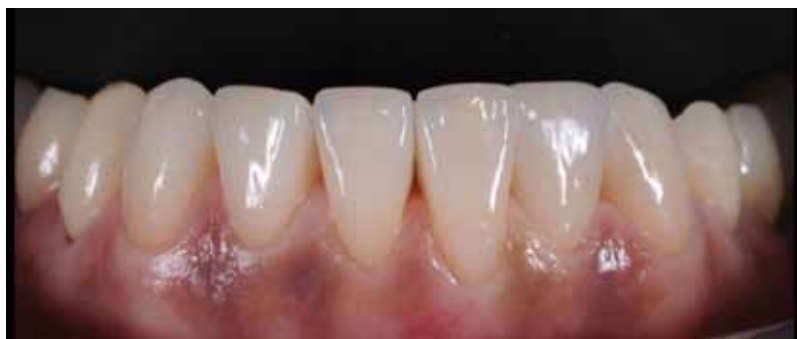Prior to the development of the pressed ceramic veneer material available today, this was true. However, in the modern world of glass ceramics, there are numerous ingots available that allow blending of a veneer with the patient's surrounding natural dentition (Figs 1-3). For instance, lithium disilicate ingots (IPS



**Figure 1:** Initial view showing an unsatisfactory esthetic and structural appearance.



**Figure 2:** The patient was treated with a full-mouth rehabilitation that required fabrication of six anterior veneers in the lower arch.



**Figure 3:** The final view shows a satisfactory esthetic result, with a more harmonious anatomy, better alignment, and overall esthetic and biological integration.



e.max, Ivoclar Vivadent; Amherst, NY) are available in high translucency, low translucency, medium opacity, and high opacity, as well as in values 1, 2, and 3. With such a variety of shades, translucencies, and opacities, it is easy to match the appropriate translucency, color, shade, and nuance to achieve a highly esthetic and prominent smile for the patient. In fact, when providing treatment for a posterior restoration, in most cases it is possible to choose a monolithic material and eliminate layering the coping and still obtain a superb result.

Although it is true that feldspathic porcelain offers outstanding optical qualities, its lack of strength must be considered. Feldspathic porcelain veneers demonstrate the lowest strength of all available veneer materials at 70 MPa to 90 MPa;<sup>1,6</sup> whereas the strength of leucite-reinforced glass-ceramic is approximately 180 MPa in vitro, which is much stronger; and that of lithium disilicate is approximately 400 MPa. Glass-ceramic porcelain is strong and durable, and with sufficient tooth structure and enamel to provide support and retention, failure rates due to fracture or breakage are extremely low.<sup>7-10</sup>

## Myth

The cut-back technique to produce incisal characterization for pressed porcelain veneers is more prone to fracture than feldspathic veneer restorations.

## Reality

In this author's experience, that has not proven true. In fact, pressable ceramics were developed to address the lack of strength in feldspathic veneer restorations.<sup>1,2</sup> It has already been established from clinical research that leucite-reinforced glass-ceramic (IPS Empress), the first of the new generation pressable ceramics, has demonstrated an outstanding success rate of approximately 95%.<sup>9,10</sup> Pressed porcelain veneers are strong and durable and suitable for a wide range of dental restorations.<sup>1,2</sup> Specifically manufactured with increased density, they demonstrate flexural strengths up to 180 MPa, resisting fracture and providing more durable restorations than feldspathic veneers.<sup>1,2</sup>

Due to its composition, higher density, and superior edge strength, a third generation of pressable ceramic material, such as lithium disilicate, boasts a strength of 400 MPa and can be finished thinner without chipping. Today, this author relies more and more upon lithium disilicate, which demonstrates more strength in vitro than leucite-reinforced glass-ceramic. Therefore, fracturing or chipping of pressable ceramic veneers fabricated with these materials is of very little concern.

## Myth

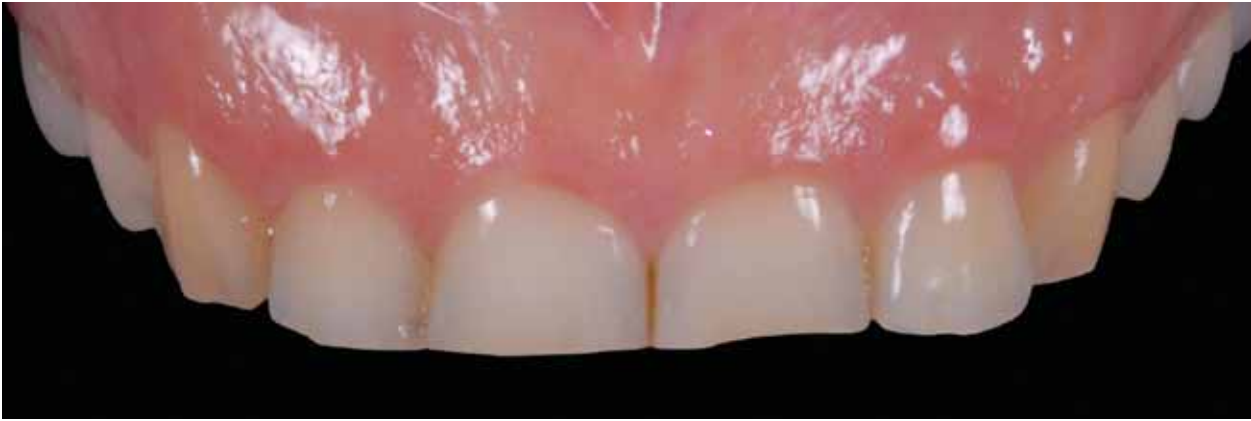
Because of the addition of leucite crystals in pressed ceramic systems, it lessens the amount of silica for bonding, making pressed ceramic restorations less bondable than feldspathic.

## Reality

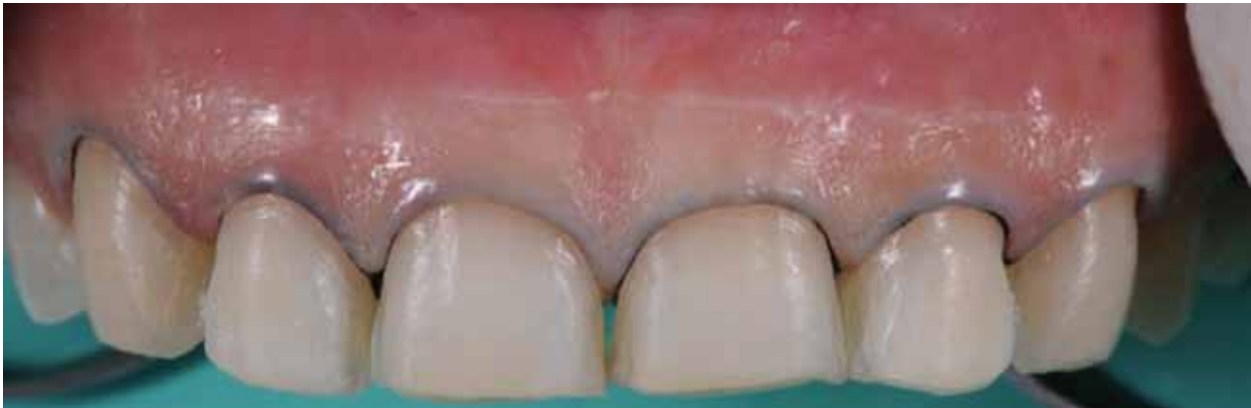In 1990, laboratory technician Giancarlo Barducci and this author were one of the first teams to test leucite-reinforced glass-ceramic (IPS Empress) in Europe. Bonding, even when using the techniques popular more than 20 years ago, never proved an issue. Data from many clinicians has proven that, regardless of whether clinicians bond feldspathic porcelain or pressed ceramic, as long as the adhesive step is performed properly, a durable and lasting bond will be obtained.<sup>11</sup> It is true that the concentration of leucite within the pressed ceramic correlates to the strength of bond between the resin composite cement and the etched porcelain.<sup>11</sup> In fact, porcelain manufactured with a high-leucite content was introduced in an effort not only to improve material properties but also to increase the strength of the bond between the porcelain and resin composite cement.<sup>11</sup> High-leucite content porcelain material demonstrates between 49% and 51% leucite concentration, while leucite content in feldspathic porcelain will vary from 20% to 30%.<sup>11</sup> When porcelain contains a high-leucite content, etching generates an increase in smaller micro-porosities that may provide a stronger bond to resin composite.<sup>11</sup>

Materials available today provide solutions to many challenges when restoring dentition, and dentists consider more than just the adhesive issue when choosing a material. There are several factors considered with each individual restoration. Among glass ceramics, lithium disilicate is four times stronger than feldspathic porcelain. Its use is recommended especially in cases where there is an insufficient quantity of enamel substrate, and when a considerable amount of tooth length is needed. Moreover, consider a technician who must fabricate six veneers with feldspathic porcelain, and the case must be delivered the next day. If something is wrong with the color, in most such cases, it cannot be corrected. Therefore, the restorations will need to be remade and the case will not be delivered on time. On the other hand, with a glass-ceramic restoration such as a leucite crystal or lithium disilicate ceramic, the color can be changed by relayering the restoration, and the case delivered on time. Clinically speaking, for the dentist, the technician, and the patient, it is much easier to finalize a case using glass-ceramic materials.

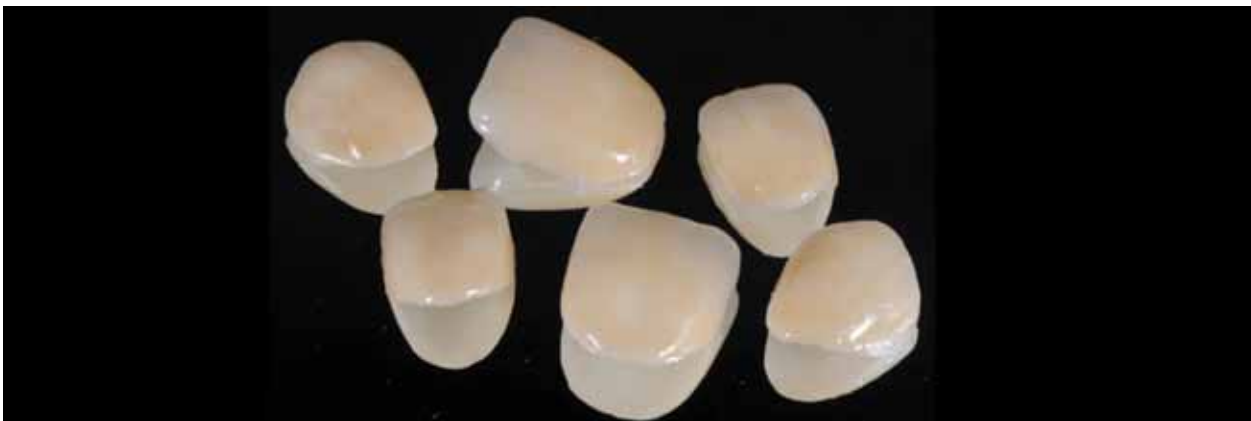Additionally, studies have indicated that for feldspathic veneers to achieve a successful bond, at least 50% of the enamel is required to bond to the substrate, and at least 70% of the margin must be positioned within the enamel.<sup>1,2</sup> Today, with a strong material such as lithium disilicate, clinicians can remove less tooth structure and retain as much enamel as possible—also on the posterior areas—to create durable, completely enamel overlays or even full-crown design, as in the minimally invasive prosthetic procedure (MIPP) technique.<sup>12</sup> By reducing the thickness of the lithium disilicate in full anatomy of the posterior to 0.8 mm, it is possible to still bond onto the enamel. This provides enhanced restorative strength that can be compared to a posterior crown with 1.5 mm thickness that is cemented completely to dentin. Therefore, using a durable monolithic material with this technique maintains the structure and anatomy of the tooth while preserving the enamel and providing a much less invasive, yet successful, treatment.



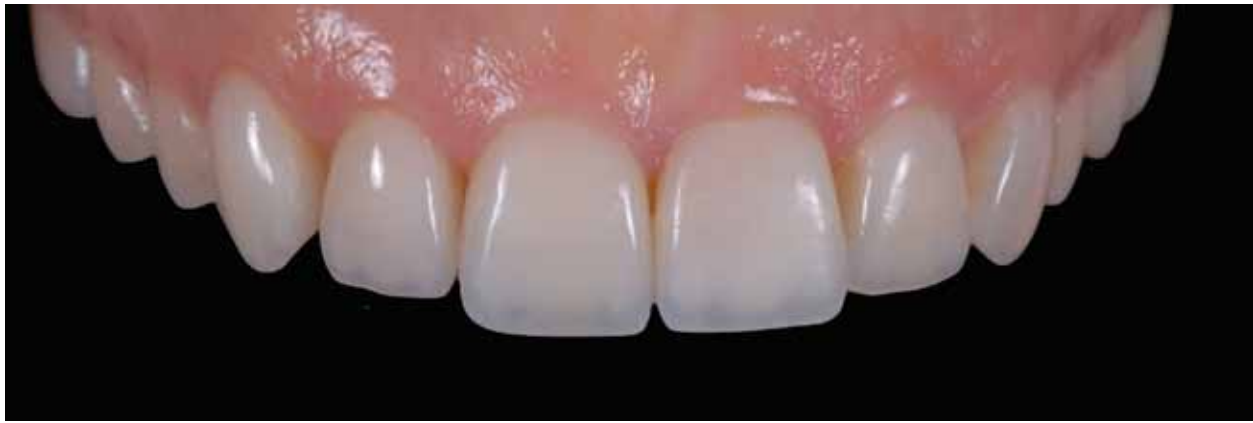**Figure 4:** The patient exhibits a flat reverse incisal edge due to tooth attrition.



**Figure 5:** The tooth preparation shows complete maintenance of the enamel substructure, which will be fundamental in achieving the best bonding.



**Figure 6:** The thickness of the six anterior veneers exceeds 1 mm in some areas due to the addition of volume in the incisal and buccal areas.



**Figure 7:** The strength of the ceramic material played a very important role in this clinical case, where the final tooth length was optimized courtesy of a substantial amount of unsupported ceramic (4 mm).

## Conclusion

With myriad dental materials available, dentists have an abundance of choices for restoring affected dentition. Contingent upon tooth location, treatment modality, and esthetics, as well as other circumstances, often more than one material is required for treatment. With the concept of minimally invasive dentistry guiding treatment today, multifaceted and versatile materials are continually being introduced. Earlier materials still serve successfully for certain indications, but when pressed ceramic materials are available, dentists can consider their many advantages. Although feldspathic porcelain is hailed for its esthetic properties, pressed ceramics demonstrate enhanced physical properties, stronger flexural strength, and fracture toughness (Figs 4-7); provide durability and, now, enhanced esthetics; and have proven successful for many indications.

## References

1. McLaren EA, LeSage B. Feldspathic veneers: what are their indications? *Compend Contin Educ Dent*. 2011 Apr;32(3):44-9.
2. McLaren EA, Cao PT. Ceramics in dentistry—part 1: classes of materials. *Inside Dent*. 2009;5(9):94-103.
3. Roulet JF, Degrange M. Adhesion: The silent revolution in dentistry. Hanover Park (IL): Quintessence Pub.; 2000.
4. Friedman MJ. A 15-year review of porcelain veneer failure—a clinician's observations. *Compend Contin Educ Dent*. 1998;19(6):625-30.
5. LeSage B, Wells D. Two viewpoints on prepared veneers and prep-less veneers. *J Cosmetic Dent*. 2011 Summer;27(2): 66-76.
6. Giordano R. A comparison of all-ceramic restorative systems. *J Mass Dent Soc*. 2002;50(4):16-20.
7. Cho GC, Donovan TE, Chee WW. Clinical experiences with bonded porcelain laminate veneers. *J Calif Dent Assoc*. 1998 Feb;26(2):121-7.
8. Strassler HE, Nathanson D. Clinical evaluation of etched porcelain veneers over a period of 18 to 42 months. *J Esthet Dent*. 1989 Jan;1(1):21-8.
9. Fradeani M. Six-year follow-up with Empress veneers. *Int J Periodontics Restorative Dent*. 1998;18:217-25.
10. Fradeani M, Redemagni M, Corrado M. Porcelain laminate veneers: 6- to 12-year clinical evaluation—a retrospective study. *Int J Periodontics Restorative Dent*. 2005 Feb;25(1):9-17.
11. Lopes MB, Sinhoreti MA, Correr Sobrinho L, Consani S. Comparative study of the dental substrate used in shear bond strength tests. *Pesqui Odontol Bras*. 2003 Apr-Jun;17(2):171-5. Epub 2003 Oct 10.
12. Fradeani M, Barducci G, Bacherini L, Brennan M. Esthetic rehabilitation of a severely worn dentition with minimally invasive prosthetic procedures (MIPP). *Int J Periodontics Restorative Dent*. 2012 Apr;32(2):135-47. **JCD**



Dr. Fradeani is associate editor of *The European Journal of Esthetic Dentistry*. A past president of the European Academy of Esthetic Dentistry and of the Italian Academy of Prosthodontics, he maintains a private practice specializing in esthetics and prosthetic rehabilitation in Pesaro, Italy.

Disclosure: Dr. Fradeani is a consultant for and receives material support from a number of companies, including Ivoclar Vivadent. He did not, however, receive any financial remuneration for this article.



All-new AACD live education experience series

# AACD Unplugged

Madison, WI | September, 2012

The Best is Yet to Come! But Who Will it Be?

This September, the AACD will host the second edition of AACD Unplugged at the Executive Office in Madison, Wis. Plan on joining us for live cosmetic dental education in an intimate setting under the direction of a master clinician. You'll learn, grow, and be inspired in one amazing weekend.

Who is this master clinician? Watch for updates as we unveil the next AACD Unplugged presenter!

Attendance extremely limited.  
Learn more at [www.aacd.com/unplugged](http://www.aacd.com/unplugged)

 American Academy  
of Cosmetic Dentistry®

# A PICTURE is *Worth...*

## A Three-Step Process for Taking Better Photographs

Alessandro Devigus, Dr.Med.Dent.



### Abstract

Digital photography is a constantly evolving medium that can be used in daily practice for a number of applications, including documentation and patient education. There is no “mystery” to taking quality images when simple rules are followed. The three most important steps in successful dental photography are selecting the right equipment, selecting the right settings, and improving basic photographic set-ups. Following these rules provides the ability to take photographs at a high level of quality on a daily basis. This article highlights some of these points to motivate readers to start taking pictures.







**Figure 1:** Taking three images of a clinical situation from the same angle makes the series look more professional.

Establishing effective and consistent methods for capturing images is critical to faithfully recording and conveying clinical results.

### Introduction

Imagine that you have just completed a clinical case, and you and the patient are both very pleased with the esthetic outcome. The restoration looks beautiful. Suddenly, you think: "Why didn't I take pictures before I started? This would have been a nice case to present or publish." Unfortunately, there is no way to turn back the clock and obtain these images.

Taking pictures is still not considered a standard procedure in daily practice. Yes, we do take pictures of extensive cases for our publications, presentations, lectures, and legal matters.<sup>1</sup> But this is not enough.

Furthermore, the author does not see many published articles in which a photographic protocol has been established or is strictly followed.<sup>2</sup> Certainly, the number of articles on clinical photography has grown since digital photography became affordable and, therefore, has become more popular.<sup>3,4</sup> However, no uniform procedures for producing high-quality dental photographs currently exist for authors and publishers.

Establishing effective and consistent methods for capturing images is critical to faithfully recording and conveying clinical results.<sup>5,6</sup> Varying angles of view and different degrees of cropping can not only make it difficult to compare before-and-after images, but it may also have an effect on the photograph's accuracy.

The author has reviewed many articles submitted for publication to *The European Journal of Esthetic Dentistry*. They range in quality from very poor to excellent, especially regarding the images.

It seems to be a challenge to combine clinical skills with an appropriate level of photographic documentation. Nevertheless, the author encourages readers to take more images. With digital photography, additional images do not create additional cost, but the information they provide is priceless.

### Three-Step Process

Taking great images is part of a three-step process:

- choosing the right equipment
- selecting the right settings
- improving the photographic set-up.

With the proper equipment and settings, the following tips can improve your photographic skills.

### Choose the Correct Angle



The most common error in dental photography is choosing an incorrect angle of view that leads to distorted and unnatural-looking images.

To avoid or correct this mistake, try to position the patient in the chair to get a straight horizontal view. If necessary, let the patient move his or her head to look at you. If you take a photo of a smile, aim at the center of the papillae of the central incisors. This creates the appearance that you have taken an "upside down" photograph, which will put the image on a horizontal plane. In addition, it is important not to change the angle of view while documenting a clinical case. Keep the same angle throughout the shooting (**Fig 1**). This small correction will make even the simplest of cases look much more professional.

Before starting documentation, think about the possible angles of view available. Ask yourself if there is a constant angle of view throughout the whole photo session.

## Three-Step Process

Taking great images is part of a three-step process:

- choosing the right equipment
- selecting the right settings
- improving the photographic set-up.

### Tip:

Consider taking pictures as a standard procedure in your daily practice.

## Position the Patient

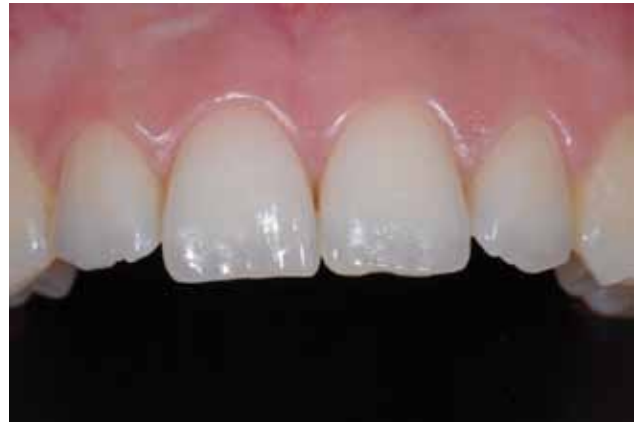

Position the patient to get a straight horizontal view.

**Figure 2** demonstrates the typical result when a patient sits in the chair with his or her head in a backward position. Notice that the teeth look too long (distorted) and the flash hits the incisal part of the surface of the front teeth.

To achieve a better angle of view, aim at the papillae in between the two incisors. The camera's flash is then reflected much better (**Fig 3**).

Try to take an image from "above" for an even better result. By doing so, it is possible to capture a horizontal view of the teeth (**Fig 4**).



**Figure 2:** Image with the patient's head in a backward position. Standing in front of the patient and trying to take photos produces an unwanted angle of view; light from the flash hits the incisal edge, the highlights remove important information, and the tooth looks unnaturally long.

## Improve Depth of Field



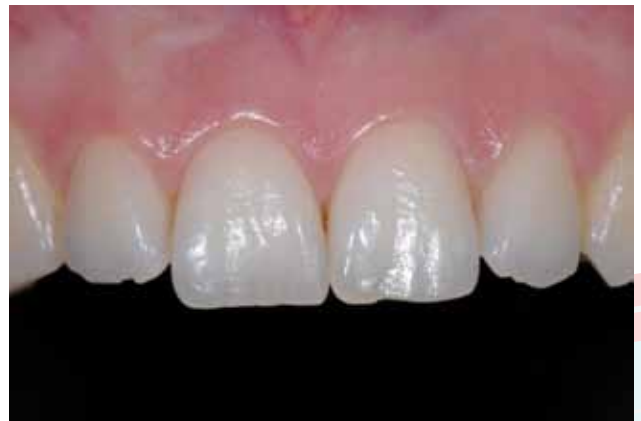Another common mistake in dental photography is taking images that are out of focus. When taking intraoral images, you should use a macro lens, be relatively close to the subject,<sup>7</sup> and work with a small aperture (higher f-stop number = small aperture). This leads to a deeper depth of field in this photographic setting. When working with a close focusing distance, try focusing at the optimal plane in the canine and premolar area of the patient's mouth to achieve a better image result.

To obtain sharper images, try the following:

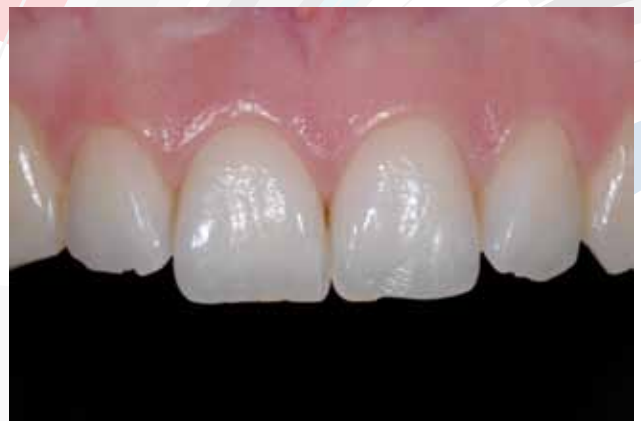- Switch the lens to manual focus mode. Focus on the front teeth. With this fixed focus, move the camera slightly closer to the patient. This small shift adjusts the focus from the incisors to the canine or premolar region.
- Snap the shutter; this should guarantee that nearly everything is in focus.

Getting closer to the patient has another advantage. Most cameras show only 95% of what will be shown on the viewfinder. Moving closer also crops unwanted structures and tissues and makes the images appear even better without the need to manually crop later.

Avoid using autofocus when taking intraoral pictures, which wastes precious depth of field in front of the patient's mouth. Focus on the front and move slightly closer to the level of the canines or premolars. This prevents blurring (**Fig 5**). Almost all the teeth will be in focus if you follow this rule.



**Figure 3:** A corrected, horizontal angle of view in which the patient has been repositioned. When attempting this angle, aim the lens on the papillae between the incisors.

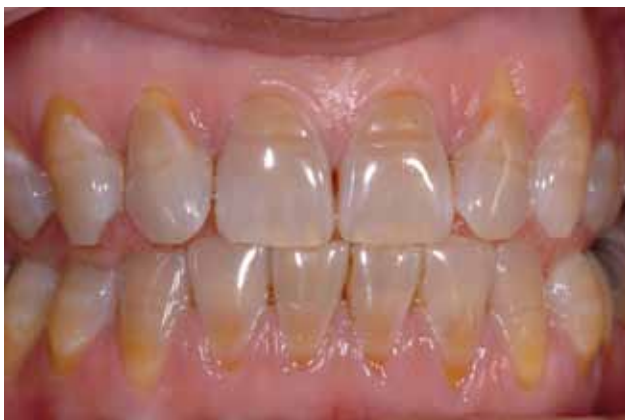

**Figure 4:** Consider taking a photograph from an even higher position. When you think you are shooting from directly above the patient, you may be straight. Try to take several shots and select the best one. Notice the uniform light reflections on the tooth surface in this high-position angle.





## Light Diffusers and Reflectors



**Figure 5:** Avoid using autofocus when taking intraoral pictures. This prevents blurring, which is evident in this image that starts at the premolars.



**Figure 6:** Placing a small light diffuser cup on top of the flash creates a uniform flash, eliminates the “red eye” effect, and creates a professional look.

By adding a light diffuser to the flash, you create a uniform, soft illumination of the patient’s face.

Two small and efficient tools that can help to obtain consistently great portrait images are light diffusers and reflectors. By adding a light diffuser to the flash, you create a uniform, soft illumination of the patient’s face. Additionally, using a reflector (silver when the patients are tan and gold when they look a little pale) can achieve better light flow and illumination of the patient, which eliminates “dark shadows” below the eyes. A gold reflector can also make patients look healthier.

Attach a small light diffuser cup on top of the flash. This helps diffuse the flash’s light so as to avoid direct light, which creates shadows and red eyes (**Fig 6**).

Use a double-sided reflector with a diameter of approximately 30 inches, and have the patient hold it horizontally in front of his or her chest (**Fig 7**).

While continuing to use manual exposure mode, change the aperture setting to around 5, which creates a slight blur around the face. Position the patient in front of a white or gray background (not too close, to avoid shadows) (**Fig 8**).



**Figure 7:** This two-sided reflector should be positioned below the patient’s chin. The silver side creates a colder reflection, and the gold produces a warmer reflection. Depending on the patient’s skin type, either side can be used. This helps eliminate unwanted shadows below the eyes and chin.



## Summary

Digital photography can not only help improve your practice and your patients' satisfaction, but it can also promote you in the dental community. Presenting quality images, particularly to colleagues at conferences and study clubs, can create a positive impression of your practice.

## References

1. Bengel W, Devigus A. Preparing images for publication. part 2. *Eur J Esthet Dent.* 2006;1:112-27.
2. Chu SJ, Devigus A, Paravina R, Mielezsko A. *Fundamentals of color: shade matching and communication in esthetic dentistry.* 2nd ed. Hanover Park (IL): Quintessence Pub.; 2010.
3. Bengel W. *Mastering digital dental photography.* Berlin: Quintessence Pub.; 2006.
4. Shagam J, Kleiman A. Technological updates in dental photography. *Dent Clin North Am.* 2011;55(3):627-33, x-xi.
5. McLaren EA, Schoenbaum T. Digital photography enhances diagnostics, communication, and documentation. *Compend Contin Educ Dent.* 2011;32(Spec. No. 4):36-8.
6. Salat A, Devoto W, Manauta J. Achieving a precise color chart with common computer software for excellence in anterior composite restorations. *Eur J Esthet Dent.* 2011;6(3):280-96.
7. CambridgeInColour.com [Internet]. Understanding depth of field in photography. Available from: <http://www.cambridgeincolour.com/tutorials/depth-of-field.htm>. **jCD**

With digital photography, additional images do not create additional cost, but the information they provide is priceless.



**Figure 8:** Portrait taken with the aid of a light diffuser and golden reflector. In portrait photography, do not aim for great depth of field. Set the aperture to around 5, which creates a slight blur around the face for a soft effect.



Dr. Devigus is editor-in-chief of *The European Journal of Esthetic Dentistry*. He owns a private practice in Bülach, Switzerland.

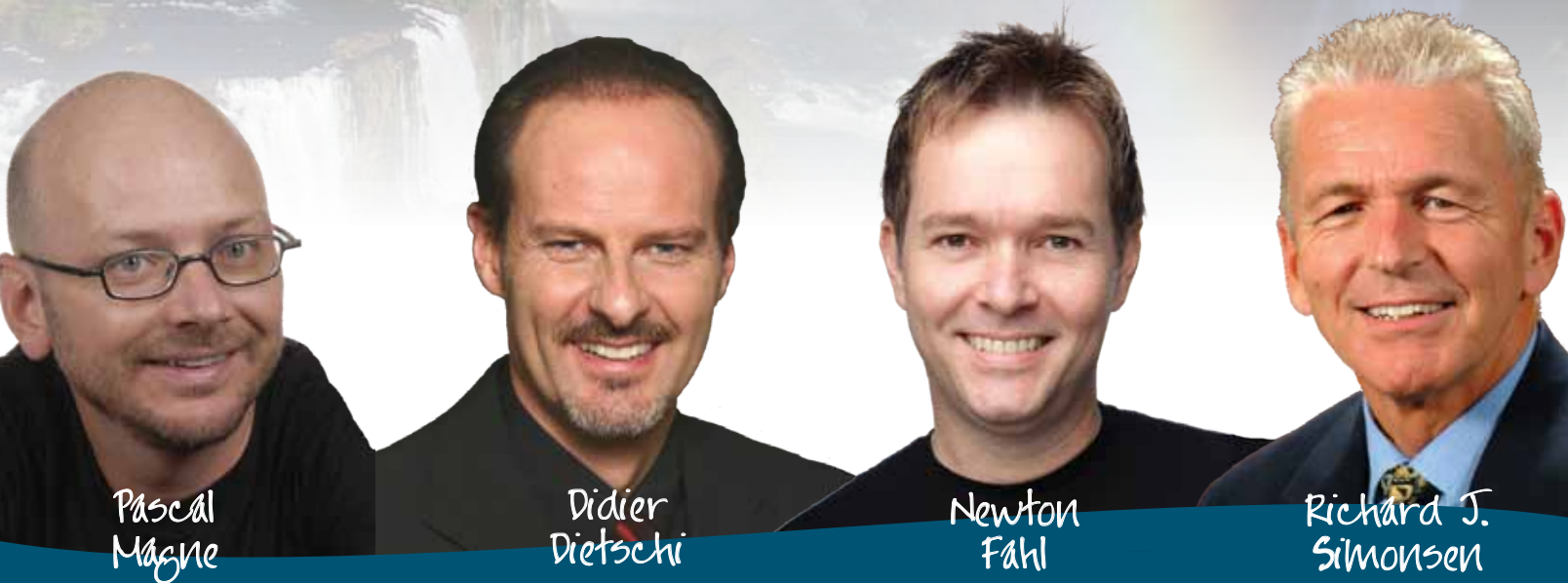Disclosure: The author did not report any disclosures.



# VI Fahl Alumni Meeting

November, 15 to 17, 2012 - Iguassu Falls . Brazil

Learn from the Masters at one of the  
7 Natural Wonders of the World  
Iguassu Falls - Brazil



Pascal  
Magne

Didier  
Dietschi

Newton  
Fahl

Richard J.  
Simonsen

**For registration and information**

e-mail [fahlcenter@gmail.com](mailto:fahlcenter@gmail.com)  
or call Intl. + 55 41 3224-3008

The lectures will be in English.

Location: Mabu Thermas & Resort  
Phone: +55 41 3219-1120  
[www.hoteismabu.com.br](http://www.hoteismabu.com.br)

ULTRADENT  
PRODUCTS, INC.

Tokuyama Dental

3M ESPE

sirona

Heraeus  
Kulzer

COSMEDENT

ivoclar  
vivadent

BISCO


VOCO

FAHL  
Art & Science  
In Aesthetic Dentistry



# TRANSLUCENCY

## Determinants of



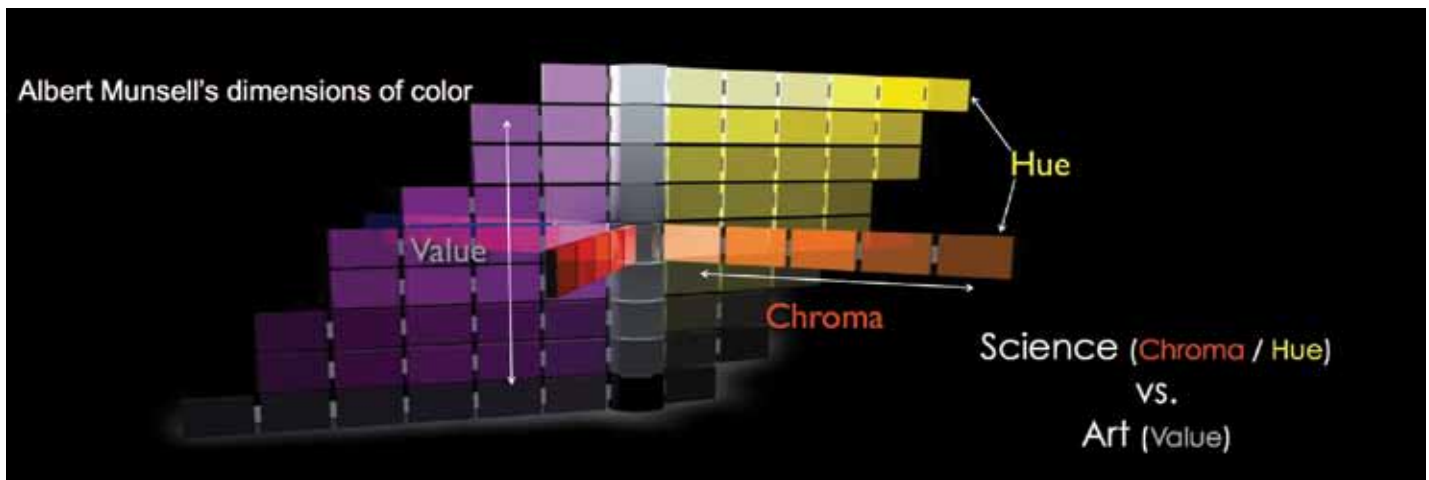
# Natural Teeth

## Replicating Nature with Porcelain Laminate Veneers

Jason J. Kim, CDT

### Abstract

When it comes to the creation of highly esthetic, natural-looking porcelain laminate veneers (PLVs), dental technicians have a plethora of options available from a multitude of material manufacturers. Although the great majority of off-the-shelf materials are well suited for cases in which the goal is to match the patient's natural tooth shade, many patients today demand the whitest teeth possible, which are much whiter and brighter than nature ever intended. Therefore, bleach-white shades present quite a challenge for the ceramist: How to satisfy the patient's expectations for ultra-white veneers, while also ensuring that the restorations "behave" and interact with light in a way that maintains natural opacity and translucency. Through scientific densitometer analysis of natural enamel slices, and then modifying existing feldspathic porcelain materials accordingly, this article describes the potential for any skilled ceramist to produce PLVs in the bleach-white range that possess translucency and opacity values nearly identical to natural enamel.



**Figure 1:** The dimensions of color: hue, value, and chroma. In esthetic restorative dentistry, it is a delicate balance between science and art. (From *Fundamentals of Color: Shade Matching and Communication in Esthetic Dentistry* [chapter 1, Color Theory, p. 17], by Stephen J. Chu, Alessandro Devigus, and Adam Miesleszko.)

“The greatest challenge to producing perfect restorations is making sure they interact with light the way natural teeth do.”

## Introduction

Providing patients with restorations that replicate natural teeth in size, form, and function<sup>1,2</sup> is *not* one of the greatest challenges dental professionals face today. Using the right tools, materials, and techniques, all of these anatomical parameters can be accomplished readily and with great success in the dental laboratory.<sup>1,2</sup> Rather, the greatest challenge to producing perfect restorations is making sure they interact with light the way natural teeth do. In other words, the light interacting with the restoration must be absorbed, transmitted, and dispersed similarly to the way nature intended.<sup>3-5</sup> For this to happen, the restoration must be made from an all-ceramic material that possesses the same, or nearly similar, properties of natural tooth enamel.<sup>3-5</sup>

## Understanding Color

Creating restorations in the laboratory today is as much an art form as it is a science<sup>6</sup>—in this case, the science of color and its necessary component, light.

After all, without light, there can be no color.

If we are asked to describe a three-dimensional object, we can identify its height, width, and depth. Color similarly has three basic attributes: hue, value, and chroma<sup>3</sup> (Fig 1).<sup>7</sup> *Hue* is the easiest to identify and the element that is most often referred to simply as an object’s “color.”

*Value* is defined as the relative lightness or darkness of a color. The value or brightness of a color is based upon the amount of light emanating from that color. The easiest way to remember value is to visualize a gray scale, which runs from black to white and contains all the possible monochromatic grays. The brighter the color is, the higher its value.

*Chroma* does not deal with light reflectance, but rather the strength or purity of a certain color. We often refer to chroma as the intensity or saturation of a color (i.e., how bright or dull it is). Chroma is the degree to which a hue departs from full intensity toward

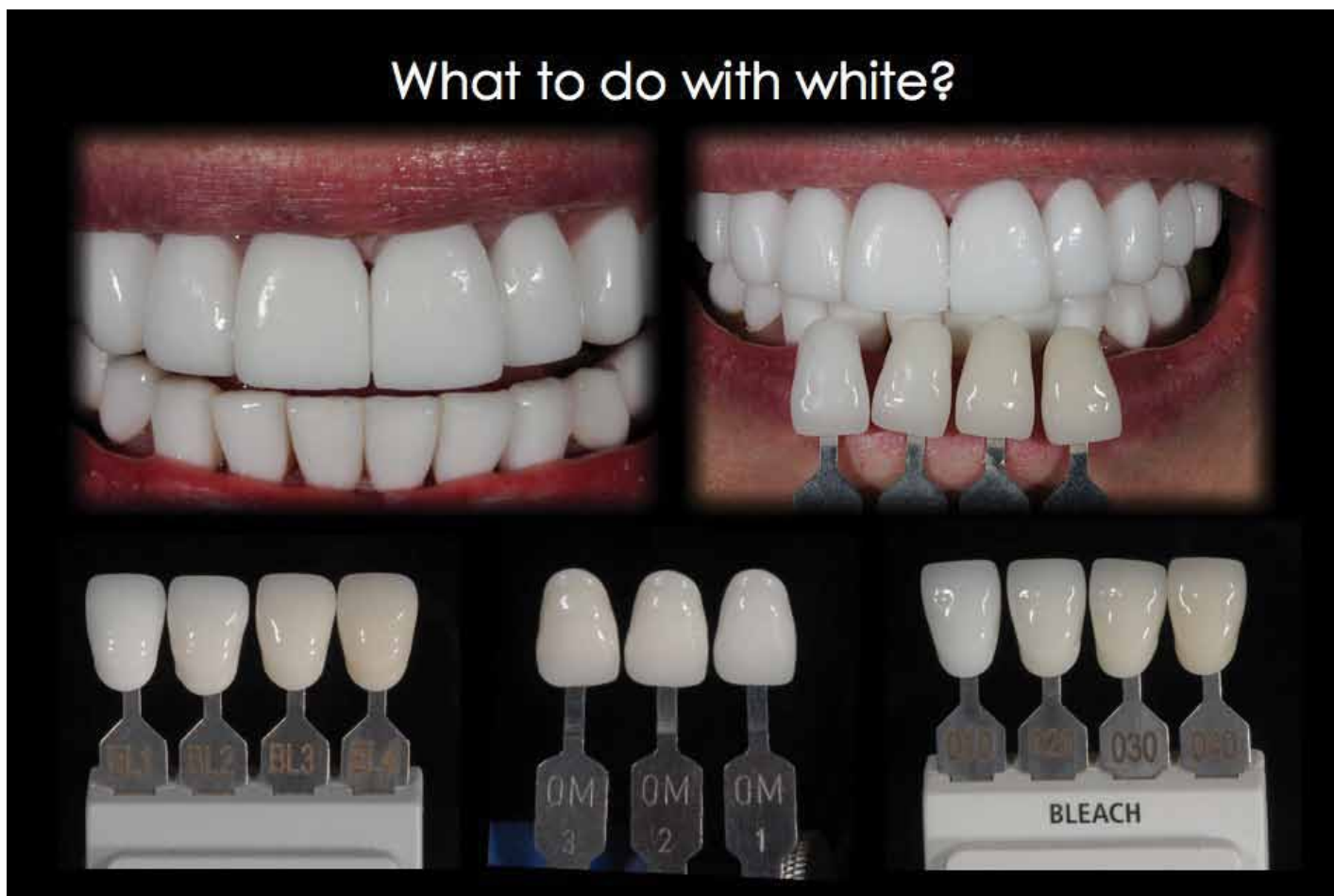
a neutral gray. Although both hue and chroma can be measured by machine, the value of color cannot.

With respect to hue, value, and chroma, replicating the correct value of a porcelain laminate veneer has always been the most difficult. Value represents the visual depth of a tooth and is directly influenced by opacity and translucency.

## Methods of Reproducing Visual Depth on Dental Restorations

A natural, unrestored tooth interacts with light in three ways: light is absorbed by it, transmitted through it, and dispersed away from it. Most ceramic restorations possess these qualities to some degree, as they are translucent and allow the light to pass through, which imparts depth, dimension, and vitality to the tooth. Conversely, a porcelain-fused-to-metal crown can only absorb and reflect light; it does not allow light to pass all the way through the tooth,





**Figure 2:** Ultra-white shades create a “cue ball” effect because there is no translucency.

often making it appear flat and without depth or vitality.

As if dealing with the dynamic interplay of light on the visual perception of dental restorations is not challenging enough, another obstacle has emerged in recent years: the introduction of bleach-white and ultra-white shades. Bleach-white tooth shades do not occur in nature. Rather, they are a product born of the general public’s desire to have a “Hollywood smile.”

This is a case of perception versus reality. Although the general public may believe that the whitest teeth possible are also the most attractive teeth, dental professionals know that simply making a tooth whiter does not mean it will look better. These teeth are, in-

deed, ultra-white (Fig 2), but they are also opaque, so they do not let light pass through, which makes them appear flat and unnatural. In ceramic science, increasing the brightness is the only way to make the laminate material whiter. The negative consequence of ultra-white restorative shades, however, is that they increase the opacity of the tooth to the point where translucency is virtually eliminated.

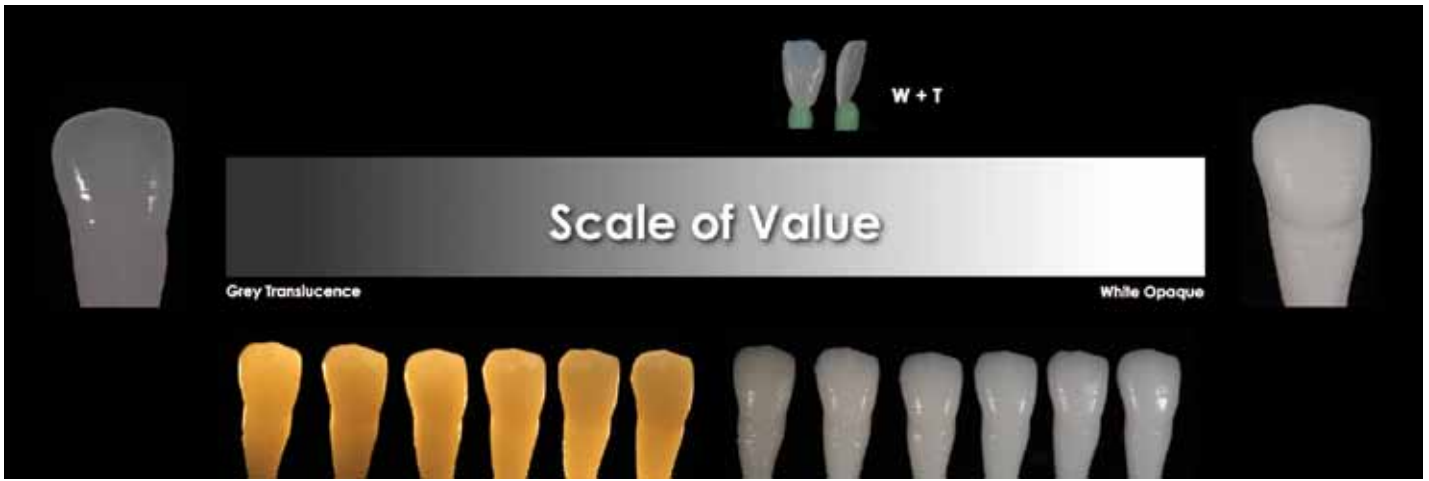#### **The Need for Measuring Enamel Translucency Shades**

The goal is to achieve translucency levels with PLVs that are as close to matching natural tooth enamel as possible.<sup>8</sup> The problem, however, is that the whiter we attempt to make the restoration, the

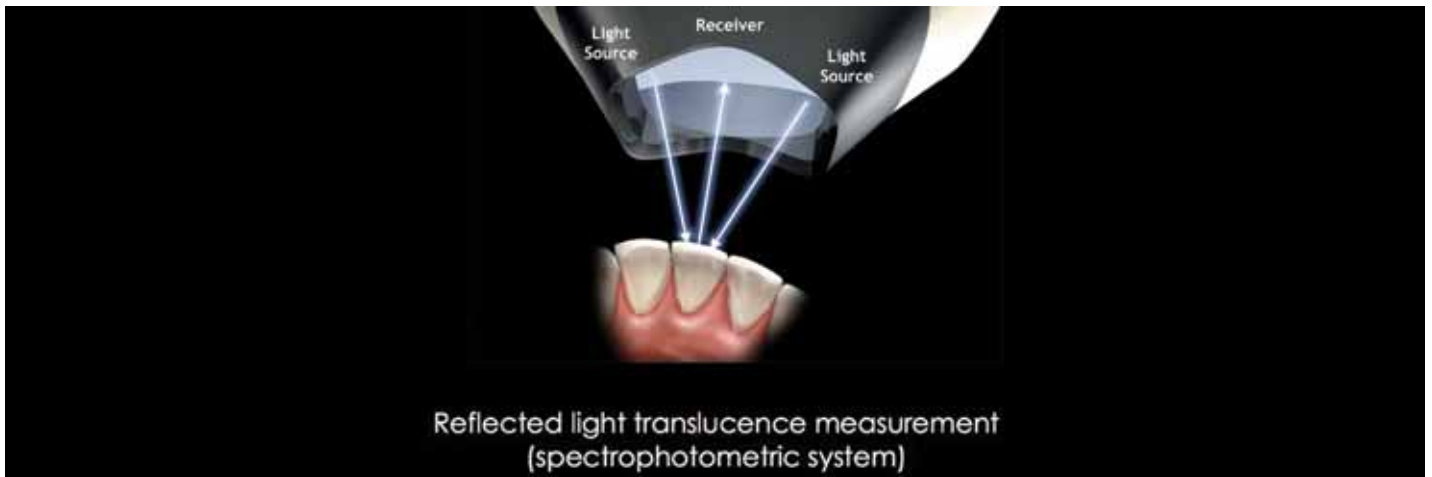
more difficult it becomes to maintain natural translucency and light transmission (Fig 3).

#### **Achieving Bleached Veneers Within Natural Translucency Levels**

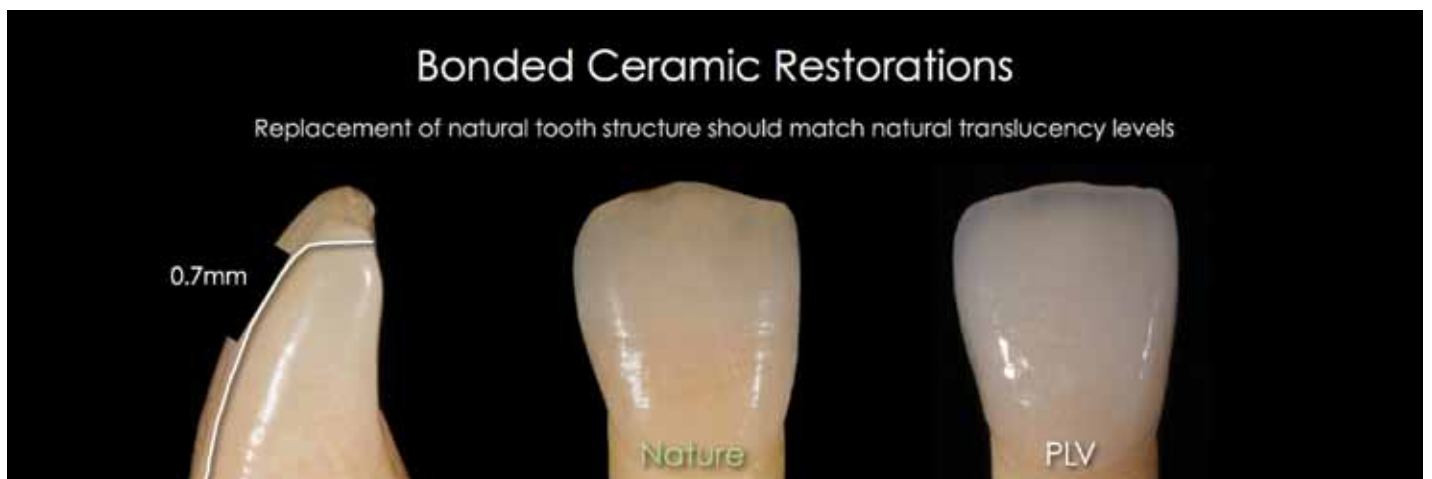Hand-held spectrophotometric light systems are often used in dentistry for shade matching (Fig 4).<sup>9-13</sup> They work by shining a calibrated, consistent light source at the tooth and then measuring the quality of light reflected back into the device. This type of imaging provides the correct hue and chroma of the teeth, but not the value. Without knowing the value, it is quite possible to have many different teeth that are, for example, shade A3 at the gingival third, C2 in the middle, and C1 at the



**Figure 3:** The whiter the restoration, the more difficult it becomes to maintain natural translucency and light transmission.



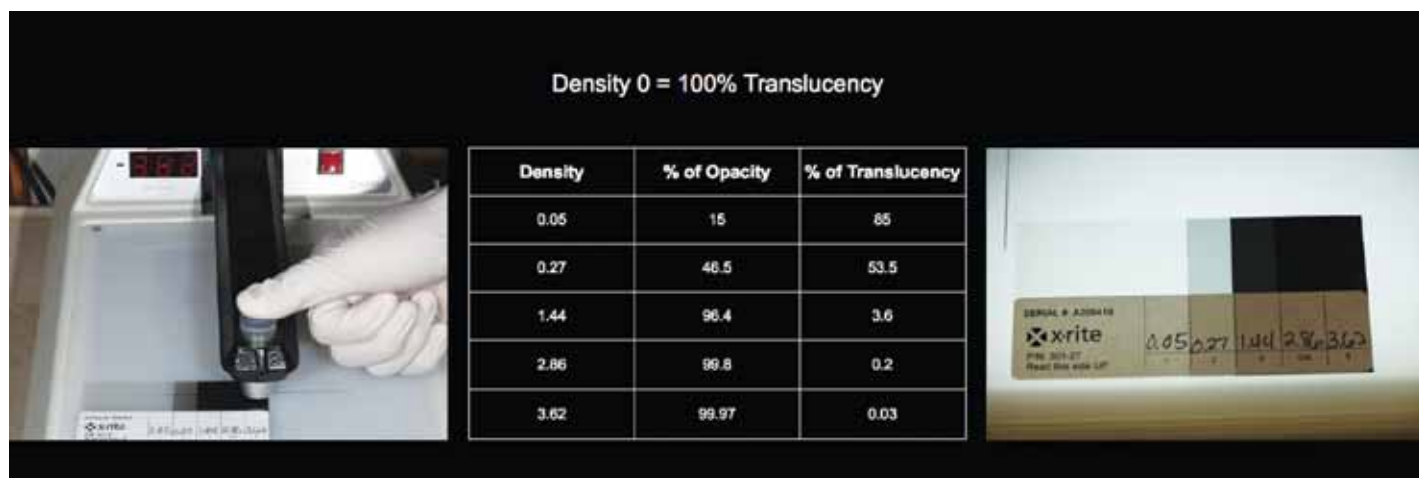
**Figure 4:** Hand-held spectrophotometric light systems are often used in dentistry for shade matching. (From *Fundamentals of Color: Shade Matching and Communication in Esthetic Dentistry* [chapter 1, Color Theory, p. 64], by Stephen J. Chu, Alessandro Devigus, and Adam Mielezsko.)



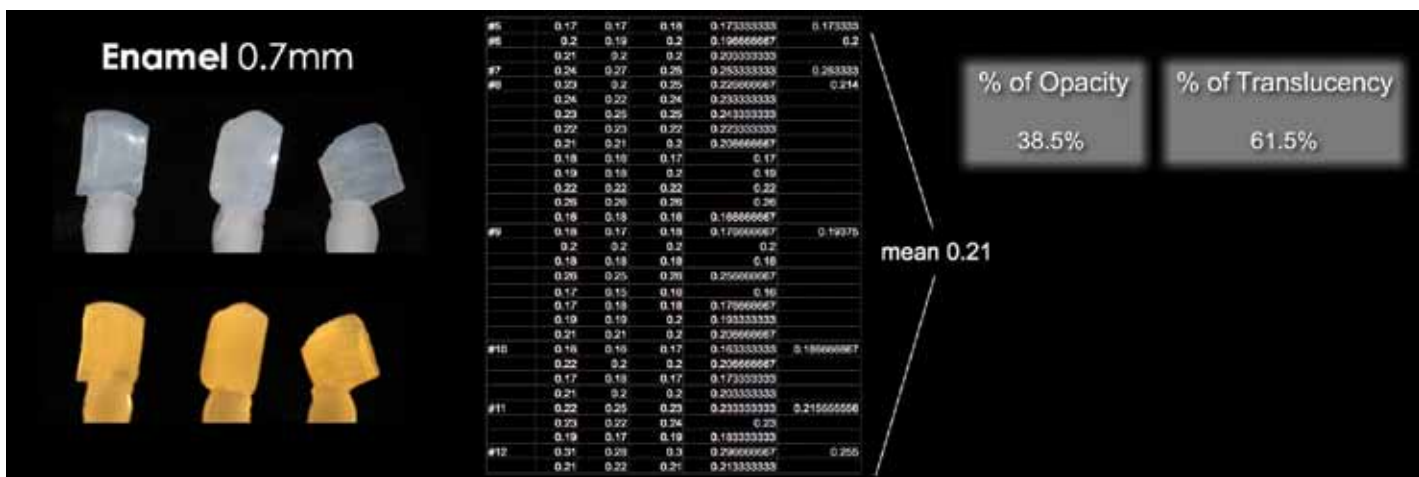
**Figure 5:** The ceramist's ultimate goal is to produce a bonded porcelain laminate veneer with translucency and opacity as close to natural levels as possible.



**Figure 6:** The enamel from 28 natural teeth was carefully removed into slices, each with a thickness of 0.7 mm, to replicate the size and thickness of a porcelain laminate veneer.



**Figure 7:** The density, opacity, and translucency of the natural enamel slices were measured with a professional-grade densitometer.



**Figure 8:** The average opacity reading for the entire sample of natural enamel slices was 38.5%, and the average percentage, or degree, of translucency was 61.5%.



“Ceramists should consider using a densitometer test... to determine the actual opacity and translucency of their own materials.”

Type of Material	% of Opacity	% of Translucency	% of Translucency Difference Compared with Natural Enamel
Bleach (three samples)	51%	49%	21%
Lithium Disilicate (low tran: 7 samples)	49.9%	50.1%	20%
Lithium Disilicate (high tran: 8 samples)	47.5%	52.5%	15%
Nature (natural enamel)	38.5%	61.5%	0% (baseline)
Custom Ceramic Blend	41%	59%	5%

Table 1. Translucency Comparison of Ceramic and Natural Enamel.

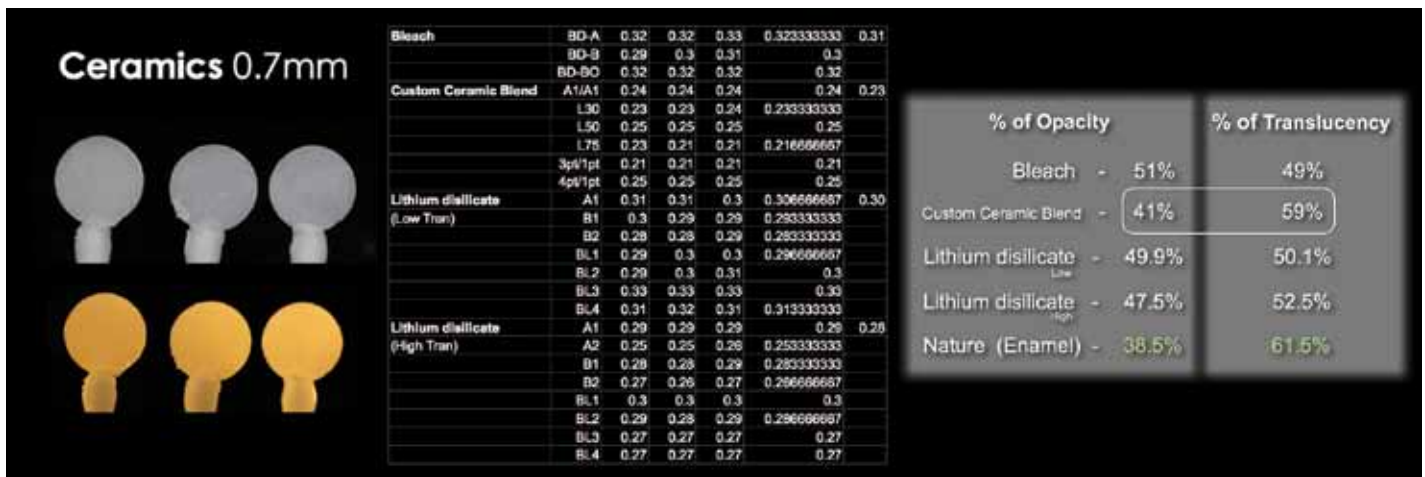

Figure 9: The off-the-shelf ceramics were up to 21% less translucent compared to that of natural enamel, whereas the author’s customized blend was much closer to natural enamel, with a difference of only 5%.

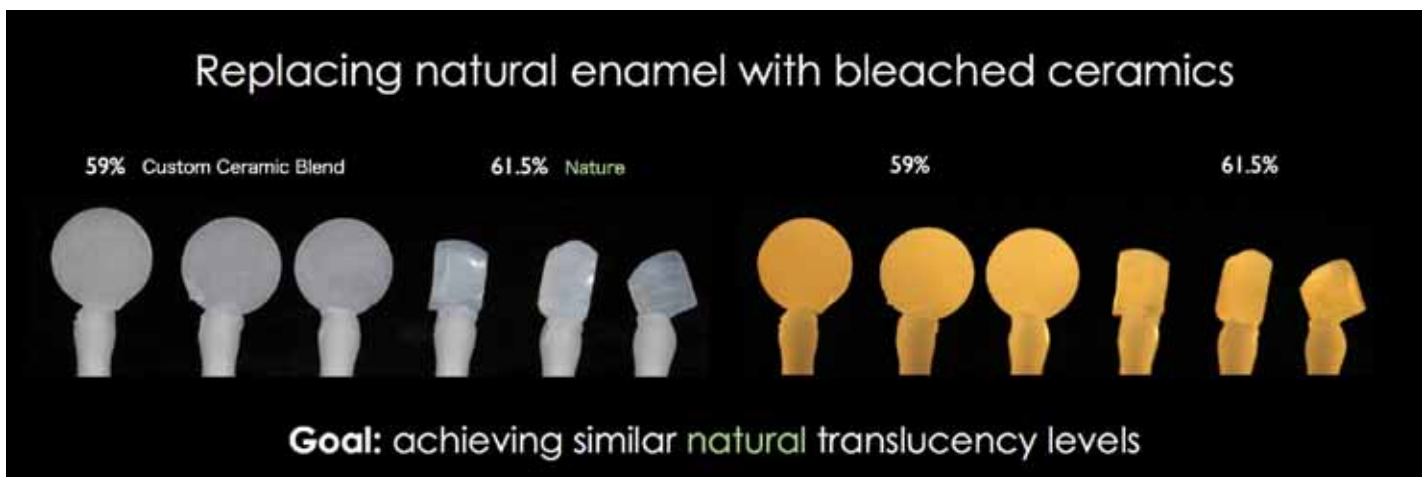
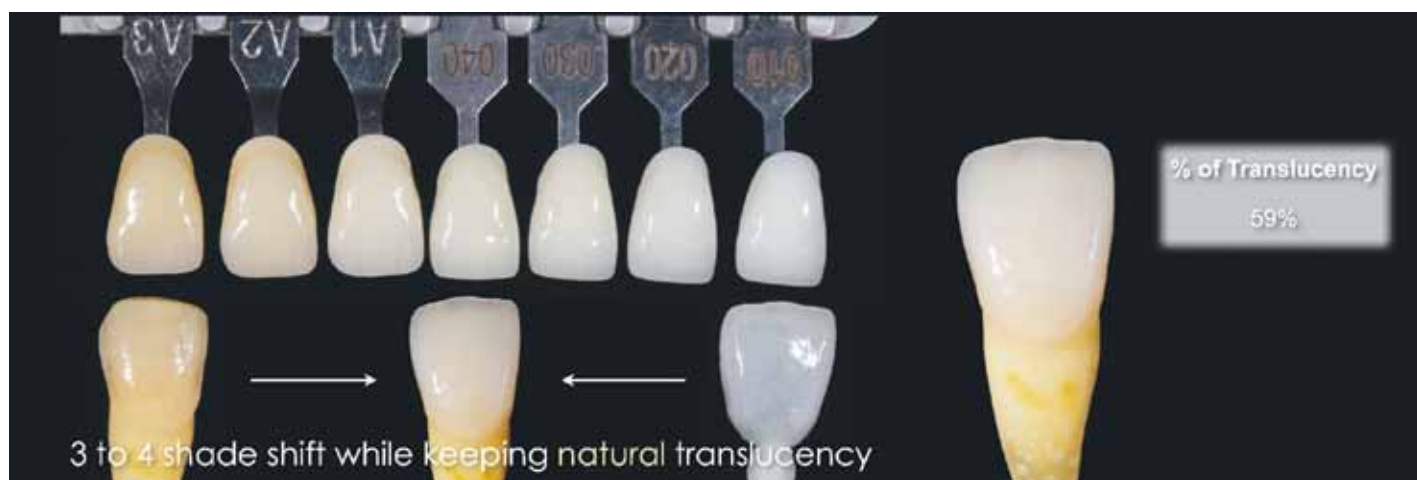
Figure 10: When replacing natural enamel with bleached ceramics, the goal is to achieve translucency levels as close to natural enamel as possible.



**Figure 11:** Customized ceramic blends are capable of producing the most natural-looking bonded veneers, even in shifts of up to three or four shades, without compromising translucency and minimizing the tendency toward increased opacity—especially when working in the esthetically challenging bleach-white range.

incisal edge; however, when placed side by side, they all look slightly different.<sup>14</sup> This is because the value of the shades can vary significantly, even though the shades themselves remain constant.

## Replacing Natural Enamel With Bleached Ceramics

The ceramist's ultimate goal is to produce a bonded white ceramic restoration with translucency and opacity as close to natural levels as possible (Fig 5). This is especially difficult when replacing natural enamel with bleached ceramics. Not totally satisfied with results produced from off-the-shelf ceramics, the author conducted a test to create a range of proprietary ceramic blends that most closely matched the translucency and opacity of natural enamel.

First, 28 natural extracted teeth samples were collected, including incisors, canines, and bicuspids. All teeth were intact and unrestored, with no defects. The enamel from each tooth was carefully removed into slices, each with a thickness of 0.7 mm (Fig 6).

Next, each 0.7 mm slice of natural enamel was measured using a professional-grade densitometer (Fig 7). The density of the enamel varied between

a low of 0.17 to a high of 0.26, with a mean of 0.21. The average opacity reading for the entire sample of natural enamel slices was 38.5%, and the average percentage, or degree, of translucency was 61.5% (Fig 8).

Once the average opacity and translucency of natural enamel was known, the next step was to test the opacity and translucency of a variety of ceramics from various material manufacturers (Fig 9).

Surprisingly, the percentage of opacity among all of the off-the-shelf materials tested was 23% to 30% higher than natural enamel (Table 1). This degree of deviation could have an effect on the appearance of the restoration and may lead to imparting a flat, dull, lifeless look. As we know, the greater the opacity, the less realistic the restoration will look.

Armed with this scientific knowledge, we should create our own proprietary ceramic blends to produce a ceramic material with opacity and translucency as close to natural enamel as possible. The results of the testing conducted for this article were 41% opacity (38.5% for natural enamel) and 59% translucency (61.5% for natural enamel), which fared significantly better than all of

the other off-the-shelf ceramics tested (Fig 10).

## Conclusion

To produce the most natural-looking porcelain laminate veneer restorations—specifically those in the increasingly popular bleach-white range—it was first necessary to conduct a controlled, scientific study of the translucency and opacity values of natural enamel as well as a selection of readily available ceramic materials (Fig 10). Once the translucency and opacity values of natural enamel were determined using scientific densitometer testing, a comparison of the results using the same test method on existing ceramic systems indicated that they needed to be modified to more closely match translucency and opacity values of natural tooth enamel.

Ceramists should consider using a densitometer test as described in this article to determine the actual opacity and translucency of their own materials. The results should be compared to natural enamel to determine how closely their materials match the opacity (38.5%) and translucency (61.5%) of natural enamel. With these numbers, ceramists can further refine their own porcelain formulations and retest un-

til the results are as close as possible to matching natural enamel.

Utilizing this “test and refine” method, shifts of up to three to four shade changes can be achieved without compromising translucency and minimizing the tendency toward increased opacity, especially when working in the esthetically challenging bleach-white range. The custom material blends developed and described in this article have been used in natural dentition samples with great success (Fig 11), which suggests that when applied to existing feldspathic ceramic material systems, similar results should be realized.

### Acknowledgments

*The author offers sincere gratitude to Stephen J. Chu, DMD, for mentoring and encouraging him to write this article; and to Adam Mielezsko, CDT, and Julian Kim, CDT, for their assistance.*

### References

1. Reshad M, Cascione D, Kim T. Anterior provisional restorations used to determine form, function, and esthetics for complex restorative situations using all-ceramic restorative systems. *J Esthet Restor Dent.* 2010;22(1):7-16.
2. Weston JF, Haupt E. Creating aesthetic success through proper clinical and laboratory technical communication. *Dent Clin North Am.* 2011;55(2):371-82.
3. Baratieri LN, Araujo E, Monteiro S Jr. Color in natural teeth and direct resin composite restorations: essential aspects. *Eur J Esthet Dent.* 2007;2(2):172-86.
4. Vanini L. Light and color in anterior composite restorations. *Pract Periodontics Aesthet Dent.* 1996;8(7):673-82; quiz 684.
5. Chu SJ, Devigus A, Mielezsko AJ. Fundamentals of color: shade matching and communication in esthetic dentistry. Hanover Park (IL): Quintessence Pub.; 2004. p. 77-97.
6. Gürel G. The science and art of porcelain laminate veneers. Hanover Park (IL): Quintessence Pub.; 2003. p. 182-5.
7. Munsell AH. A color notation. New York: Munsell Color Co.; 1919.
8. Villarroel M, Fahl N, De Sousa AM, De Oliveira OB Jr. Direct esthetic restorations based on translucency and opacity of composite resins. *J Esthet Restor Dent.* 2011;23(2):73-87.
9. Hegenbarth EA. Esthetics and shade communication: a practical approach. *Eur J Esthet Dent.* 2006;1(4):340-60.
10. Chu SJ, Trushkowsky RD, Paravina RD. Dental color matching instruments and systems: review of clinical and research aspects. *J Dent.* 2010;38(Suppl 2):e2-16.
11. Yoshida A, Miller L, Da Silva JD, Ishikawa-Nagai S. Spectrophotometric analysis of tooth color reproduction on anterior all-ceramic crowns: part 2. color reproduction and its transfer from in vitro to in vivo. *J Esthet Restor Dent.* 2010;22(1):53-63.
12. Ishikawa-Nagai S, Yoshida A, Da Silva JD, Miller L. Spectrophotometric analysis of tooth color reproduction on anterior all-ceramic crowns: part 1. analysis and interpretation of tooth color. *J Esthet Restor Dent.* 2010;22(1):42-52.
13. Chu SJ, Tarnow DP. Digital shade analysis and verification: a case report and discussion. *Pract Proced Aesthet Dent.* 2001;13(2):129-36; quiz 138.
14. O'Brien WJ, Hemmendinger H, Boenke KM, Linger JB, Groh CL. Color distribution of three regions of extracted human teeth. *Dent Mater.* 1997;13(3):179-85. **jCD**



Mr. Kim is a clinical assistant professor at New York University College of Dentistry. He is also the founder and president of Jason J. Kim Dental Aesthetics in Port Washington, New York, and Oral Design Center in New York City.

Disclosure: The author did not report any disclosures.





Smile Design Directions



## Deliver more smiles to more patients with Dental GPS software

Create personalized smile simulations for your patients within minutes  
Accurately produce quick smile design plans with the exclusive "M Ruler"  
Certified labs wax up your case with utmost precision using your smile design plans



THE **AURUM** GROUP

[www.dentalgps.com](http://www.dentalgps.com)

Call now for information 1 877 GPS-8977 450-663-3588



Contact us for more information on our "New Concept in Aesthetic Dentistry" seminars.



"The level of control and accuracy exceeds any software that I've yet to witness. . . while I avoid superlatives, I was very impressed by what I saw. I consider it to be a groundbreaking tool for the aesthetic dentist."

**Dr. Martin B Goldstein DMD, Wolcott, CT, USA**



"Since I started using Dental GPS my practice has increased by \$20,000 a month. Technical support has been tremendous and Dr. Methot is a born teacher with a deep knowledge in cosmetic dentistry and lab procedure."

**Dr. Ronald Morin DMD, Gatineau, QC, Canada**

# The Benefits of a Multi-layer Technique

Minimally Invasive and Non-Invasive Ceramic Veneers

Joachim A. Maier, MDT

*The advantages of these small ceramic veneer chips have enjoyed a high acceptance rate by patients.*



## Abstract

Minimally invasive procedures are highly desired in dentistry today. Today's advanced adhesive technology and composite systems allow for a wide range of indications. The variety of so-called non- and minimally invasive veneers is discussed. This article presents a traditional production method using platinum foil.

## Introduction

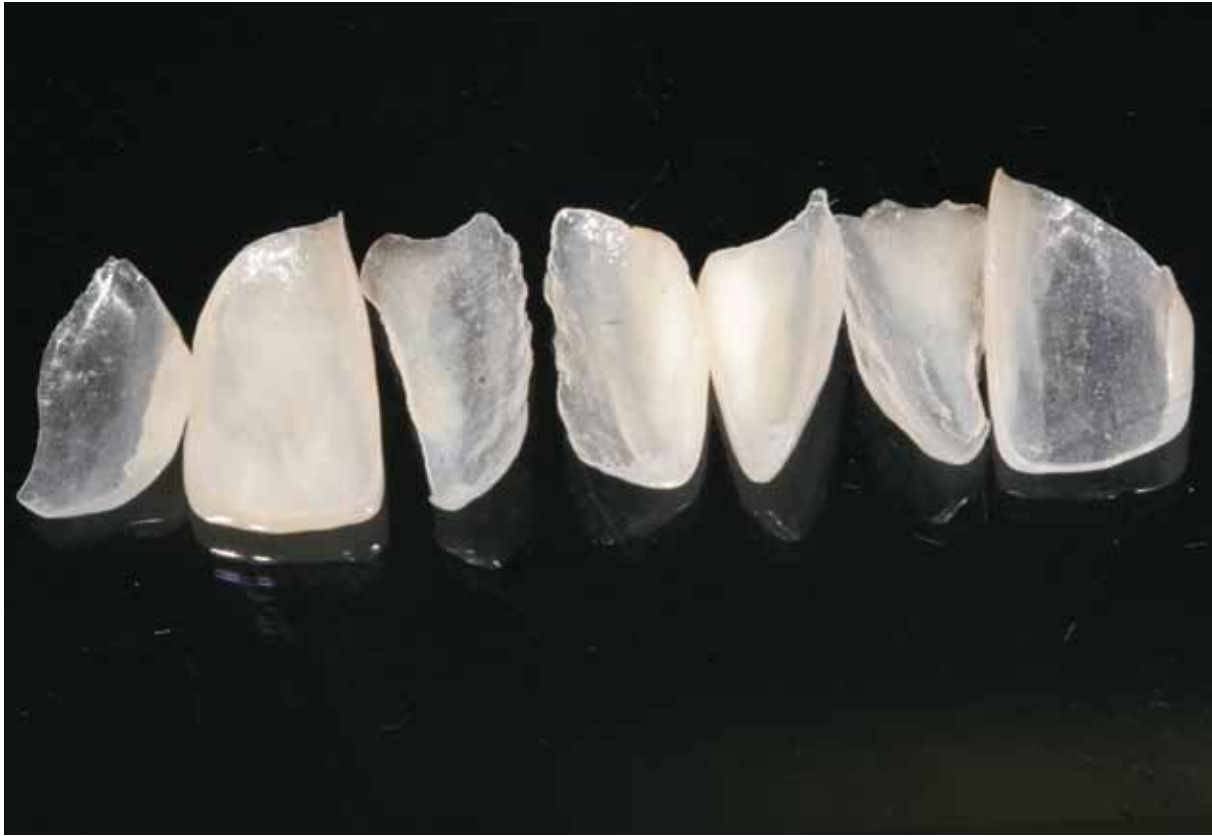"Modern" dentistry is immediately associated today with computer-assisted design/computer-aided manufacturing (CAD/CAM) technology and high-performance ceramics in combination, which are also used in the author's laboratory. These areas are strong growth markets with much potential. However, we can also experience great success with a very traditional product that is produced in a conventional manner.

In the author's laboratory, modern dental technology involves the production of non- and minimally invasive dental restorations, including veneers. The application areas include changes in shape, closing interproximal spaces, widening teeth, incisal extensions, optical compensation of malposition, and changing color in correlation with veneer thickness.

The advantages of these small ceramic veneer chips have enjoyed a high acceptance rate by patients, who appreciate benefits such as little or no loss of tooth structure, usually no grinding, no anesthesia, and not necessarily provisional acrylic veneers.

In the author's laboratory, ceramic veneers for non-invasive and minimally invasive treatment concepts are produced by a very classic method. In the author's opinion, highly esthetic veneers cannot be manufactured with any CAD/CAM method or pressing technique. The layer thicknesses within the veneers vary greatly and, therefore, require different opacities and translucencies (**Fig 1**). Therefore, the author uses, with great success, only the multi-layer technique on platinum foil or refractory dies. The special filling of these veneers makes a perceptible difference.





**Figure 1:** Minimally invasive veneers require light management in different material thicknesses.

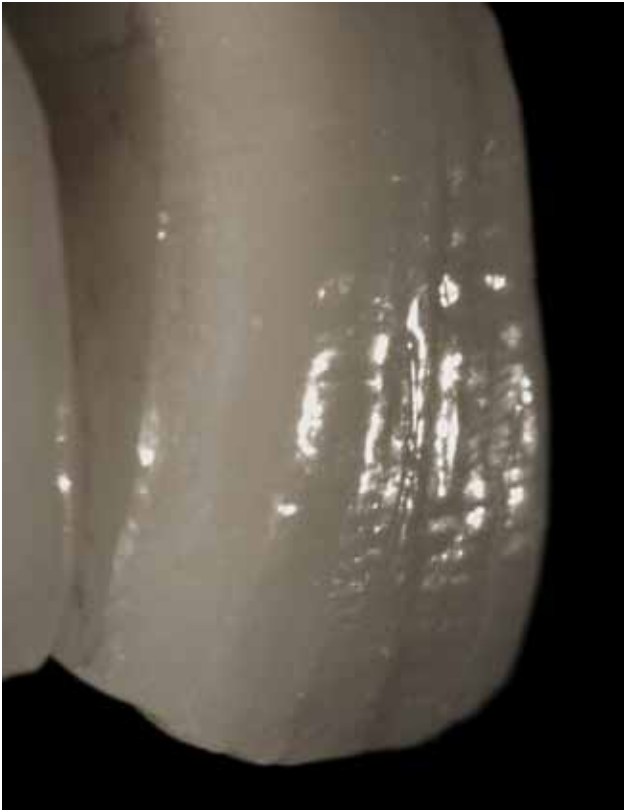
## Long-Term Success of Minimally Invasive and Non-Invasive Ceramic Veneers

Traditional veneers have proven in studies to yield long-term success.<sup>1,2</sup> Veneers, particularly the delicate no-preparation veneers used before adhesive cementation, are extremely sensitive. They acquire their ultimate strength of the frictional connection with the tooth structure via the adhesive bonding process. The reliable adhesive bond to tooth structure for long-term clinical success is a key factor. The development of the adhesive bonding process makes no-preparation veneers possible. Following the correct protocol of adhesive cementation, excellent durability and stability are expected.

Non- and minimally invasive veneers are mainly cemented on unprepared or near-the-surface enamel. An adhesive system is recommended using the proven total-etch technique of generations four and five.<sup>1</sup>

Enamel near the surface is very etch-resistant, due to the relatively low solubility of fluorapatite. In this critical area, total-etch products also allow sufficient bond strength with prolonged etching. They have proven adhesion to dentin, ground enamel, and unground enamel with high shear strength, micro-tensile bond strength, and marginal quality.<sup>1-4</sup>

*A veneer is unobtrusive when its light dynamics resemble those of the specific natural tooth.*



**Figure 2:** Surface reflection enhances perceptible brightness.

Peumans and colleagues conducted a study examining the long-term stability of ceramic veneers. Within a 10-year observation period, 4% of the restorations had to be exchanged. Another 32% were deemed “clinically unacceptable” after 10 years, but could be repaired.<sup>5</sup>

Even with various forms of preparation for traditional veneers, long-term success can be determined. The different anatomical characteristics of natural teeth, which should be served with non-invasive or minimally invasive veneers, could, therefore, be as successful.

Other studies of conventional veneers have examined the effects of the preparation method based on the shape of the to-be-supplied teeth. Guess and Stappert found a success rate of approximately 98% for “overlap veneers” and 100% for “full veneers” over a five-year observation period. When considering infrafractures—fractures within the veneers that have not resulted in an absolute failure—the relative survival rate of conventional veneers stands at 85%.<sup>6</sup>

Regarding preparation shape for veneers, Castelnovo compared pure facet preparation with reduction of the incisal edge with and without a chamfer. The fracture resistance of the observed veneers combined only with the pure reduction

of the tooth in the multi-faceted preparation is comparable to the strength of a natural tooth.<sup>7</sup> Stappert, however, could find no difference in his investigations of the three types of preparation compared to the natural tooth.<sup>8</sup>

It can be assumed that non-invasive veneers are as successful as prepared veneers. Strassler and colleagues observed the high stability of non- or minimally invasive veneers in a long-term clinical study that evaluated 167 veneers. However, these were pressed veneers.<sup>9</sup>

Long-term durability of layered, non-invasive veneers requires further investi-

gation, as there are only a few known studies on this topic. Additional veneers using a multi-color build-up technique represent a highly esthetic restoration for the clinician.

## Planning and Esthetic Analysis

At the beginning of each veneer treatment, accurate therapy planning is required, including an analysis of causes of severe abrasions or discolorations. It must be clarified whether orthodontic pre-treatment is necessary. In some cases of vertical height loss, the dentist raises the vertical dimension before the beginning of the veneer treatment. It makes sense to integrate the dental technician into the planning process from the beginning.

As part of the esthetic analysis, the distribution of various color shades and the light flux of the different tooth areas in the restored area will be established. The age-appropriate development of the restorations with corresponding individual characteristics and conformal surface texture will be determined and set. An optimal tooth position and veneer shape will be sought. The correct tooth color analysis presented here with the “additional veneers” has a high priority, and only parts of a tooth will be reconstructed. Variations in brightness are noticeable. The complexity of the color determination is evident when we look at the main influencing factors that create the conscious perception of color. The nature of the light sources, color environment (e.g., clothing, furniture, and walls), and receptivity of our eyes influence the outcome we see.

## The Perceived Color of a Tooth

A tooth shade is created by the impact of light on the tooth surface and reflection or absorption within the tooth. There are some scattered portions—one portion of the spectrum is absorbed and the other is reflected. The perceived tooth color is caused by the light optical effects of its components, such as the crystalline form of dentin and enamel. The tooth surface reflects a portion of the light off the surface texture and the angle of incidental light. The remaining fraction penetrates into the tooth and is refracted or scattered in the prisms of the dentin and enamel crystals. The size and structure of the crystals determine the color scheme.

The fine crystalline melt and high transparency produced are due to the high, non-reflected light component, revealing a grayish tone. The prismatic, reflective depth in the dentin is a saturated color. The knowledge of the light response of the natural tooth structure aids in the analytical evaluation and reproduction of tooth color. For example, determining the shade of a young patient's teeth is challenging. The strong surface reflection enhances the perceptible value. Only different angulations of view show the real value of brightness inside (Fig 2).

### Color Perception and Definition

Brightness is the dominant factor in the color selection and will always be determined first (Fig 3), followed by color saturation and hue. The tooth patterns also require a sophisticated color analysis.

When determining shades, the author uses the Color Guide Vitapan 3D Master System (Vita Zahnfabrik H. Rauter GmbH & Co KG; Bad Säckingen, Germany), which groups five distinctly different brightness layers. The distances between the teeth samples are spaced exactly the same. Therefore, tooth shades in the intermediate layers are easily communicable by dentists and reproducible by the laboratory. Even the arrangements of the tooth patterns within the respective layers have uniform brightness distances in terms of saturation and hue. With this logic, the number of the required patterns can be reduced to 26 teeth. This color system helps to easily structure complex colors. The teeth are divided into different zones and analyzed. Strictly speaking, there are merely three decisions to make: value/brightness, saturation/chroma, and hue.

### Light Dynamics Within Veneers

A veneer is unobtrusive when its light dynamics resemble those of the specific natural tooth. Light dynamics are influenced by the material's light

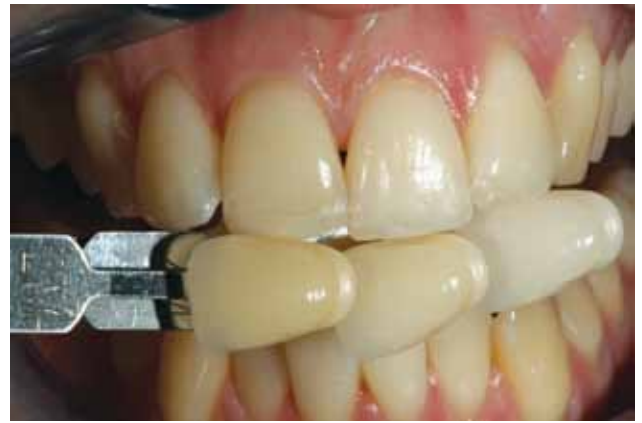

Figure 3: Color determination by Vita 3D-Master Shade Guide.



Figure 4: Adapting the platinum foil.



Figure 5: Hard metal tools visible on the tooth's fine surface structure.



scattering index and thickness and the combination of several layers with different translucencies and opacities. Light must be on the inside of the veneer for a certain thickness to be reflected, which allows light to pass through the veneer and into the absorbing oral cavity. The brightness value is greatly reduced at this point. This is desirable in some areas of the tooth's incisal, middle, and apical thirds, but is rather less frequently the target. Specifically, a reflective ceramic mass inside the veneer is placed to stabilize the brightness value of the ceramic. This simple principle of layer technology is the basis for most tasks. The author's laboratory uses Creation Classic Ceramics (Creation Willi Geller International GmbH; Meiningen, Austria) with great success.<sup>10</sup>

### Platinum Foil Manufacturing Technique

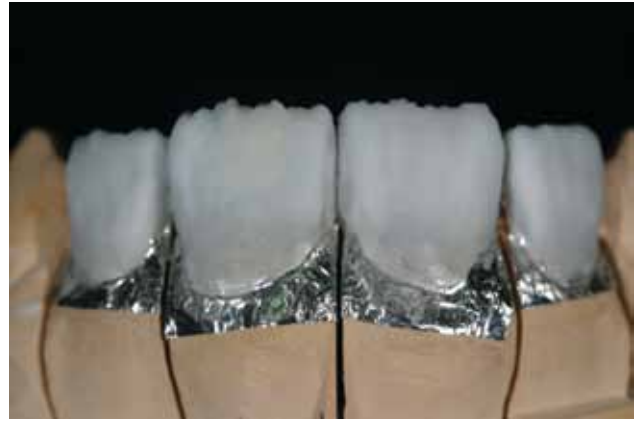
There are two different carrier materials used in the production of ceramic veneers: the investment stump and platinum foil. The latter has been used as carrier material for porcelain veneers for many years. This production method involves a series of steps. First, to gain access to the marginal border area of the veneers, any plaster model disturbing proportions of the soft tissue is removed. The bearing surface of the platinum foil must be free of undercuts. Removing a stump is otherwise impossible, as they are made of hardened plaster. Platinum foil is cut and applied with the thumb, and the proximal areas are folded first to the palatal edge (Fig 4) and then to the incisal edge.

The adaptation is first done with the finger, always moving from the center or the incisal edge to the outside, painted, and adapted to the surface. Soft rosewood has been proven not to damage the platinum surface. The final adaptation is done with a metal tool, which brings the fine structures on the tooth surface to light (Fig 5). The incisal edges bring the double or triple platinum foil within the targeted areas. This area should be outside the veneer. Different thin, multi-color ceramic layerings with up to seven firings are applied (Fig 6). After the firings (Fig 7), the platinum foil is pulled off (Fig 8).

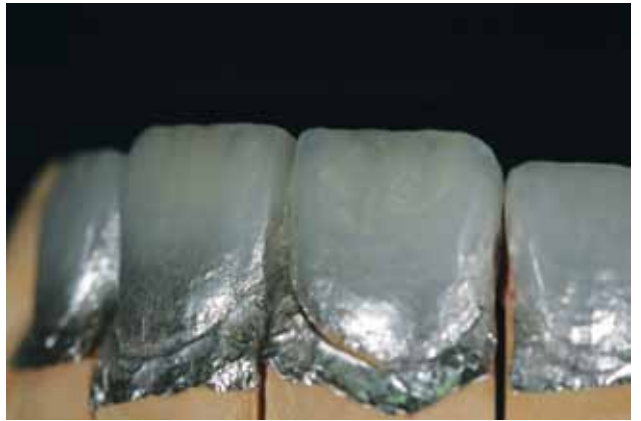### Examples of Indications

#### Incisal Extension

Teeth become heavily abraded for a reason, which must be determined and fixed before the veneers are treated. A general increase in vertical relation is usually carried out before or with the extension of the front teeth. The multi-layer technique makes it possible to hide the incisal edge by using opaque ceramic only



**Figure 6:** Several thin, multi-color ceramic layerings and firings imitate natural intrinsic characteristics.



**Figure 7:** The platinum foil is ready to be removed.



**Figure 8:** Pulling out the platinum foil.

## *A multi-layer technique allows natural intrinsic and extrinsic light effects and creates natural-looking veneer restorations.*

minimally deep inside this difficult area. It is not necessary to press opaque veneers in this situation; it is only required to make the incisal edge invisible. The veneers must be protected from overuse. Hence, it is appropriate to use a synthetic splint at night (Figs 9-11c).

### **Closing Interproximal Spaces and Widening Teeth**

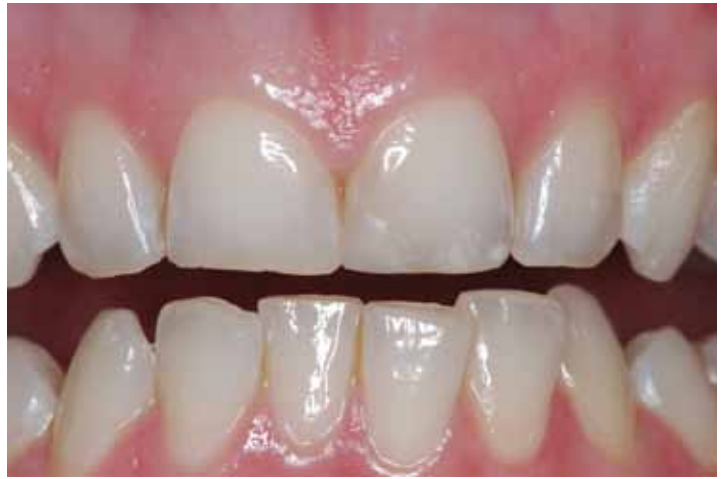Usually, the interproximal natural tooth shape allows a path of insertion for the veneers. The challenge lies in the various thicknesses of veneers. Different scattering characteristics within the ceramic shell are necessary. On the other hand, very thin edge leaking areas are a challenge during production and placement in the mouth. However, there is no other known veneer technique that is as nearly invisible (Figs 12-15).

### **Compensation for Malposition**

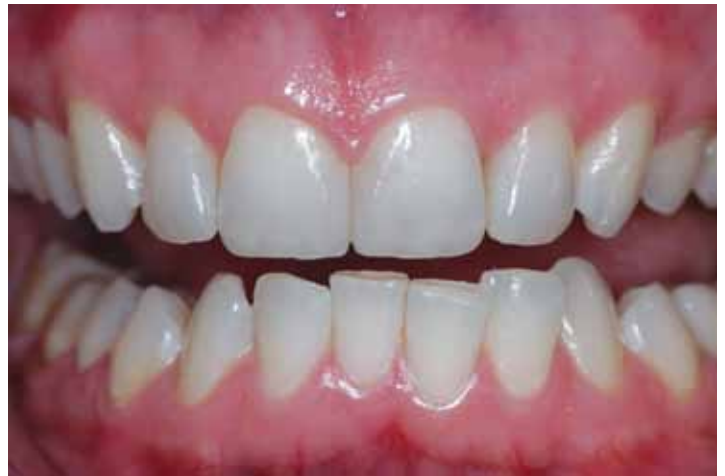Some of the most challenging veneer restorations involve retruded or rotated teeth that should be returned to their origin position in harmony with the dental arch. This case study shows that non-invasive concepts are, in some instances, only a compromise solution to produce a maximum natural shape. For example, if a patient asks for a non-invasive optical improvement of teeth #7-10, the filling mesial on teeth #8 and #9 will be reduced, but no more tooth structure is removed. Unfortunately, the anomaly of the position leads one to believe that an optimal tooth shape cannot be achieved. However, considering the preservation of healthy natural tooth structure using this non-invasive treatment, the esthetic improvement is satisfactory. Nevertheless, the multi-layer technique achieves a result that is hard to perceive (Figs 16 & 17).

### **Repair After Fracture**

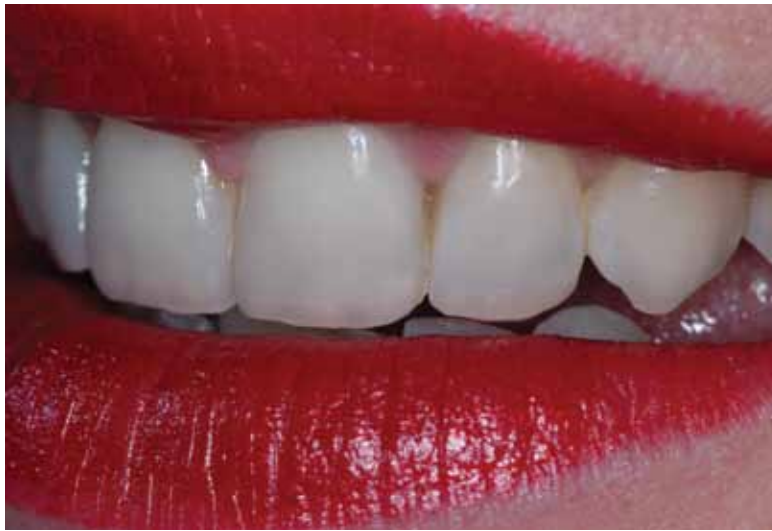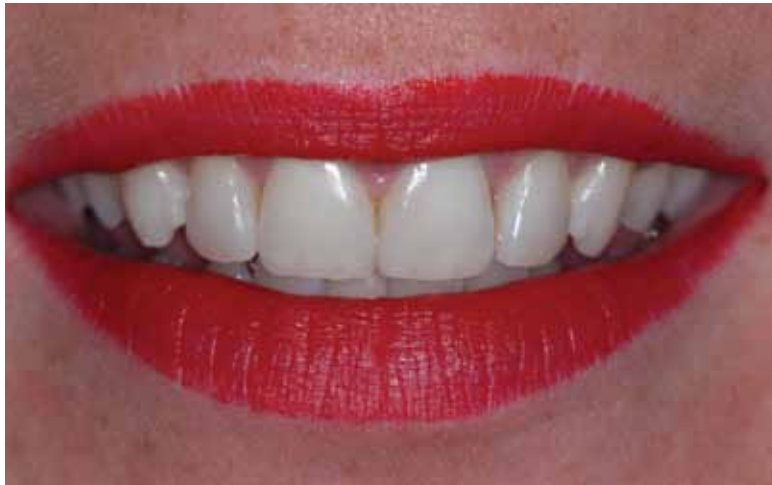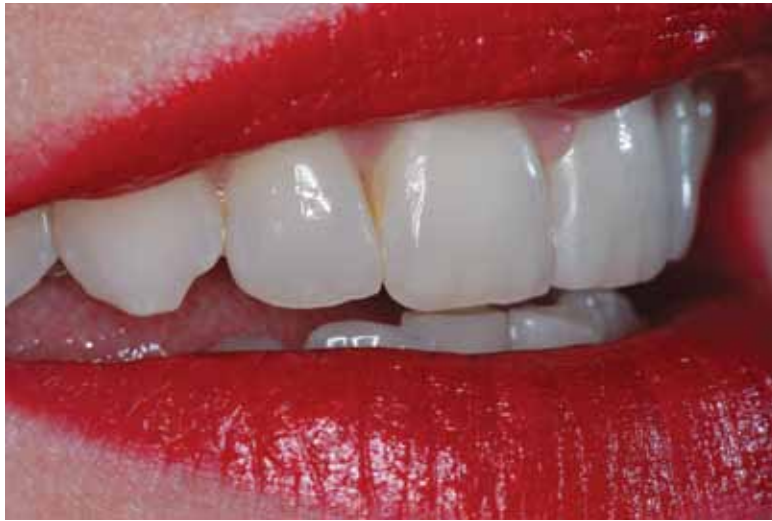In the case shown here, the patient wanted a visual improvement of #8 and #9. Tooth #8 had an old composite filling on the mesio-incisal edge (Figs 18a & 18b), which will be removed before the impression. There will be two purely enamel-anchored veneers fixed, which will be adapted through the light conduction of the adjacent multi-layered ceramic structure. This intrinsic natural optical effect would not be possible with the pressed ceramic technique (Figs 19 & 20).



**Figure 9:** The abraded dentition of a young patient.



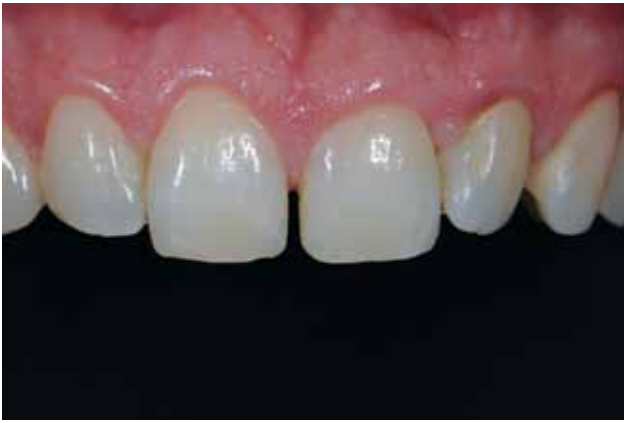**Figure 10:** The four anterior veneers are difficult to perceive.



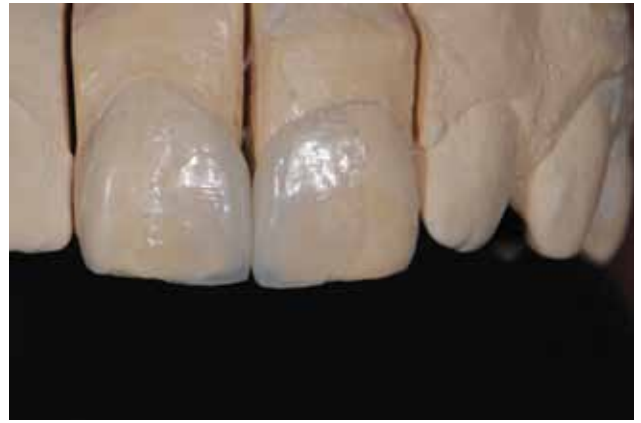**Figures 11a-11c:** A natural, beautiful smile enhanced by non-invasive veneers.

*The examples presented in this article show a small section of the diverse sectors of non-invasive and minimally invasive veneers.*

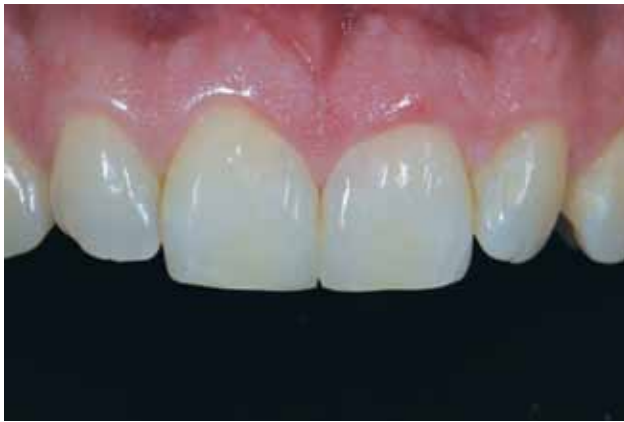



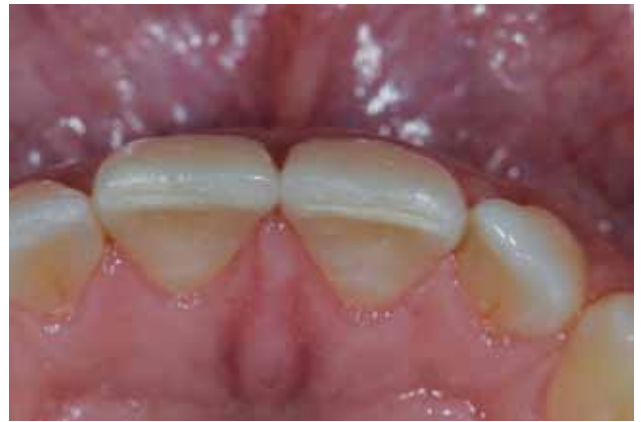**Figure 12:** Diastema between the central incisors.



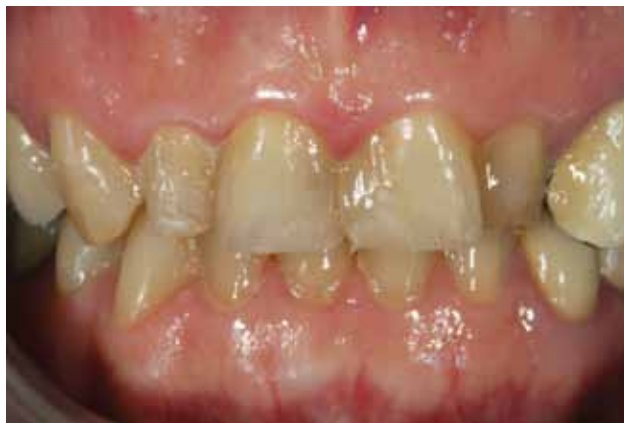**Figure 13:** Both veneers are overextended incisally to improve retention while placing on the teeth to simplify cementation.



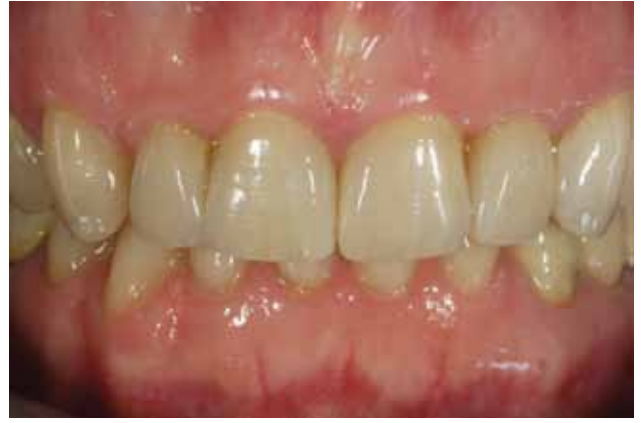**Figure 14:** Following cementation, the incisal over-extension is polished.



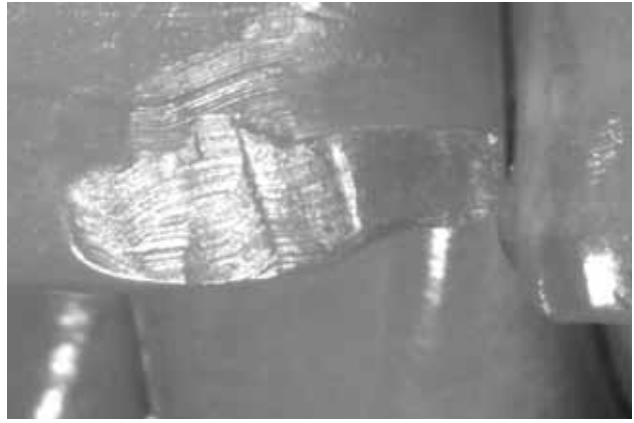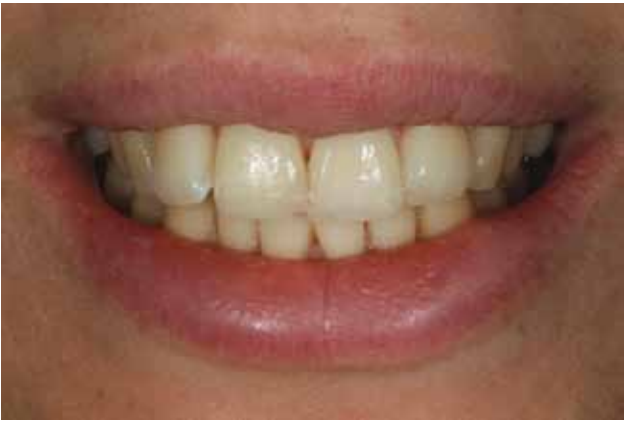**Figure 15:** The interproximal space is closed without creating unhygienic areas.



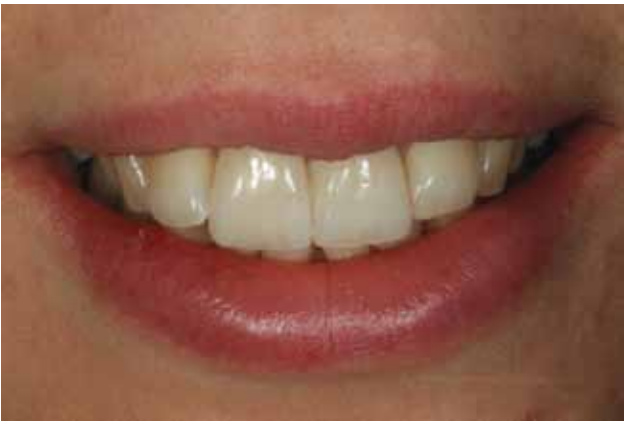**Figure 16:** Non-invasive optical improvement was requested by the patient on ##6-10.



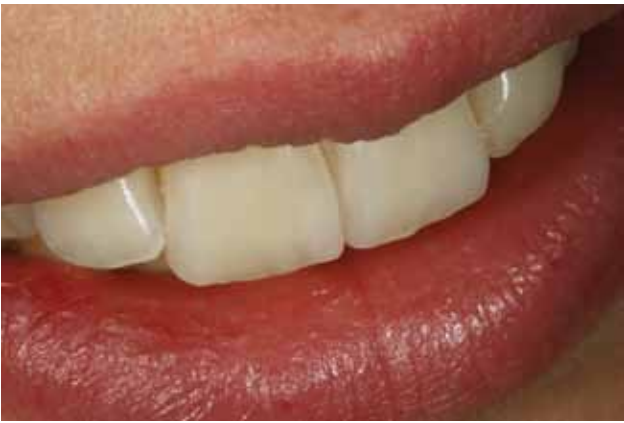**Figure 17:** Non-invasive veneers are placed on ##6-10 in different thicknesses, and #11 is capped with a zirconium crown.



**Figures 18a & 18b:** An old composite filling on #8 is replaced and disharmonic placement of #8 and #9 is improved by veneers.



**Figure 19:** Minimally invasive grinding at the incisal edge of #8 was used to remove an old composite filling and flatten sharp enamel edges.



**Figure 20:** A minimally invasive veneer was placed on #8 and a non-invasive veneer was placed on #9.

## Did you know...

- The multi-layering technique in combination with platinum foil technique allows for veneers as thin as 0.3 mm.
- Different areas of transparency or areas of increased opacity can be presented in nuances; this allows us to produce veneers that are virtually imperceptible.

## Try In

A review of the contact points should always be done with a pair of adjacent veneers, and color can be best controlled with a clear glycerin gel. Highly esthetic veneers integrate the color of natural teeth precisely. For discolored teeth, a corresponding layer ceramic technology should be used; this provides brightening benefits. Optimizing use with a colored composite is rarely necessary.

The stability of the veneers stands or falls with the method of adhesive cementation. As recommended by the manufacturer, the product-specific processing requires a disciplined approach to achieve long-term success.

## Conclusion

The examples presented in this article show a small sample of the diverse sectors of non-invasive and minimally invasive veneers. The advances in adhesive technology allow for this method of treatment.

The correct processing of adhesive systems by the dentist is one key to the success of this appealing treatment technology. The other key is the precise control of light in the veneer ceramic. A multi-layer technique allows natural intrinsic and extrinsic light effects and creates natural-looking veneer restorations. Additionally, this technique has a high acceptance rate among patients.

More clinical studies demonstrating the long-term stability of non-invasive or minimally invasive veneers using this multi-layer technique are necessary. The author's experience using this technique over the last eight years has been overwhelmingly positive (it is important to note that a collaborative effort involving patients, dentists, and dental technicians was required for this success).

## References

1. Clyde JS, Gilmore A. Porcelain veneers: a preliminary review. *Br Dent J.* 1988;164(1):9-14.
2. Barnes DM, Blan LW, Gingell JC, Latta MA. Clinical evaluation of castable ceramic veneers. *J Esthet Dent.* 1992;4:21-6.
3. Pashley DH, Tay FR. Aggressiveness of contemporary self-etching adhesives. part II: etching on unground enamel. *Dent Mater.* 2001;17(5):430-44.
4. Tyas MJ, Burrow MF. Adhesive restorative materials: a review. *Aust Dent J.* 2004;49(3):112-21; quiz 154.
5. Peumans M, De Munck J, Fieuws S, Lambrechts P, Vanherle G, Van Meerbeek B. A prospective 10-year clinical trial of porcelain veneers. *J Adhes Dent.* 2004;6(1):65-76.
6. Guess PC, Stappert CF. Midterm results of a 5-year prospective clinical investigation of extended ceramic veneers. *Dent Mater.* 2008;24(6):804-13.
7. Castelnuovo J, Tjan AH, Phillips K, Nicholls JJ, Kois JC. Fracture load and mode of failure of ceramic veneers with different preparations. *J Prosthet Dent.* 2000;83:171-80.
8. Stappert CF, Ozden U, Gerds T, Strub JR. Longevity and failure load of ceramic veneers with different preparation designs after exposure to masticatory simulation. *J Prosthet Dent.* 2005;94:132-9.
9. Strassler HE, Weiner S. Long-term clinical evaluation of etched porcelain veneers. *J Dent Res.* 2001;80(Spec. Iss.):60.
10. Creation Willi Geller International GMBH. Creation Willi Geller: simply brilliant. Available from: "[http://www.creation-willigeller.com/content.php?page\\_id=1&language=1](http://www.creation-willigeller.com/content.php?page_id=1&language=1)".

**jCD**

## Acknowledgment

*The success of the cases presented in this article was largely determined by close cooperation with the author's dentist partners. The author thanks Dr. Stavros Pelekanos (Athens, Greece), Dr. Jörn van Heek, (Bochum, Germany), and Dr. Ingrid Weimann (Tuttlingen, Germany).*

Mr. Maier lectures internationally and owns Oral Design Center in Überlingen, Germany.

Disclosure: The author did not report any disclosures.





# PREMIER WEB MARKETING & DESIGN for Dentists

## MEMBER Spotlight

Name: *Arnold Tyrangel, DDS*

Practice Location: *Long Island, New York  
(offices in Great Neck and Hicksville)*

Website: *www.greatneckdentalassociates.com*

RM Client Since: *2008*

Advice on Shopping for a Web Company: *My expertise is in dentistry, not websites and marketing, so partnering with Rosemont Media has been beneficial. They keep our practice on the cutting edge of the Internet and help to streamline our budget.*

Favorite Activity Outside of Dentistry: *Golf - If my three girls aren't keeping me busy, the course is where you'll find me.*



Design • Promote • Consult

28th Annual AACD Scientific Session

May 2 - 5, 2012 | Washington, D.C. | *Find us at booth #800*

 American Academy  
of Cosmetic Dentistry  
CORPORATE MEMBER

**ROSEMONT MEDIA**  
A MODERN AD AGENCY

Call Today:  
**800.491.8623**  
www.rosemontmedia.com

# Web Marketing BUYER'S GUIDE

## *Top considerations and questions before your purchase*

by Keith Humes, CEO Rosemont Media

With countless opportunities available to market your practice on the Internet, finding a reputable firm to guide your efforts is imperative. As the number of companies claiming expertise in web marketing continues to grow, you may find it hard to choose a vendor that meets all your needs. Generally, hiring a company who is diversified in all areas of Internet marketing will be more cost effective for you in the long run (and less of a headache) than having to manage separate vendors who handle specific aspects of your strategy.

*This guide offers general questions to ask when interviewing firms and highlights points to consider before making your next move in the world of Internet marketing.*

1

## Choosing a Search Engine Marketing Company

**Q: Do you outsource any elements of web design, website build, or SEO services?**

A: It is important to work with a company that has knowledge of core search engine marketing services such as design, web development, and content creation to ensure consistent quality and coordinate all of the moving parts.

**Q: Do you have dental customers I can talk to?**

A: When speaking with other customers, make sure you ask about their specific experiences with the company including aspects of customer service and responsiveness to requests. Search engine marketing is extremely dynamic and you need a partner who is accessible and can move quickly.

**Q: Do you provide exclusivity or do you work with multiple practices in one area?**

A: Your online marketing strategy is something that should be held in confidence between your practice and vendor. If you employ a company that provides the same strategy for your competitors, you won't be gaining a competitive edge.

2

## Web Design

**Q: Will my design be custom or will it be generated from a template?**

A: A customized design is essential in establishing your brand online. When you are providing aesthetic procedures tailored to each patient's unique dental needs, your website should reflect this.

**Q: How well versed is your company in Search Engine Optimization (SEO)?**

A: SEO should be the main emphasis of your planning process, not an after-thought when designing a new website. While some companies can offer stunning design, SEO may not be an area of expertise. Save yourself frustration and money, and choose a vendor with distinction in both areas.

**Q: Will I own my website after I pay for it? What about the content?**

A: Although the lower initial website set-up often associated with a leased website is appealing, you will end up paying more in the long run. Your website is a major asset of your dental practice and full ownership, including content and all files needed to maintain a functioning site, is critical.

3

## Search Engine Optimization

**Q: Do you have experience with optimization and content creation in dentistry?**

A: While your participation will be vital to developing content that reflects your personal philosophy, you don't want to have to spend time teaching your SEO company about dental procedures.

**Q: Can you show some examples of first page search engine rankings?**

A: Every successful dental SEO company should be able to show you at least 10 examples of front page placement under competitive terms.

**Q: Will you itemize how you charge for SEO services?**

A: SEO best practices have been well documented, and a reputable firm should be able to tell you exactly what is being done to increase and maintain your search engine rankings.

4

## Pay Per Click (PPC) & Online Media Buying

**Q: How do you determine my Pay-Per-Click (PPC) budget?**

A: A safe bet is to start with a modest ad budget and build upon your success as you attract new patients. Your budget should be based on procedures you wish to target and a thorough competitive analysis in your area - not a blanket budget set for every practice.

**Q: How do you charge for PPC management? Is it a percentage spend or an hourly rate?**

A: If a company includes your management fee and ad costs in one lump sum, it is important that you know exactly how much is going towards ad spend. A reasonable percentage would be no more than 15% of your spend on management.

**Q: Will the campaigns be set up in my own account?**

A: Since there is long-term valuable information associated with Google Adwords & Analytics, it is important that your accounts be linked and portable, and that you have the ability to log in and track your keyword clicks & spend.

5

## Social Media Optimization

**Q: How do you plan on helping my practice build a fan base?**

A: The focus of building a fan base should be centered around quality rather than sheer quantity. A smaller, targeted audience is much more useful than a wide fan base of individuals who do not live in your area. Your first goal should be building a strong base comprised of your existing patients. From there you can move on to attracting "friends" of these individuals.

**Q: Who will keep my social media page updated?**

A: Although having an outside company take total control of this responsibility sounds appealing, outsourcing your efforts is the anti-social solution to social media. The key to success is interaction with your fan base, and nobody will have a better understanding of your patients than you and your staff. Ask to see examples of successful campaigns and look for good interaction with the fan base.



# SPRINGING *from* Diagnosis

## ESTHETIC DENTISTRY:

### Photographic diagnosis and treatment planning

Alain Méthot, DMD, MSc

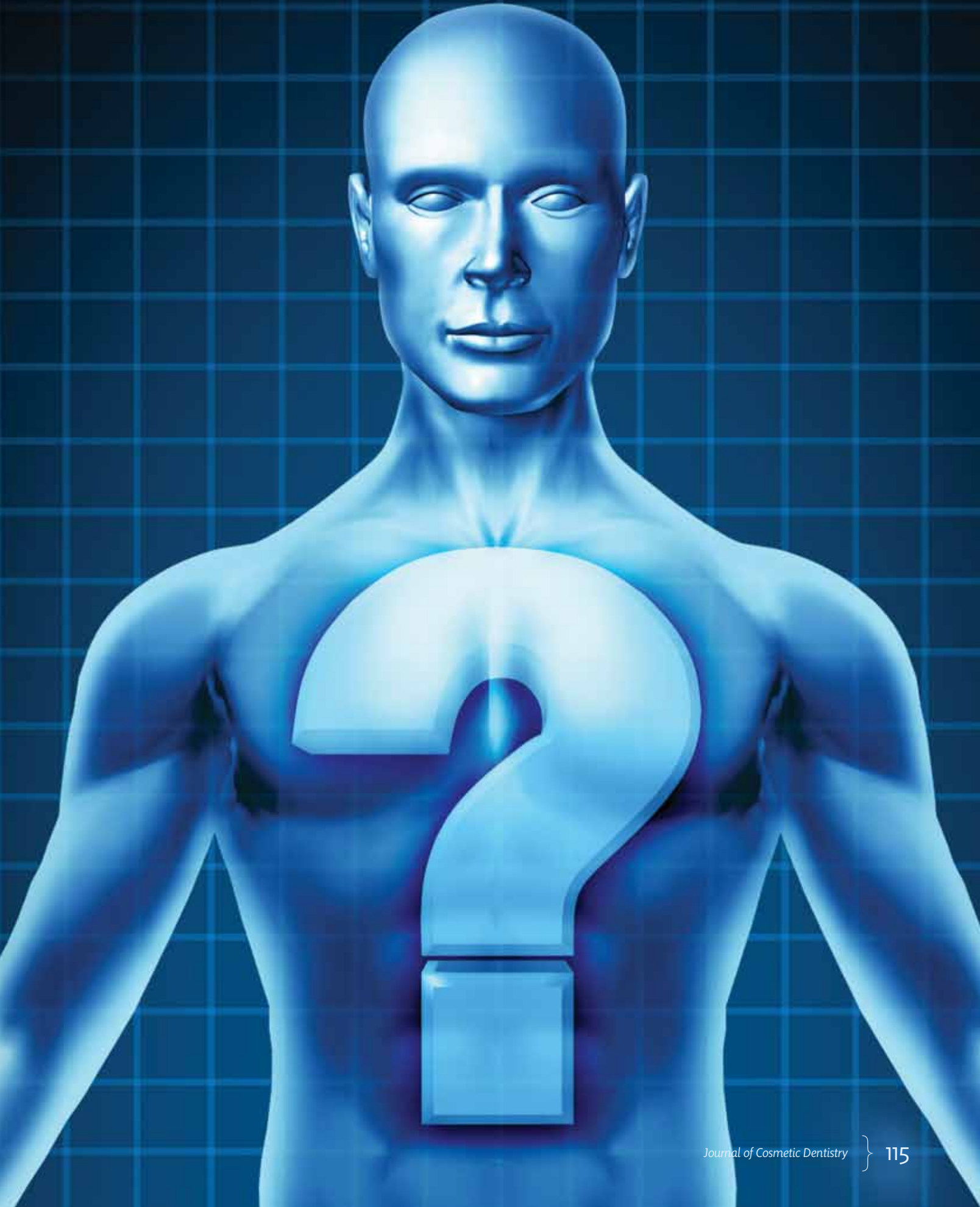
**In the realm of esthetic dentistry, photography is often overlooked or underutilized as an essential diagnostic tool that can effect a positive outcome.**

#### INTRODUCTION

Treatment planning springs from diagnosis. Effective treatment depends upon an accurate diagnosis to help the body recover from disease or cope with a condition. An accurate diagnosis is essential before treating any dental disease or condition.

Clinical examination, radiographs, and study models are long-standing, essential tools to help practitioners diagnose dental problems in the majority of cases. However, in the realm of esthetic dentistry, photography is often overlooked or underutilized as an essential diagnostic tool that can effect a positive outcome. When dental treatments are performed to respond to a patient's demand for improved esthetics, it is even more important to choose the diagnostic tools that will help achieve reliable esthetic results to meet the patient's expectations without compromising dental health and function.

Images were used in this case, not only for diagnosis, but also for simultaneous treatment planning and projection of the final smile. This was achieved by using a software tool that creates a precise and reliable virtual wax-up.



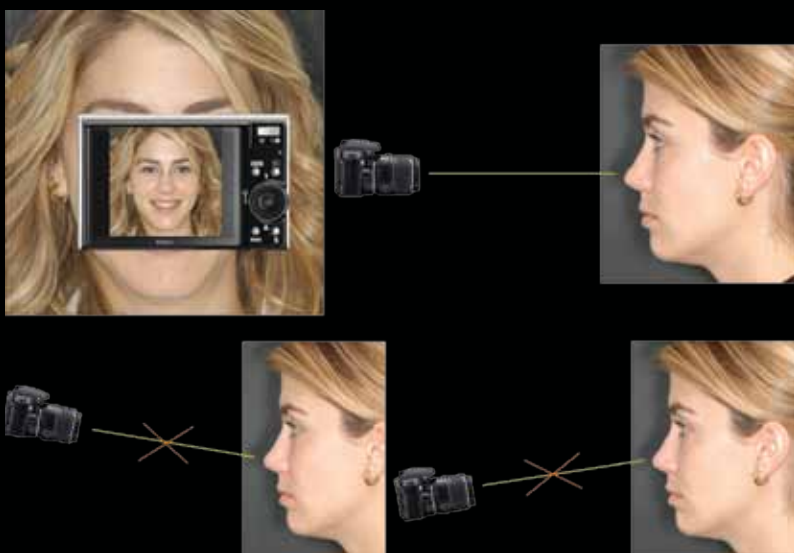
## INTERPRETATION

Esthetic dental treatments frequently begin as suggestions that are made based upon the practitioner's judgment and experience before any specific diagnosis is made, using customary diagnostic tools. Practitioners might also offer suggestions based upon the patient's esthetic requirements. A level of trust develops based upon this interaction as well as upon the personal rapport between the patient and practitioner. If the patient wants to further investigate treatment options, the practitioner should establish a diagnosis to produce treatment plans.



**Figure 1:** Preoperative, natural smile.

(Note: with the exception of **Figure 2**, all images in this article were computer-generated.)



**Figure 2:** Photo protocol, keeping the camera and patient's Frankfort plane parallel to the ground.

There is a "gray zone" in esthetic dentistry:

- It is not a purely scientific discipline.
- It is influenced by the practitioner's perception, experiences, knowledge, and judgments about what is an esthetic smile.
- It is a field of dentistry that has no rigid protocol for treatments.
- It is influenced by the patient's taste and wishes.

## NEED FOR A VISUAL SYSTEM

In many cases, patients are not entirely clear about all possible treatments and the final esthetic results available to them. Most of the time they cannot visualize the final results in their mouth before engaging in costly treatments. Even if a diagnostic wax-up is made by the dental laboratory and shown to the patient, or if a provisional is made from the wax-up and tried as a mock-up in the patient's mouth, this single proposed wax-up may not be the optimal esthetic solution for that particular patient.

There is a need for a visual system with tools that will systematically guide practitioners through smile assessment to help diagnose esthetic shortcomings and treatment plans; in other words, the optimal options that can be achieved for each patient.

The ideal visual system is a diagnosis/communication tool that does the following:

1. Allows practitioners to create a virtual diagnostic wax-up based upon the patient's facial photograph.
2. Allows the practitioner to systematically formulate a diagnosis based upon smile, lip, and tooth symmetry measurements that are specific to that patient.
3. Offers different smile "samples" that can be adapted to the smile design measurements and smile design principles dictated by the patient's face.
4. Allows the practitioner to choose a smile that will complement the patient's personality and be in harmony with their facial features.
5. Serves as a clinical communication tool that reveals the steps involved in various treatment options.

## CASE PRESENTATION

A 48-year-old female presented in good health; she had a healthy mouth and was diligent about having a regular dental examination and cleaning every six to nine months.

The patient's appearance and smile were very important to her. During her yearly follow-up examination, she expressed a keen interest in making changes to the appearance of her smile.

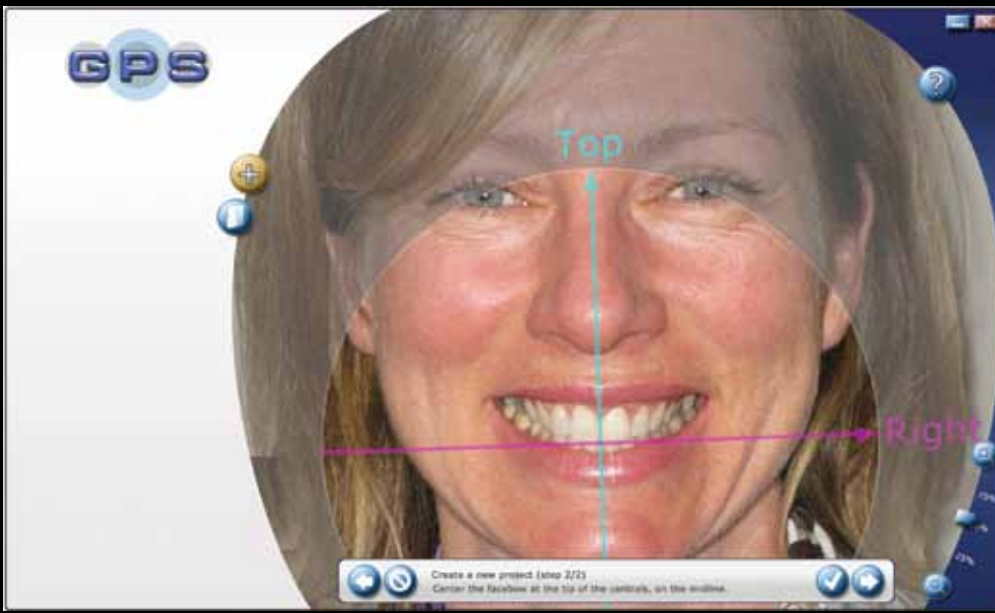


A full-face photograph of the patient was taken (**Fig 1**) and the image was uploaded to Dental GPS software (Dental GPS; Laval, QC, Canada) to analyze her smile.

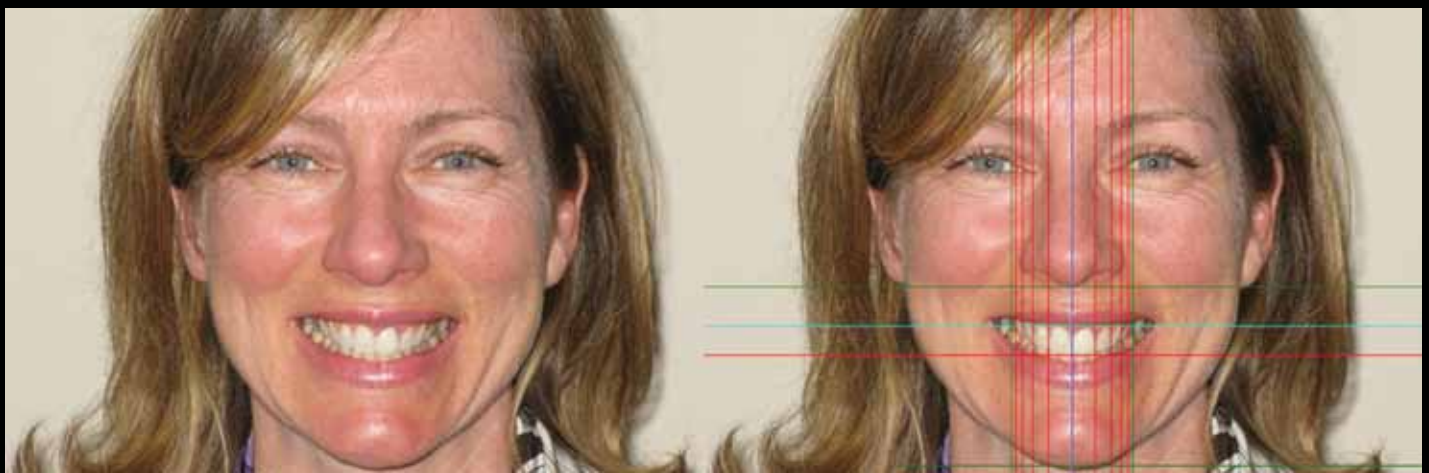The facial photograph must be taken in a direct frontal view in order to use the software for diagnostic purposes (**Fig 2**).<sup>1</sup> This view is critical for diagnosis and to ensure accuracy in the dental laboratory's subsequent work.

In the next view (**Fig 3**), the patient's facial photograph has been introduced in the GPS software and the junction of the dental midline and incisal edges of both centrals is matched with the long axis of the patient's face by using the GPS digital facebow.

From that image, an esthetic diagnosis can be made with the help of the diagnostic menus in the software and a proportion tool called the M ruler, which is overlaid on the patient's facial photograph. The M ruler is a diagnostic tool for smile design using an algorithm based on the upper central width and the width of the patient's maxillary complex that will give the ideal disposition of teeth in the patient's face.<sup>2</sup>



**Figure 3:** GPS digital facebow.



**Figure 4:** Smile analysis using the M ruler.

Compared to the “golden proportion,” which can offer only one ratio: 1:1.618, the M ruler determines the patient's own unique ratio for smile design. The standard golden proportion works well for the determination of the central incisor ratio; however, in the majority of cases, it fails to provide a pleasing smile when used to develop the proportion of central to lateral to cuspid.<sup>3,4</sup> This proportional relationship is shown in **Figure 4**.

## DIAGNOSES

When the M ruler (with vertical lines) is overlaid on the patient's facial photograph, it will help diagnose facial and dental asymmetries, teeth displacements, and gingival discrepancies. The M ruler places vertical visual guides (**red lines**, **Fig 4**).

In addition to the M ruler, three horizontal guide lines (**Fig 4**) can be used to establish the ideal position of the incisal edges of the maxillary central incisors<sup>5</sup> (**red line**), the gingival margin of the central incisors (**light blue line**), and lower facial height (**two green lines**). The lower facial height is established as the distance between the base of the nose and the bottom of the chin.

# Heraeus

## Venus Diamond®

Blending elegance and efficiency.

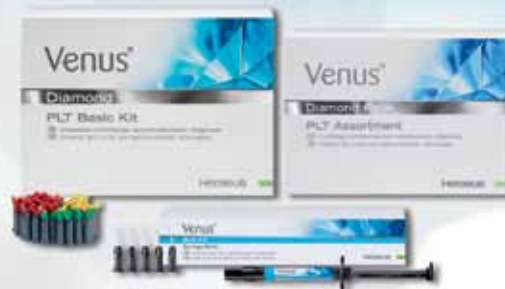**Venus Diamond** provides superb color adaptation, low shrinkage stress, high durability, and excellent handling for esthetic brilliance without compromise.

When used with **Venus® Bulk Fill**, the low stress baseliner-to-bulk-fill solution, **Venus Diamond** provides the perfect finish for a restoration that unifies simplicity and beauty.

### **PURCHASE** 5 Refills of

Venus® Composite, Venus Diamond®,  
Venus® Flow, or Venus Diamond® Flow,  
**RECEIVE** 2 of the same **FREE – PLUS**  
a syringe of Venus® Bulk Fill **FREE!**

1000803757

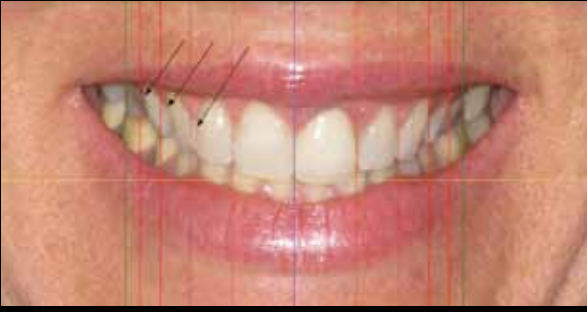

TO REDEEM FREE PRODUCTS: Purchase products from an authorized Heraeus dealer on one invoice between 4/1/12 and 6/30/12. Write campaign code on your invoice and fax it to (877) 271-5211. Invoices can also be mailed to Heraeus, Attn: Free Goods Fulfillment, 300 Heraeus Way, South Bend, IN 46614. Invoice must be received by 7/31/12. All offers subject to change. Not to be combined with any other offers. Please allow 6-8 weeks from receipt of invoice for delivery. OFFER EXPIRES 6/30/12.

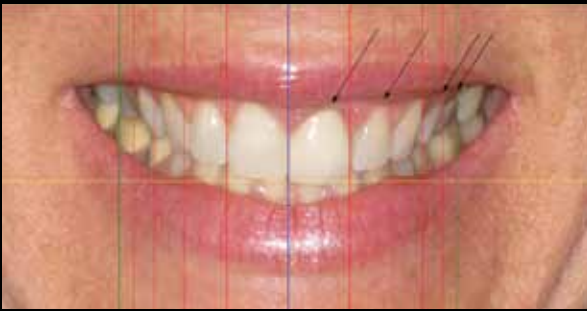\*Refill equivalent is syringe or 20-pack PLT.

Venus® and Venus Diamond® are registered trademarks of Heraeus Kulzer GmbH.  
© 2012 Heraeus Kulzer, LLC www.heraeusdentalusa.com

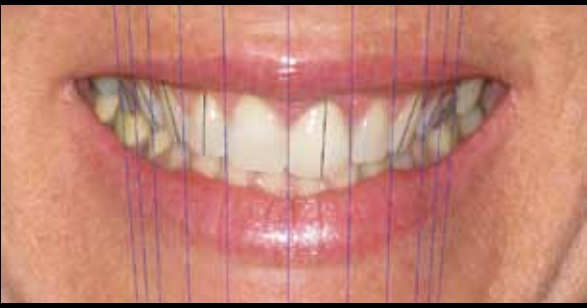Venus®  
The New Esthetics



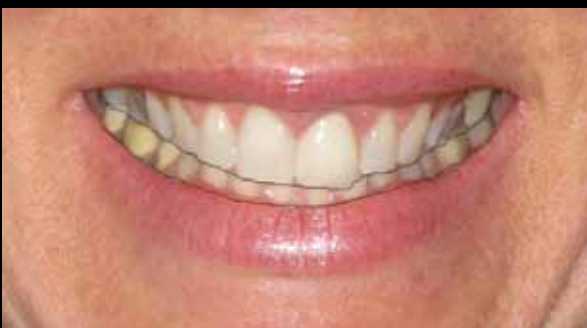**Figure 5:** The smile analysis suggests a deficiency in the buccal corridor. The positions of ##5-7 do not adequately fill the space, creating negative space and constricting the visual arch form.



**Figure 6:** The smile analysis reveals that the gingival height needs to be corrected on teeth #9 and #10, and #13 and #14.



**Figure 7:** The smile analysis reveals axial inclination discrepancies of the maxillary (see black lines).



**Figure 8:** Incisal edges of the maxillary teeth should follow the smile line.

These horizontal guides work in concert with one another; the incisal edges of the maxillary centrals (**red line**) are actually established in relationship to the base of the nose and the base of the chin (**green lines**) to ensure the ideal position of the central incisors according to the lower facial heights.

In **Figure 5**, it is apparent that the three maxillary teeth on the right side of the patient's mouth (lateral, cuspid, and first bicuspid) are not positioned against the M ruler (**red lines**), and the first diagnosis is revealed: unilateral constriction of the maxilla or malposition of the right lateral, cuspid, and first bicuspid.

In **Figure 6**, the gingival architecture is not symmetrical on both sides of the mouth. The gingival tissue is lower on the left upper central, left lateral, left first premolar, and the left first molar. The diagnosis was gingival contour discrepancy.

In **Figure 7**, it is apparent that the axial inclinations of the eight maxillary teeth shown do not match the ideal axial inclination. The blue vertical incline lines are also a feature of the M ruler that allows the practitioner to see the ideal inclination of the posterior teeth compared to the actual inclination of the teeth. The diagnosis was improper axial inclination.

In **Figure 8**, the curvature of the maxillary teeth does not follow the lower lip line. The diagnosis was inadequate, uneven smile line.

## PROPOSED TREATMENT PLANS

### TREATMENT PLAN #1

Several treatment plans with final visual results were shown to the patient, in addition to the option of doing nothing at all. The first treatment offered was orthodontics to correct the gingival contour level, the axial inclination, the smile line, and the disposition of teeth.

### TREATMENT PLAN #2

The second proposed plan consisted of a gingivectomy on four maxillary teeth and 12 maxillary crowns, or veneers from molar to molar.

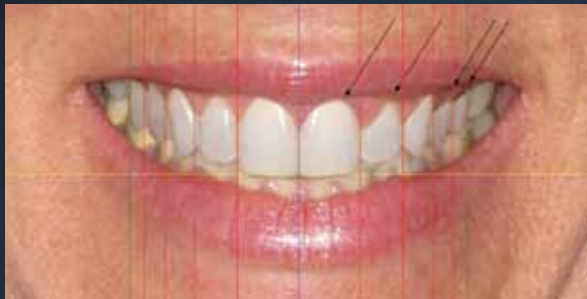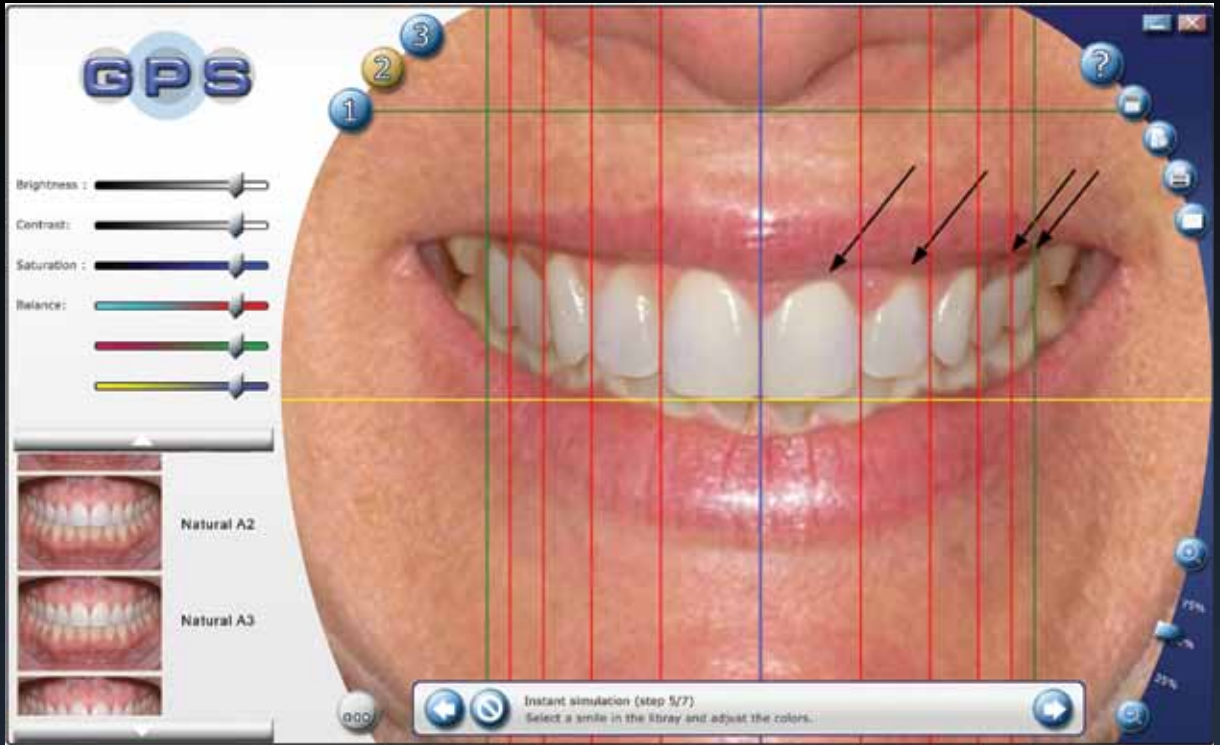
Option 1: Using the simulation feature in the software, it was possible to execute the gingivectomy on screen to correct the gingival architecture. A new smile was chosen from the smile library that morphed into the image of the patient's mouth to visualize the disposition of the teeth. By using additional simulation features in the software, it was possible to correct the smile line and the axial inclination and teeth length (**Figs 9a-9d**).

By using the M ruler, we were able to correct the smile line, the axial inclination, and teeth disposition by creating a virtual diagnostic wax-up using computer imaging techniques. Each smile option that was incorporated in the patient's mouth was then able to be adapted to the fu-

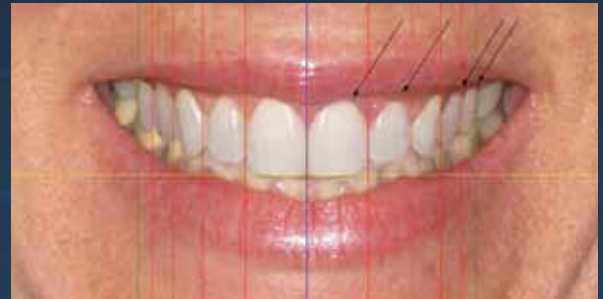

Figures 9a-9d: Treatment plan #2, Option 1.

**Figure 9a:** The need for a gingivectomy is diagnosed on teeth #9, #10, #13, and #14.



**Figure 9b:** The gingivectomy is performed directly on the screen with the gingivectomy tool.



**Figure 9c:** Results after gingivectomy.



**Figure 9d:** Images before and after gingivectomy.

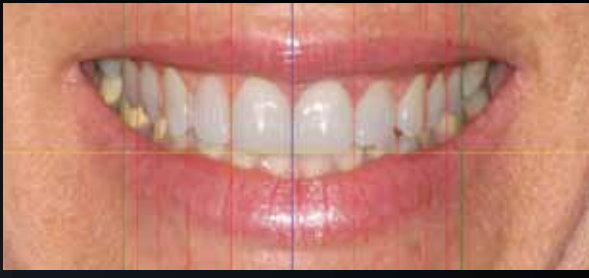

Figure 10a: Treatment plan #2, Option 2.



Figure 10b: Treatment plan #2, Option 2.

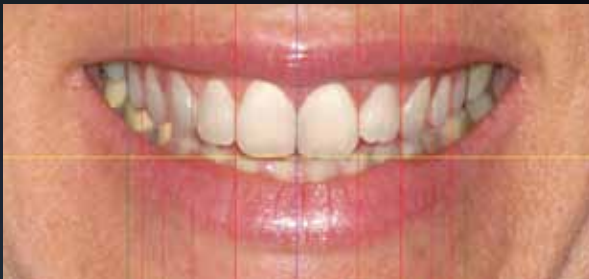

Figure 11a: Treatment plan #2, Option 3.



Figure 11b: Treatment plan #2, Option 3.

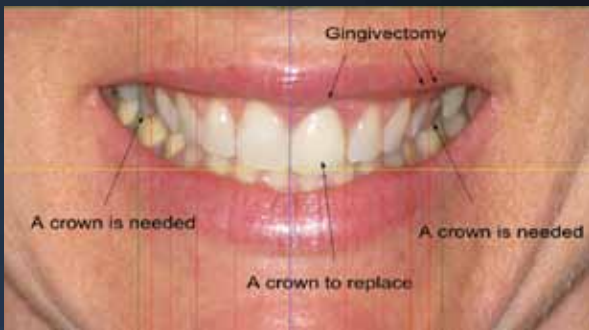

Figure 12: Full diagnosis.

**Patients have the right to see which of the possible smiles and alternative treatments will best suit their face and budget before committing to esthetic treatments.**



Everything counts at the

# CAC

Comprehensive Aesthetics Center



Barbara W. Wojdan, CDT, AAACD  
barbwarner@knightdentalgroup.com

## Cosmetics



Lonnie Lee, CDT, AAACD  
llee@knightdentalgroup.com



Knight Dental Group  
*Nothing Compares to Knight*

800-359-2043  
knightdentalgroup.com





**Figures 13a-13e:** Treatment plan #3 (patient's final choice).

ture gingival architecture of the patient, and provided a different tooth shape and morphology, a different emergence profile, and different colors. It was possible for the patient to observe different smiles adapted to her mouth when the practitioner selected smiles from the smile library; each smile was morphed automatically by the software into the photo of the patient's mouth.

Option 2: A new smile with fuller buccal corridors, square teeth, and a more masculine look can be achieved using a smile library with a bigger emergence profile (**Figs 10a & 10b**).

Option 3: A new smile with fuller buccal corridors, and a younger and more feminine look can be achieved using a different smile library with a bigger emergence profile and rounder teeth (**Figs 11a & 11b**).

### TREATMENT PLAN #3

A third, less invasive treatment plan was also offered to the patient. It comprised whitening, gingivectomy, and crowns on three teeth.

As treatment planning was done from the same initial full-face photograph, it was interesting for the patient to visualize the different alternatives on the same facial view. In **Figure 12**, the gingival height on the maxillary left central, the left first premolar, and the left first molar are not in harmony with the global gingival architecture. The maxillary first molars were restored with large amalgam restorations, which provided a dark color, were inclined lingually, and did not fill the buccal corridors. The maxillary left central was restored with a ceramic-metal crown that was too opaque and too yellow, the gingival margin was inflamed and the gingiva was not at the same height as the adjacent central. The restored central was also longer than the natural adjacent central.

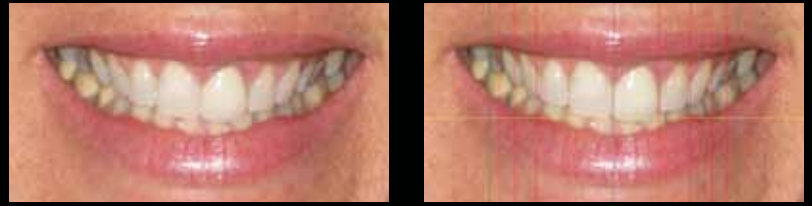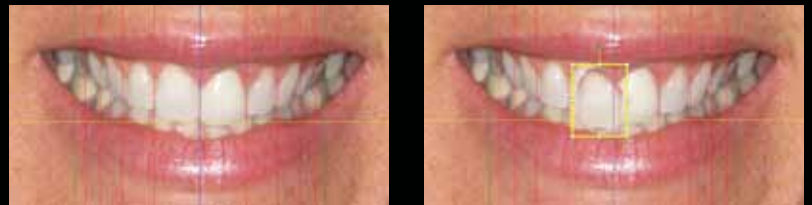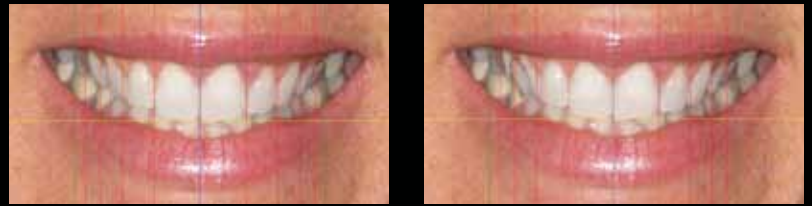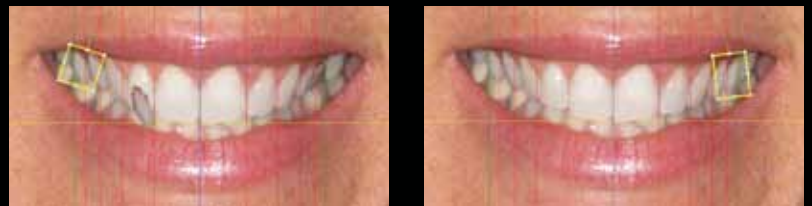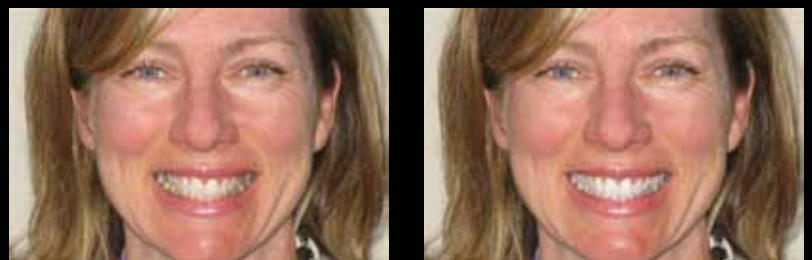**Figures 13a through 13e** show the progression of this treatment plan as it was shown to the patient before proceeding with the proposed treatment.

This third treatment plan was the most impressive compared to the others and shows a smile that is well balanced in the patient's face, a filled buccal corridor, and symmetry between the two centrals. This simulated smile looked natural and the patient liked the fact that this plan was less invasive and less costly. She accepted this treatment plan.

### TREATMENT

The patient was treated in the following sequence.

1. The patient brushed with X-Pur toothpaste (Oral Science; Longueuil, QC, Canada) for four weeks to desensitize teeth before whitening with the Zoom2 in-office whitening system (Discus Dental; Culver City, CA).

**Figure 13a:** Close-up images before restoration.**Figure 13b:** Restoration module—copy of right central.**Figure 13c:** Restoration module—shows placement of the right central and a copy of the first right premolar, which is then placed on the right molar.**Figure 13d:** Restoration module—shows a second copy of the first right premolar; it is then flipped and placed on the left molar.**Figure 13e:** Before and after image of restorations.

2. Gingivectomy and preparation of the maxillary teeth, three months after bleaching.

Before preparing the three maxillary teeth, a laser gingivectomy was performed (Biolitec; East Longmeadow, MA) on the left central, the left first premolar, and the left first molar; and the three Empress crowns (Ivoclar Vivadent; Amherst, NY) were fabricated on the left central, the left first molar, and the right first molar based upon the patient's smile design from the virtual wax-up of the Dental GPS prescription (Fig 14).

The patient's final facial photograph is shown in Figure 15.

## CONCLUSION

Using a simple facial photograph and a diagnostic tool like the M ruler, it is possible to diagnose, treatment plan, and achieve the patient's smile design. An additional benefit is that, thanks to the visual simulation, the patient understands the treatment plan from the preoperative image through to the final cementation of the restorations. Patients have the right to see which of the possible smiles and alternative treatments will best suit their face and budget before committing to esthetic treatments.

Esthetic dentistry relies on patient trust, traditional wax-ups, or artistic modifications of provisionals in the mouth to achieve the desired smile. The traditional laboratory wax-up allows the patient to visualize only one smile design possibility. Different possibilities can also be visualized if the dentist fabricates the provisionals in the mouth, a time-consuming chair-side procedure that also delivers only one possibility for the patient to see.

Esthetic dentistry simulation systems have, to date, been useful as a general visualisation tool but have not been reliable as a diagnostic tool. Now, however, it is possible to create a reliable, virtual diagnostic wax-up to use as a springboard for treatment planning, giving direction to smile design planning with reliable precision. It also is now possible for practitioners to offer patients the opportunity to see what their final smile would look like within several treatment plan simulations before they accept the proposed treatment.

## References

1. Rufenacht CR. Fundamentals of esthetics. Hanover Park (IL): Quintessence; 1990.
2. Méthot AM. Proportions the new golden rules in dentistry. Canadian J Cosmetic Dent. 2006;1:34-40.

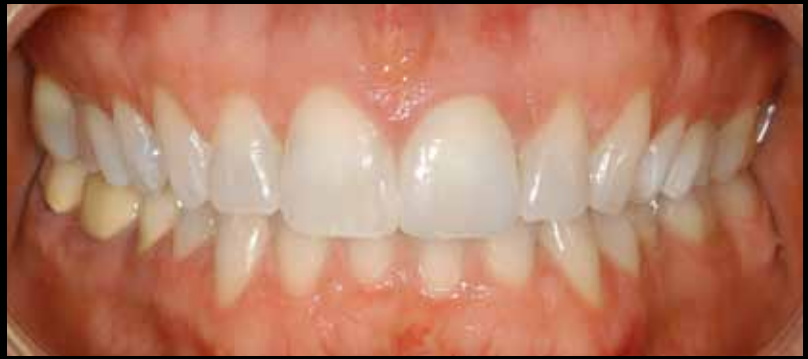

Figure 14: Retracted view of final restorations.



Figure 15: Postoperative, natural smile showing the final restorations.

3. Preston JD. The golden proportions revisited. J Esthet Dent. 1993;5(6):247-51.
4. Levin EI. Dental esthetics and the golden proportion. J Prosthet Dent. 1978 Sep;40(3):244-52.
5. Ward D. Proportional smile design using recurring esthetic dental (RED) proportion. Dent Clin North Am. 2001 Jan;45(1):143-54.



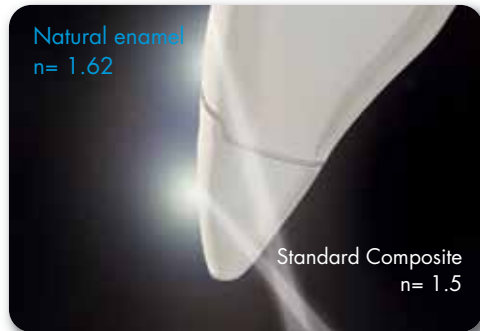
Dr. Méthot earned his DMD degree in 1981 from the Université de Montréal. He earned a Master's degree in occlusion in 2011 from Danube University, Krems, Austria. He is a researcher and developed the GPS computer software system.

Disclosure: Dr. Méthot is supported by Dental GPS.

## LIKE NATURE DOES IT !




### THE PROBLEM

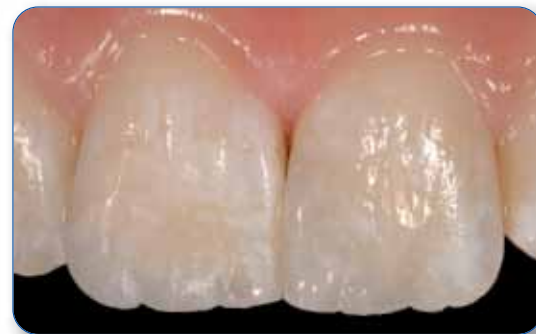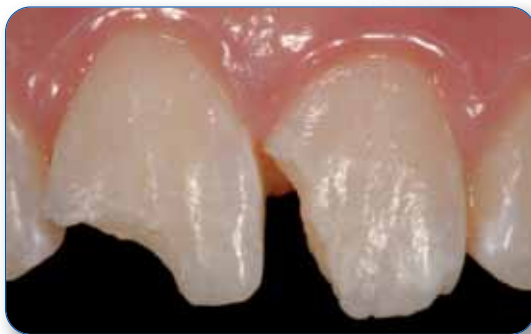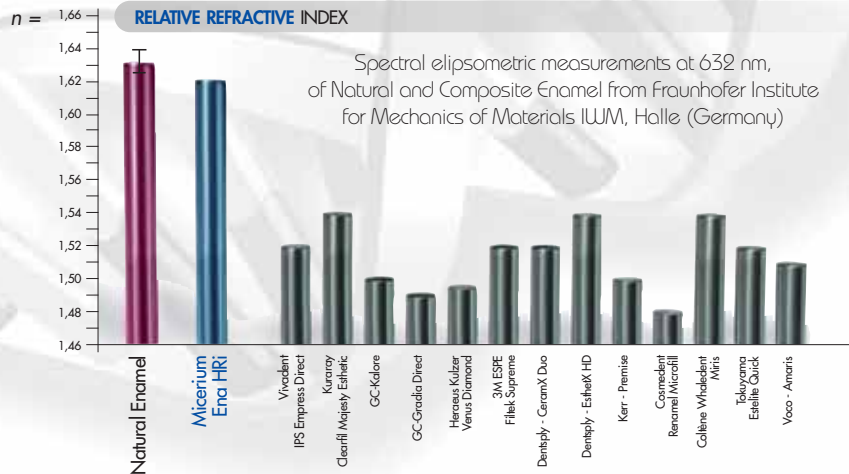


**"GLASS EFFECT" LOWERS THE VALUE OF THE RESTORATION WITH A GRAY HALO ON THE MARGIN (DARK LINE)**

### THE SOLUTION



**INVISIBLE MARGINS, IN HRi RESTORATION, USING THE SAME THICKNESS OF THE NATURAL ENAMEL**



Clinical case by Dr. L. Vanini





# APPROACHES to *Smile* Design

Mathematical to Artistic Interpretation

Brian P. LeSage, DDS, FAACD  
Luca Dalloca, DMD, CDT, FESCD, FIADFE  
Illustrations by Zach Turner



## Introduction

With advanced knowledge, techniques, and materials, dental professionals today have the ability to approach smile design cases in a variety of ways.<sup>1</sup> Often reliant upon culturally-based philosophies and ideologies, the way in which cases are handled can vary greatly depending on a dental professional's location.<sup>1</sup> There is no better example than the differences between European dentists, who tend toward a more artistic, "whole person" approach to smile design—taking into account age, gender, and replication of that individual's natural dentition—and dentists in the United States, who tend to focus more on brighter color, symmetrical/proportional, rules-governed ideal restorations that are not achievable in nature.<sup>2,3</sup> Today, however, both sides are meeting in the middle, with European patients requesting a less natural look and American patients desiring more natural-looking smiles.<sup>4</sup>

Allowing for better insight and knowledge into what it takes to make a restoration truly perfect in the eye of the beholder, the concepts and practice of esthetic dentistry benefit from differing opinions and, therefore, are in a constant state of evolution.<sup>4-6</sup> However, the need to develop reproducible restorative results has pushed dentists to quantify the smile design process with rules, formulas, and measurements, which may actually inhibit their esthetic perceptions and ability to identify and provide those individual nuances that create natural beauty.



### Learning Objectives:

After reading this article, the participant should be able to:

1. Compare criteria and the principles of art and visual perception.
2. Understand how to use symmetry, asymmetry, and "perfect imperfection" to create a beautiful smile.
3. Contrast the different approaches when applied to treating individual patients.

## ...the concepts and practice of esthetic dentistry benefit from differing opinions and, therefore, are in a constant state of evolution

### Defining Esthetics in Dentistry

It is a common misconception among some dental professionals that esthetic outcomes result solely from a set of well-defined rules.<sup>7</sup> Although it is necessary to understand and follow fundamental principles and parameters of what constitutes esthetic smiles, limiting dental professionals to specific guidelines and quantified measurements would lead to generic, boring, and stereotypical results for patients.<sup>7</sup> Following a stringent and rigid approach breaches any perception of “Mother Nature.”

Many publications historically have attempted to quantify the correct principles of smile design, but no one has demonstrated the inherent ability to teach the dental professional how to create a truly natural-looking smile.<sup>7</sup> For example, a misconception guiding many smile design principles is that components of the smile (e.g., tooth shape and size, embrasure form, axial inclination, gingival morphology, arrangement, and silhouette) should be symmetrical, a phenomenon that simply does not occur in nature.<sup>7</sup>

Instead, a more comprehensive approach is advocated, one that requires consideration of the philosophies of beauty and art in combination with fundamental smile design principles. Like the human face and smile, there is no better example of this than the complementary functions served by each side of our brain.<sup>7</sup>

### The Human Brain—Combining Reason and Creativity

Although the left and right sides of the brain may appear symmetrical under medical imaging, each side functions in a very specific way.<sup>8</sup> While the left side

handles verbal, analytic, symbolic, temporal, rational, computing, logic, and linear functions, the right side of the brain is involved in non-verbal, synthetic, analogical, atemporal, non-rational, spatial, intuitive, and artistic functions. Individuals often mistakenly believe that traits of the right side of the brain are inherited, or that one must have a disposition toward artistic and creative talents. However, it is well documented in the literature that individuals are given creative potential and have the opportunity for expression through art.<sup>8</sup>

#### Art as a Skill

It has been shown that art is a medium through which individuals develop the skills needed for the brain to approach tasks more creatively. A side of neurological function that is all too often suffocated by mundane daily tasks, developing the functions of the right side of the brain allows individuals to perceive tasks and outside influences in a different way.<sup>8</sup>

Artistic ability is a global, or “whole,” capability requiring only a limited set of basic components that, when integrated, form a whole skill that, once learned, allows a person to create art. This progression, however, requires practice, refinement of technique, and learning the situations in which the skills should be used.<sup>8</sup> Although artistic talents are referred to as such, they are actually perceptual skills that include five components (i.e., perception of edges, space, relationships, lights/shadows, and the whole, or the “gestalt”).<sup>8,9</sup>

Overall, artistic talent is the ability of an individual to shift the state of the brain into a different mode of seeing and perceiving. When learning how to create art, individuals learn how to control the way the brain processes information.<sup>8</sup> Shifting the brain to see in a particular way is the true challenge of

artistic ability. Through this global approach to the development of artistic skills, dentists in particular can form associations and reveal intimate structures that would otherwise go unnoticed.<sup>8</sup> However, with familiarity comes competency.

### Applying the Artistic Process to Dentistry


The reason dental professionals often find it difficult to address esthetic cases is that they do not realize that there is actually no such thing as unesthetic dentistry; there is *only* esthetic dentistry. Every case, no matter what the patient presents with, should be addressed as an esthetic case. Therefore, when approaching dental care, dentists must put aside the belief that the ability to step outside of the logical “left-side thinking” and into the creative right side is a predisposed, inherited ability.<sup>10</sup>

However, doing so requires knowledge of the psychology of perception and of the manner in which the natural characteristics of the dental/smile architecture influence the overall perceived appearance of the patient. Consider visual fields (Figs 1 & 2). Although human perception is an agglomerate of certain aspects of an object, including colors, forms, movements, and dimensions, it is first an interaction between guided tensions. For any spatial relation, there is a precise distance that is intuitively decided upon by the eyes. The eyes are drawn to the center, as it is the major area of attraction and repulsion. At this center, all forces are balanced and the central position of an object is perceived as stable.

Additionally, balance is the distributive condition in which each situation reaches immobility; it is achieved when all forces of a system are compensating themselves. Balance is when the poten-




- By looking at the picture for just a fraction of a second it seems that the disc is closer to the center than it appears if we look at it slowly and dispassionately.
- This demonstrates that the physical and psychological systems show a very diffuse tendency of transformation to the lower level of tension.




## TENSION

**Figure 1:** Human perception is first an interaction between guided tensions.



- The disc gives us a greater impression of stability when its center fits with the center of the square.
- For every spatial relation there is a precise distance, perceived by the eye.
- The center is the place of major attraction and repulsion.
- At the center all forces are balanced; this means that a central position is perceived as stable.

**Figure 2:** Eyes are drawn to the center, where all forces are balanced and the central position of an object is perceived as stable.



- The position of the disc could be determined and described by measurements.
- We could then realize that the disc is not central.
- This finding is not a surprise—we do not need any measurements to see that the disc is not centered, we can easily see it with our visual judgment

## VISUAL JUDGMENT

**Figure 3:** The eyes are intuitively able to find balance.

tial energy of a system is reduced to its minimum. With this, every visual situation is created by a fulcrum and a center of gravity. The eyes, when using the right side of the brain, can intuitively sense to find these factors and balance from there (Fig 3).

One of the most important factors in determining how art can be applied to dentistry is the way in which the visual weight of an object in view affects the way it is perceived. Typically, weight is also applied and used in conjunction with other defining characteristics. For example, spatial depth or the objects in depth are the first to draw attention in any figure observed. This characteristic is most notable when viewing a person's face, where the eyes and mouth draw the most initial attention. Another characteristic, color, affects how an object is perceived, with different colors creating different perceptions. For example, red has more visual weight than blue, and white has more weight than black, which is why a person's eyes often draw the most attention upon first glance (Fig 4). However, because white has more weight than darker colors, the viewer's eyes are immediately drawn to the teeth when the person smiles (Fig 5).

Dimension of an object plays an equally important role in defining weight, since the bigger the object, the more attention or weight it demands (Fig 6). Dimension, however, becomes irrelevant when discussing isolation, because an object in isolation will demonstrate a greater visual weight than any other object (Fig 7). In addition to the aforementioned characteristics, shapes are also important. The side on which an object is present (i.e., left or right) can affect the object's appearance (Fig 8). For example, all objects on the right are perceived as larger than those on the left. Therefore, one of the biggest mistakes that clinicians make with their patients is to allow them to analyze their smile in a mirror, because on a perceptual level they are speaking two different "languages." If they want to understand each other, they must evalu-

ate the smile in an image in such a way that the right and left sides are the same for both viewers.

The final characteristic, configuration, determines how an object appears and the visual weight it commands. Configuration, in general, is the determining factor in the physical form an object takes. It is the external aspect and visual weight that allows the eyes to see and capture the prominent features.

Given the right side of the brain's innate ability to undertake such functioning, dental professionals can apply the basics of the "artistic view," the foundation of which is the understanding that the whole cannot be achieved through the addition of small, isolated parts. Rather, considering the previously mentioned concept of "globality," dentists and technicians must first understand the overall integrated structure.<sup>8,10</sup>

## Artistic Perceptions of Smile Design Components

When designing a smile, it is important to understand the differences in tooth shape and structure based on the individual patient. It also is necessary to realize that characteristics like age and gender play an important role in how restorations should be completed. These characteristics are particularly significant in the central and lateral incisors and also are reflected in tooth shape and color (Fig 9).

### Central Incisors

When restoring the central incisors, age is the determining factor in how the finished restoration should appear. In younger smiles, the central incisors tend to be long and rectangular. In younger patients, the central incisors should be longer than the lateral incisors, with a 65% width-to-length ratio and prominent incisal embrasures. Also, the mamelon pattern should follow greater thickness and volume of the enamel, which will ultimately lead to a pronounced halo. In younger dentition, there is an increase in irregularities and reflective diversity, including perikyma-

ta, stippling, and striation. With these effects, a lighter color goes along with an increase in value (Table 1).

In comparison, the central incisors in older dentition tend to be squarer and shorter, appearing equal to the lateral incisors and canines. With a 90% width-to-length ratio, mature dentition also display decreased incisal embrasures and smooth, higher-shine facial anatomy (craze lines). Mature central incisors are typically darker in color and show a decrease in value (Table 2).

In consideration of these principles and realizing the importance of central dominance, there are tools to aid in making an individual look older or younger. These principles are listed in Tables 3 and 4. Table 4 outlines strategies for treating older patients who desire much whiter teeth than would be age-appropriate. These simple tools will help make even the whitest of cases blend in due to the concepts of composition and consideration of "the whole," allowing for a sense of realism.


### Lateral Incisors

Based on gender, the lateral incisors are evaluated on their size compared to the central incisors, the softness or hardness of their outline form, and their arrangement in the oral cavity. Even though dentists have at best a 50/50 chance of determining a patient's gender by looking at their laterals, there still can be seen a relative difference or varied perception when it comes to tooth shape, size, and anatomy. Therefore, the gender of the patient is often considered before any restorative work is completed.

Although not definitive, according to Lombardi,<sup>11</sup> Frush, and Fisher, the lateral incisors in males have typically been viewed as wider at the neck, with parallel proximal line angles and flatter incisal edges. The width of the lateral incisor also appears similar to the central incisors, with convex gingival embrasures.

In the restoration of female lateral incisors, differences from male patients are often observed and considered. For

## Weight and Colors




**Figure 4:** Red has more visual weight than blue, and white has more weight than black.



**Figure 5:** White has more weight than darker colors, so the viewer's eyes are drawn to the teeth; the lines show how the pattern of eye movement travels on the face.

From: *Eye Movement and Vision* by Alfred L. Yarbus, Institute for Problems of Information Transmission, Academy of Sciences of the USSR. Moscow; 1967.

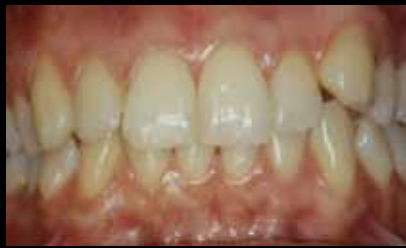
## Weight and Dimension



**Figure 6:** The bigger the object, the more attention or weight it commands.

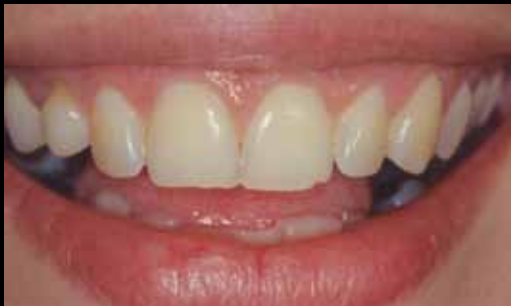

## Weight and Isolation

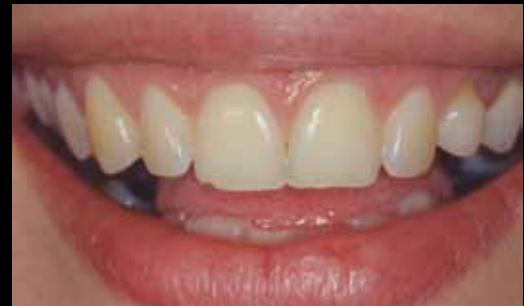

**Figure 7:** An object in isolation will demonstrate a greater visual weight than any other object.

## Weight and Side

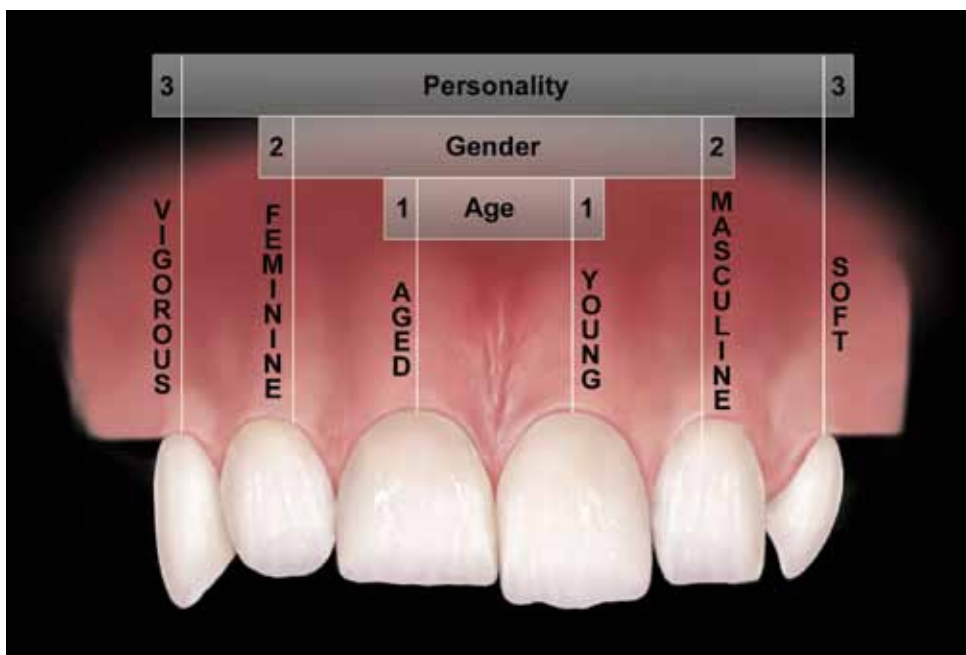


Left



Right

**Figure 8:** The viewer can appreciate how the deciduous canine is far more visible in the right-hand image than in the left-hand one.



**Figure 9:** Lombardi,<sup>11</sup> Frush, and Fisher described the central and lateral incisors as imparting age and gender characteristics while playing into the dynamic negative space.

Reprinted from *The Journal of Prosthetic Dentistry*, volume 29 issue 4, 1973, *The Principles of Visual Perception and Their Clinical Application to Denture Esthetics*, pages 358-382. With permission from Elsevier.

**TABLE 1: Characteristics Seen in Younger Teeth**

- Long, rectangular shape to central incisor
- 65% W/L ratio
- Prominent incisal embrasures
- Mammelon pattern and greater thickness and volume of enamel leading to a pronounced halo
- Increased irregularities and reflective diversity (perikymata, stippling, striation)
- Lighter color and increase in value

**TABLE 2: Characteristics Seen in Older/Mature Dentition**

- Squarer shape to central incisor
- Central incisor shorter: equal to the lateral incisor or canine
- 90% W/L ratio
- Decreased incisal embrasures
- Sharp, angular incisor corners
- Smooth, higher shine facial anatomy (craze lines)
- Darker color and decrease in value

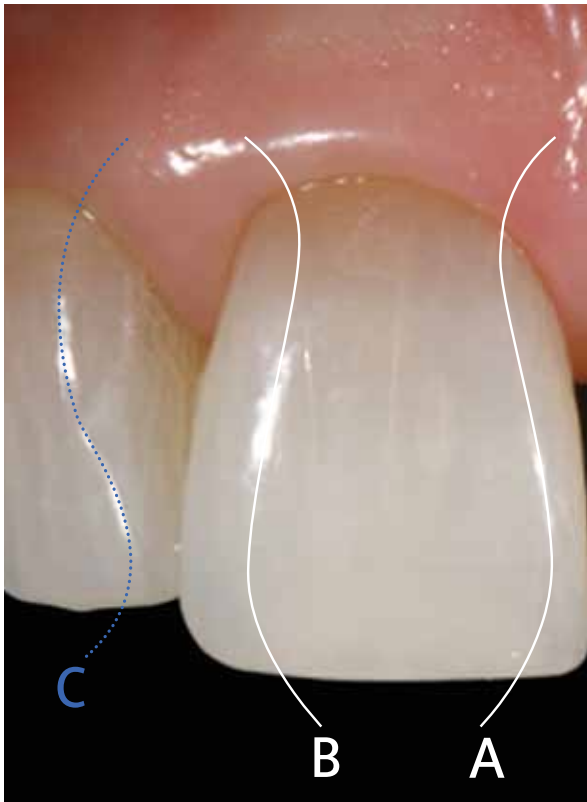**TABLE 3: Characteristics or Tools to Aid in Making Someone Look Younger**

1. Creating centrals dominance is key.
2. Make the teeth lighter in color, with the centrals the brightest.
3. Design centrals that are longer (60-65% W/L ratio) and laterals that are shorter than a line drawn from the centrals to the cuspids.
4. Bring centrals slightly more facially than laterals.
5. Show more central below intercommisural line and fill more of the smile space.
6. Increase incisal translucency in the centrals and laterals.
7. Add more texture and anatomy to the centrals and laterals.
8. Characterize the incisal edge using mammelons and avoiding straight incisal planes.
9. Round incisal line angles and create incisal embrasures with depth and volume.
10. In the relaxed lip position or "M" position, have tooth display of 3-4 mm.

**TABLE 4: Characteristics or Tools to Aid in Making Someone Look Older**

1. Create teeth that have the signs of wear and use mandibular teeth going into protrusive and lateral excursive movements as a guide.
2. Make centrals and laterals approximately on the same plane.
3. Make centrals shorter with a 85+% W/L ratio.
4. Make incisal edges straighter and little/minimal to no incisal embrasures.
5. Show less tooth structure in the relaxed lip position or "M" position.
6. Make teeth darker, especially the cuspids.

**Tables 1-4** show principles taught in the UCLA Aesthetic Continuum Course and Advanced Anterior Esthetic Course: LeSage B, Morley J, Eubank J.



**Figure 10:** (A) "S" curve on the mesial showing the transition line angle. When line angles are well established, the camera flash will pick them up as reflective zones. (B) Reverse "S" curve showing reflective zone and transition line angle on distal of tooth #8. (C) "S" curve position will aid in determining reveal of tooth and give uniformity with variety to outline forms.

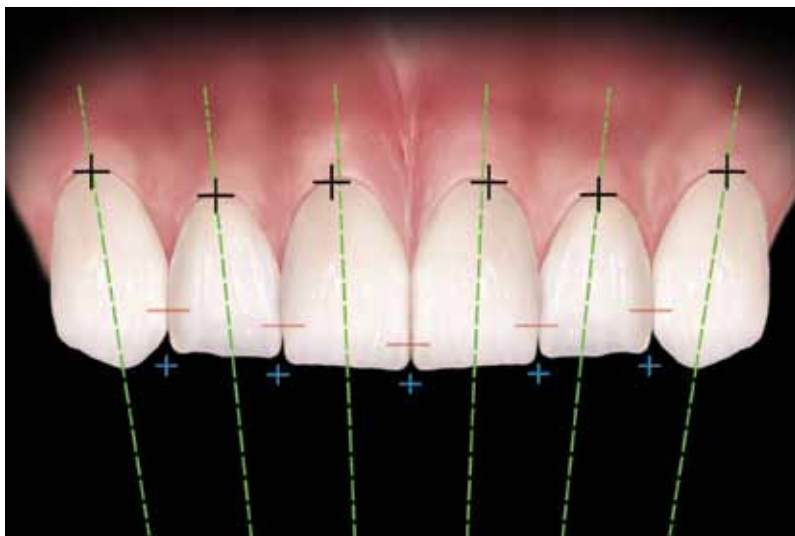
example, female lateral incisors have typically been viewed as narrower at the neck and constricted at the gingival aspect, with diverging proximal line angles. With this, the incisal edge appears rounded, and the lateral incisor appears narrower than the central incisor, with concave gingival embrasures.<sup>10</sup>

Although mentioned in the literature, these male and female defining characteristics are to be used only as a starting point when restoring the dentition, not as definitive rules. These parameters, at best, can be used as a guide; when applying the right side of the brain, color, spatial depth, dimension, weight, configuration, and globality weigh as heavily. When attempting to determine gender by the morphology of the teeth, however, it is challenging.<sup>12,13</sup> The authors liken this to a local forensic office attempting to determine the gender of the deceased using only the morphology of the dentition, which often returns non-definitive results.<sup>12,13</sup> Simplified, consider these as society-imposed guidelines.

### Tooth Proportion/Size/Symmetry

Among the objective criteria to be evaluated when planning a smile design case, proportion, size, and harmony also are important. Harmony, a form of balance, is further described as the weight of objects on either side of a midpoint in equilibrium. The proportion of the teeth, or width-to-length ratio, should range between 70% and 85%. The average size of the central incisors, for example, should be a length of between 10 to 11.5 mm, with an average length of 10.5 mm.<sup>14,15</sup> To facilitate proper harmony, line angles should be based on the "S" curve and the reverse "S" curve (Fig 10). Altering the "S" and reverse "S" curve will affect weight and balance and is an excellent way to create uniformity with variety.

When developing harmony, it is also important to consider the outline form, profile, embrasures, and contact points, which should be moved from the incisal to a more apical position from the central incisor to the canine (Fig 11). When creating this progression, the smile line should be mimicked using the intuitive and artistic (right) side of the brain<sup>16</sup> The eyes perceive any one shape of an element (tooth) secondarily to the shape of a series of elements (teeth). Isolation is the exception, as a tooth completely out of position will dominate the whole and lead to problems. Stein described it best as "perfect imperfections."

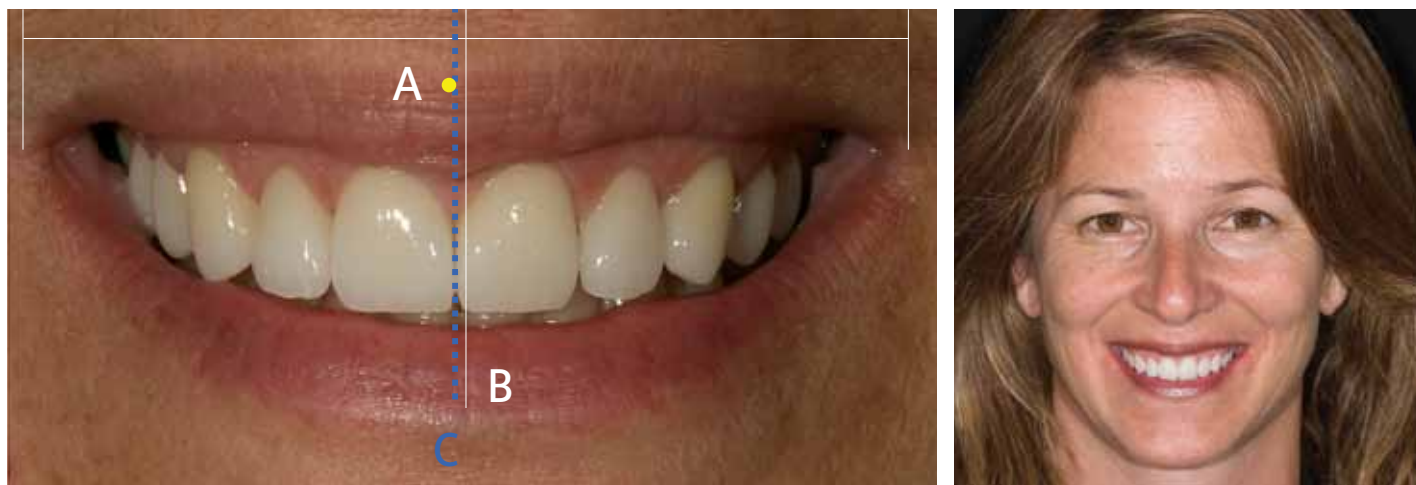

**Figure 11:** As the embrasures gain depth and volume from the central incisors posteriorly, the contact is moved more apical. This shortens the contact "zone," which defines the 50:40:30 rule.

### Midline

The most important focal spot in an esthetic smile, the midline is an imaginary line dividing the midline lobe of the philtrum, or midpoint of the intercommisures (also referred to as "Cupid's Bow"), in the center of the upper lip into equal and balanced halves (Fig 12).<sup>17</sup> Patients tend to relate their midline to the upper lip, rather than to other facial features that are further from the mouth.<sup>11,18</sup> However, a properly placed midline, in conjunction with a long, solid interproximal contact relationship between the two central incisors, produces cohesiveness of the smile composition.<sup>11</sup> This effect is desirable in esthetic cases and





**Figure 12:** Left: Midline. (A) Cupid's bow. (B) Midpoint to intercommisural line. (C) Actual dental midline. Right: Full-face image showing balance in facial-dental esthetics.

enhances the appearance of the dentition and facial features.<sup>11</sup> The incisal plane must be at a right angle to the midline, but most importantly, parallel to the patient's natural horizontal head position, since parallelism implies harmony and is the starting point of weight, balance, and composition of the smile.

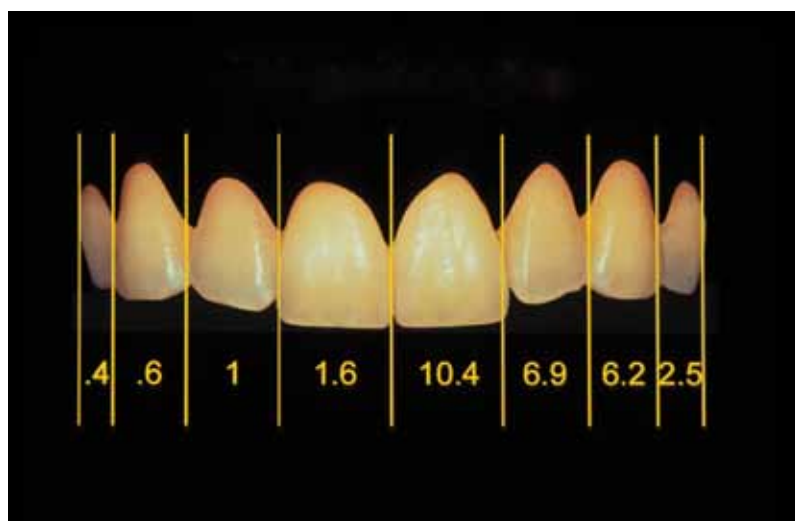
#### Golden Proportion

The "golden proportion," which does not apply to natural smiles because nature does not know symmetry,<sup>19</sup> is considered the established criteria of an average smile (Fig 13). Based upon the ratio of 1.6:1, the golden proportion should not be interpreted as the rule, but rather considered a biological guideline.<sup>6</sup> In fact, in Preston's study, none of the subjects followed golden proportion. Most consider it too distracting, and its judicious use must be emphasized.<sup>19</sup>

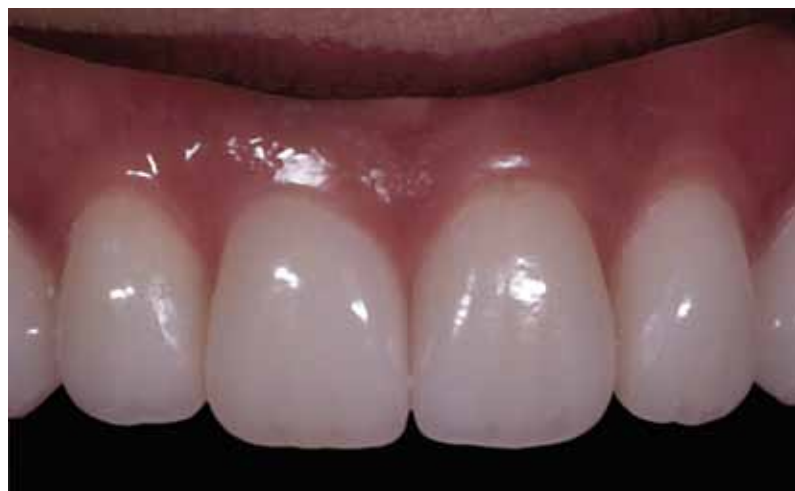A preferred, more natural ratio to follow is one in which the laterals are 65% the width of the central, and the canine is 75% to 80% the width of the lateral.<sup>6,19</sup> Further analysis would have female teeth at 61% to 65% the width of the centrals, and males having closer to 65% to 70% the width of the centrals. However, this also can be too oversimplified and rigid.

#### Significance of Gingival Esthetics

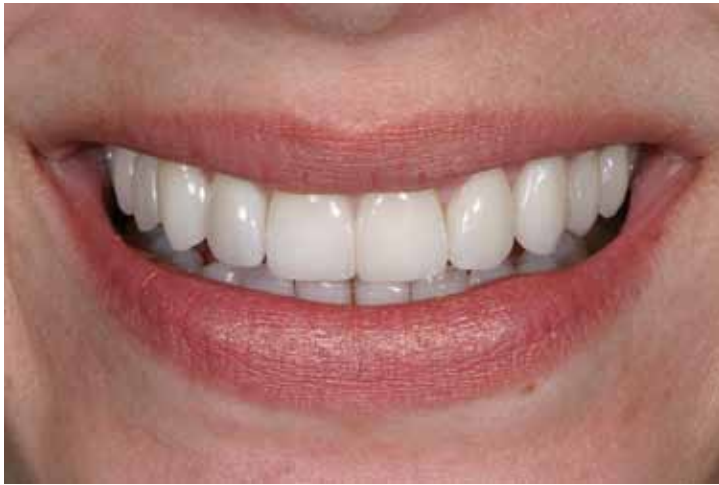Dental and gingival esthetics combine to provide a smile with harmony and balance.<sup>20</sup> The quality of the dental restorations will not compensate for a defect in the surrounding tissues. Gingival tissues should appear pink, stippled, and firm, and should display a matte surface.<sup>20</sup> The papillae should be pointed and fill embrasures to the contact area (Fig 14).<sup>21</sup> Demonstrating distances of the papillae of 5 mm or less, 6 mm, and 7 mm from the interdental bone to the apical extent of the contact area, the incidences of papillae being present are 100% (5 mm), 56% (6 mm), and 27% (7 mm), respectively.<sup>22,23</sup>



**Figure 13:** The ratio of 1.6:1, as depicted here, rarely exists in nature. Compare the reveal as measured in this dentition. Repeated ratio exists between central and lateral but is violated from the lateral to the cuspid and the cuspid to the first premolar.



**Figure 14:** View showing gingival health and gingival papillae in a restored case demonstrating good fill in of embrasure spaces to the contact areas.



**Figure 15:** (A) Smile view showing primarily gingival papillae. Incisal curvature paralleling the lower lip demonstrates the dynamic negative space filling 85% of the smile space. (B) Full-face view demonstrating harmony and balance between the dentition (white esthetics) and gingival tissues (pink esthetics).

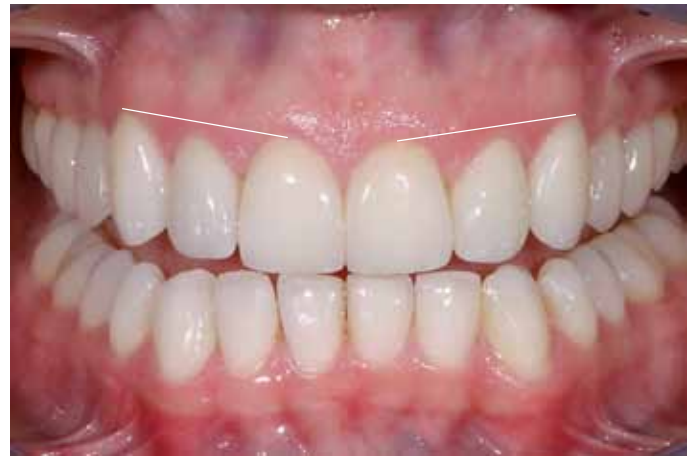### Gingival Display

In a typical smile, the gingival display should be 0 to 3 mm at full smile (Figs 15a & 15b). The symmetry of the tissues also should be nearly equal, with harmony between the dentition and gingival tissues. For example, the central incisor and cuspid should display the same gingival height, and the lateral incisor should fall 1 to 2 mm incisal to a line drawn from the central incisor to the cuspid, not apical (Fig 16).

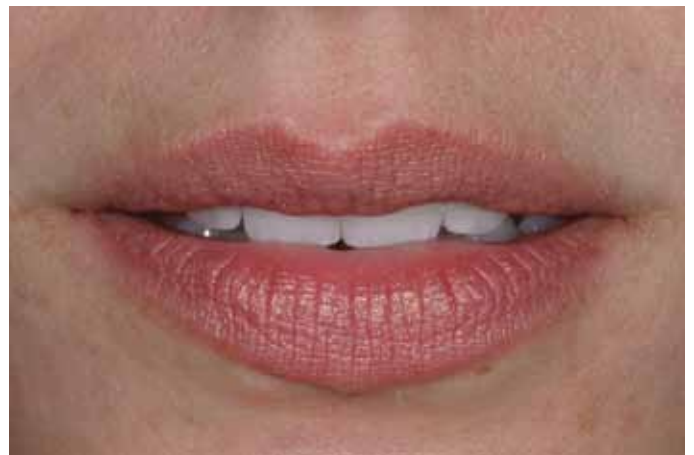Creating dynamic negative space, a correct inter-incisal distance among the centrals, laterals, and canines is necessary.<sup>11</sup> These distances ultimately will lead to the creation of an attractive incisal curvature that parallels the inner curvature of the lower lip (Fig 17).<sup>11</sup> This also has been referred to as “black esthetics” and, in the dynamic range of lip movement from full smile to the relaxed lip position, a sense of the whole (“gestalt”) will determine the outcome. Excessive tooth display in the relaxed lip position or full smile showing excessive gingivae or deficient vestibular reveal can be “pink esthetic” issues that lead to visual tension in the smile (Fig 18).

### Axial Inclination

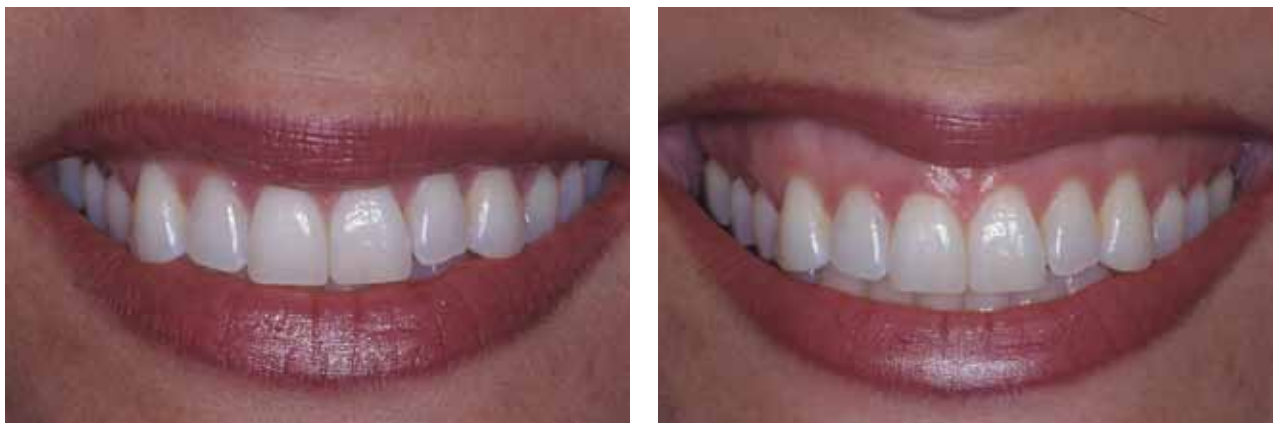Axial inclination is determined by two anatomical landmarks. Gingivally, it is at the highest point of the gingival crest (tangent) and the midpoint of the incisal edge. The line drawn between these two points defines the perceived axial inclination. Maxillary anterior teeth should have a mesial axial inclination. Worn incisal edges and/or gingival irregularities will lead to zenith and axial inclination issues (Figs 19a & 19b).



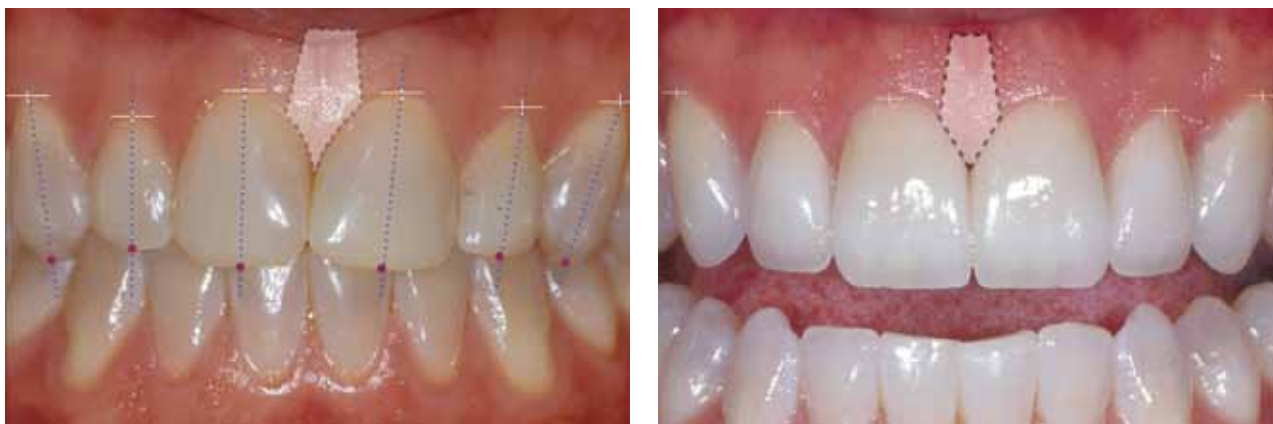**Figure 16:** Harmony and balance in the gingival morphology with healthy, stippled tissues that fill the interdental embrasure space. Lateral crest is shy of a line drawn from the central to the cuspid’s gingival contour.



**Figure 17:** Relaxed lip position showing the ideal tooth display: 3 mm for a female in her 30s.



**Figure 18:** Left: Patient's controlled smile demonstrating average lip mobility of 6 to 8 mm. Average gingival display with right side lip asymmetry. Right: Patient's full smile showing excessive gingival display.



**Figure 19:** (A) Preoperative image showing altered gingival levels, zeniths, incisive papillae, and axial inclinations. (B) Postoperative image showing improved zenith points and balance from right to left. Notice the intimate relationship between tooth shape and gingival morphology.

## Color

When discussing color in smile design, it is important to note the difference between shade selection and shade reproduction. The selection of color (also referred to as hue), relies upon the use of shade guides (e.g., Vitapan Classic Shade Guide, Vident; Brea, CA) that employ letters to represent different hues. Typically, "A" represents a red/orange-brown color, "B" represents red/yellow, "C" is equal to gray, and "D" displays as red/gray. When discussing hue, consideration of the chroma or saturation of color (also referred to as the intensity of color) is necessary as well. Dentists and technicians can choose from a light red/yellow (B1) to a darker, richer red/yellow (B4).

Coloring of restorations also involves the value and brightness (grayness) of a particular color. It is im-

portant to note that when value is increased, so is brightness. However, when increasing the value and brightness, the grayness of a restoration decreases. The translucency, opalescence, and fluorescence of the restoration also are considered during shade selection. In a simplified typical case, the central incisors will be the brightest, the lateral incisors will be slightly lower in value, and the canines will have a higher chroma (Figs 20a-20c). These determining factors can more easily be accessed in the three-dimensional or linear guide (Vita Linear guide).

Color mapping is often considered a good way to communicate shade with the technician, but this is not necessarily the case (Fig 21). In fact, whoever is fabricating the restoration should complete the color mapping. Transferrence of the color-mapping information

among team members is additional information, but its validity is doubtful. Photography is the most reliable way to communicate color to an off-site user.

## The Points of Smile Design

It is important to remember when undertaking any smile design case that, although the aforementioned parameters and those below are typically used, nature is not numerical, symmetrical, rigid, or restricted to a set of rules. These design points are merely guidelines that can be followed in an attempt to replicate nature and create restorations that mimic the natural dentition as closely as possible.

When approaching smile design cases, it is beneficial to integrate the principles of esthetics, including harmony of white, pink, and black esthetics (line angle, outline form,



## When learning how to create art, individuals learn how to control the way the brain processes information.

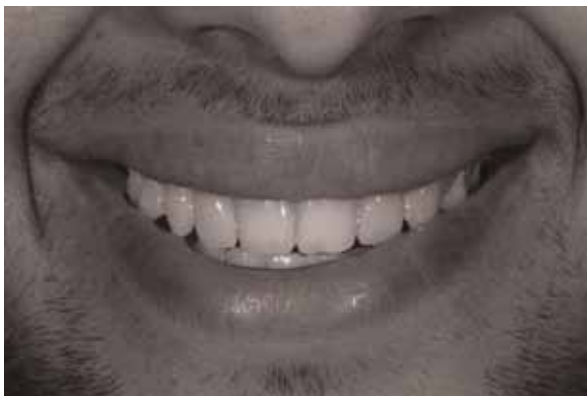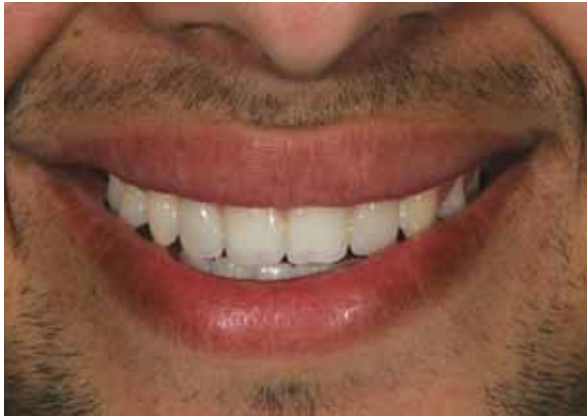profile, and embrasures), while considering dominance, composition, and repeated ratios.<sup>5,24-26</sup> Symmetry, if mentioned, refers to harmony and balance and not absolute symmetry. This involves locating the midline and direction, determining the size of the central incisors (width-to-length ratio), establishing the position of the incisal edges, creating age, possibly accounting for gender, and adding personality.<sup>5,24,27</sup> Thresholds must also be established through investigation into the individual's perception of graduated degrees of abnormality. When all elements are joined together in appropriate proportions, guided tension, weight, and balance, they will act in synergy to create a beautiful, natural-looking smile (the whole).

### Tolerance of Abnormalities

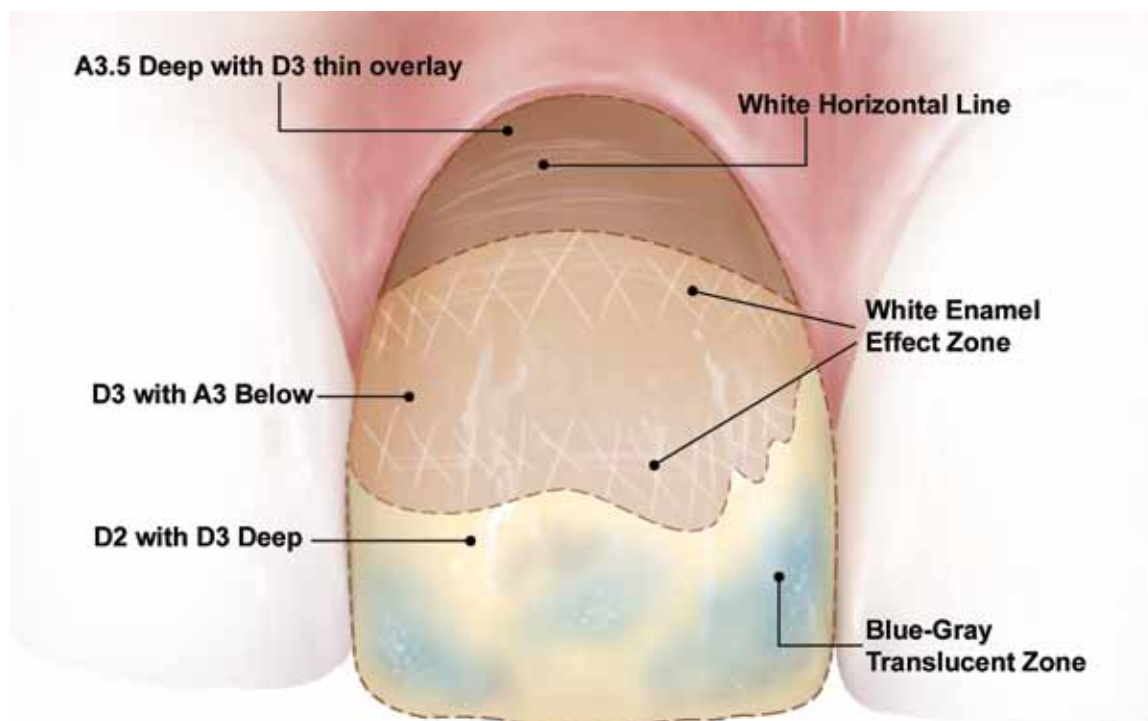
When approaching abnormalities, the overall condition and appearance of the oral cavity is typically examined.<sup>27</sup> Crown length, for example, should create harmony and balance for the centrals, which should not be shorter than the laterals. Crown width-to-length ratios should also be considered and idealized for the centrals. This is a very crucial principle. If presented with an esthetic scenario in which the canine-canine distance is narrow, clinicians should evaluate the case using a significant portion of the space on the centrals, allowing for narrower laterals or creating some overlap onto the centrals.

The incisor angulation of the restoration, or midline cant, should be viewed as unacceptable beyond 1.0 mm. Midline discrepancies in the vertical plane can be hidden by keeping it perpendicular to the horizon. This was found to be tolerated up to 4 mm.<sup>27</sup>

Any black triangles present, or the lack of gingival closure, after gingival embrasures are opened, should be kept at 1 to 2 mm. While central harmony (not symmetry) and proportions are important to the gingival margin, if shorter laterals exist, both should have the same proportion and balance. Also requiring consideration in the tolerance of abnormalities, the incisal plane becomes less detectable as it moves further from the midline, and the acceptable gingiva-to-lip distance in a gummy smile is 2 to 4 mm maximum.



**Figures 20a-20c:** (A) Color image of no-prep veneers on laterals and bonded incisal edge of tooth #8. (B) Desaturated (black and white) image of A. Values of centrals are the highest tooth in the mouth, or value of the laterals is slightly lower than the centrals. (C) Portrait showing the integration of white, pink, and black esthetics with the face in mind.



**Figure 21:** Example of a color map drawn by the clinician and used for a direct bonding case.

## The Artistic View and Biological Smile Design

After considering the artistic view, dentists and technicians can develop a treatment plan that encompasses not only esthetics, but also the biological, functional, and structural needs of the case.<sup>28</sup> When approaching restorative/esthetic dental cases, it is necessary that all parties, including the dentist, technician, and most importantly, the patient, have full involvement in the case.<sup>29,30</sup> By informing patients of all options, benefits, and risks, and allowing them to make an educated and informed decision, the overall health of the patient and the likelihood of satisfying their esthetic expectations will improve.<sup>6,7</sup> Ultimately, when a policy of open communication is implemented and followed, the best in function, esthetics, and standard of care can be achieved.<sup>29,31</sup>

## Criteria

To fully understand how a smile design case is completed, there are fundamental objective (i.e., left side of the brain) criteria that first must be addressed (Table 5). Once these areas have been analyzed, addressed, understood, and implemented, the dental team can apply subjective criteria (i.e., right side of the brain) to further develop the case and provide the expected outcome for the patient (Table 6). Initially, much of this is predicated on seeing and understanding the need for a check-off list. As the dentist's training leads to fluency in the details, their eyes will envision the final outcome with consistency and ease, and they no longer will tolerate anything short of perfect imperfections.

### Criteria Deficits

Although the criteria for biological smile design provide insights into a predictable way to treatment plan and un-

dertake a case, there are many areas that may lead to stumbling blocks. These criteria questions should be asked prior to undertaking restorative treatments and evaluated throughout treatment and again upon the completion of the dental makeover (Table 7). Table 7 was developed by the AACD/American Board of Cosmetic Dentistry® (ABCD) for the Accreditation credentialing process. It is invaluable in any restorative case involving the smile zone.

## Microinvasive Dentistry

Today, in minimally invasive dentistry, the intent is to preserve as much anatomical tooth structure as possible. The "artistic view," when applied to smile design treatments, inherently advocates a minimally invasive approach that maintains a patient's natural tooth characteristics, such as simple bleaching and/or recontouring of the teeth, orthodontics, internal bleaching, and/

<b>Table 5. Fundamental Objective Smile Design Criteria</b>
Modified from Magne and Belser, <sup>20</sup> p. 59, with permission from the author.
1. Facial and lip balance (midline)
2. Tooth size and shape (outline form)
3. Tooth axial inclination
4. Tooth proportion
5. Interdental contacts and embrasures
6. Tooth profile (three facial planes)
7. Gingival health
8. Gingival morphology and contour
9. Gingival papillae
10. Gingival zenith
11. Smile line and occlusal cant
12. Vestibular reveal (buccal corridor)

<b>Table 6. Subjective Smile Design Considerations</b>
Modified from Magne and Belser, <sup>20</sup> p. 59, with permission from the author.
1. Variations in tooth form
2. Tooth arrangement
3. Tooth texture and characterization
4. Tooth color and shade progression
5. Dynamic negative space

<b>Table 7. Biological-Based Questions for Smile Treatment Evaluations</b>
Based on the American Academy of Cosmetic Dentistry Accreditation Criteria
1. Is the periodontal health optimal?
2. Is margin placement and design appropriate? Are the margins visible?
3. Has underlying tooth color been properly managed to allow for an optimal cosmetic result?
4. Does the restoration have "show through" of tooth structure or the fracture line under the material?
5. Are the surface finish, polish, and luster appropriate?
6. Is the labial anatomy (primary, secondary, and tertiary) appropriate? Are there three planes for the labial contour of the central incisors?
7. Have line angles been properly developed?
8. Is the color (hue, value, and chroma) selection appropriate/natural, not monochromatic?
9. Are incisal translucency and halo effect appropriate?
10. Is the interproximal contact or connector proper in length and position?
11. Is the midline appropriate?
12. Is the axial inclination appropriate?
13. No dark triangles?
14. Is the cervical/incisal tooth length symmetrical from right to left?
15. Are contralateral teeth in harmony in terms of size, shape, and position?
16. Are the cervical embrasures proper?
17. Are effects of internal and surface color characterizations appropriate?
18. Is the buccal corridor properly developed?
19. Are incisal edges in harmony with the smile line?
20. Is the tooth preparation inappropriate or excessive?



**Table 8. Armamentarium Approach for Microinvasive and Artistic View Dentistry**

1. Balance search in a composition by eliminating tensions without reaching symmetry
2. Mock-ups
3. Additional Veneers (e.g., partial veneers or no-prep veneers for treating additional teeth)
4. Shells/Provisionals
5. Orthodontic Therapy
6. Tissue Contouring and Conditioning
7. Second and Third Provisionals, and Grafting

or direct composite bonding. When considering an indirect restoration, veneers often are the best tool to achieve this goal, as minimal correction of the anatomical surface of the teeth is often all that is required to make the most significant corrections to all aspects of the face.

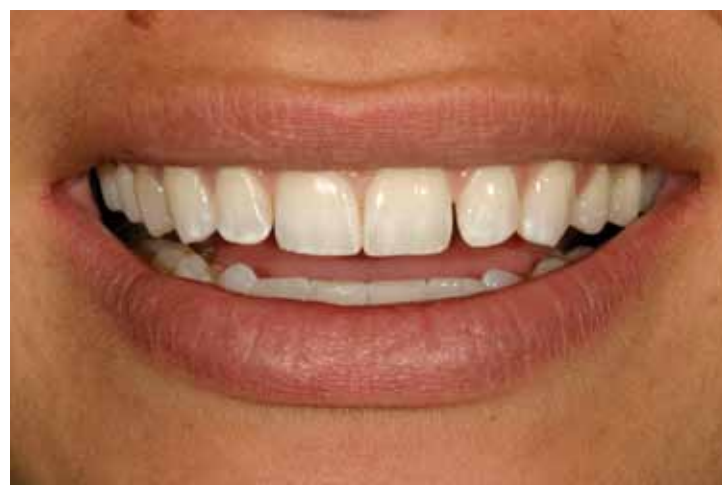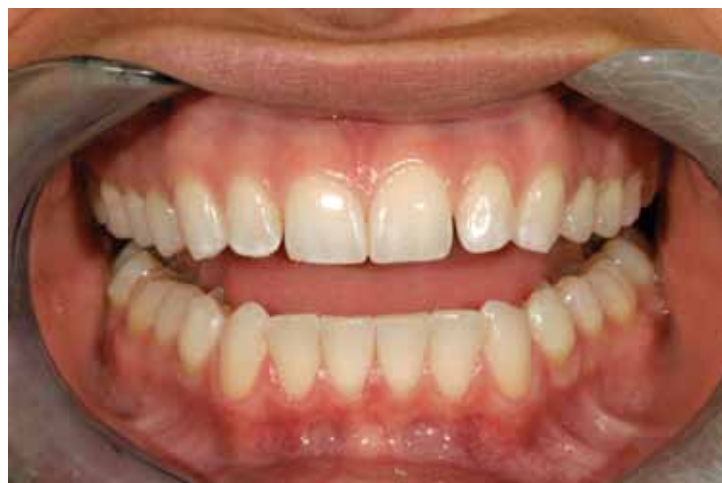Therefore, the philosophy of microinvasive dentistry—which holds that the less the dentist does to the teeth, the better it is for the patient and their oral tissues—can be combined with the artistic perception view to produce naturally esthetic restorative results. Fortunately, there are several restorative components and tools that can be used for smile design cases that incorporate both the artistic view and microinvasive dentistry (Table 8).

#### Case #1

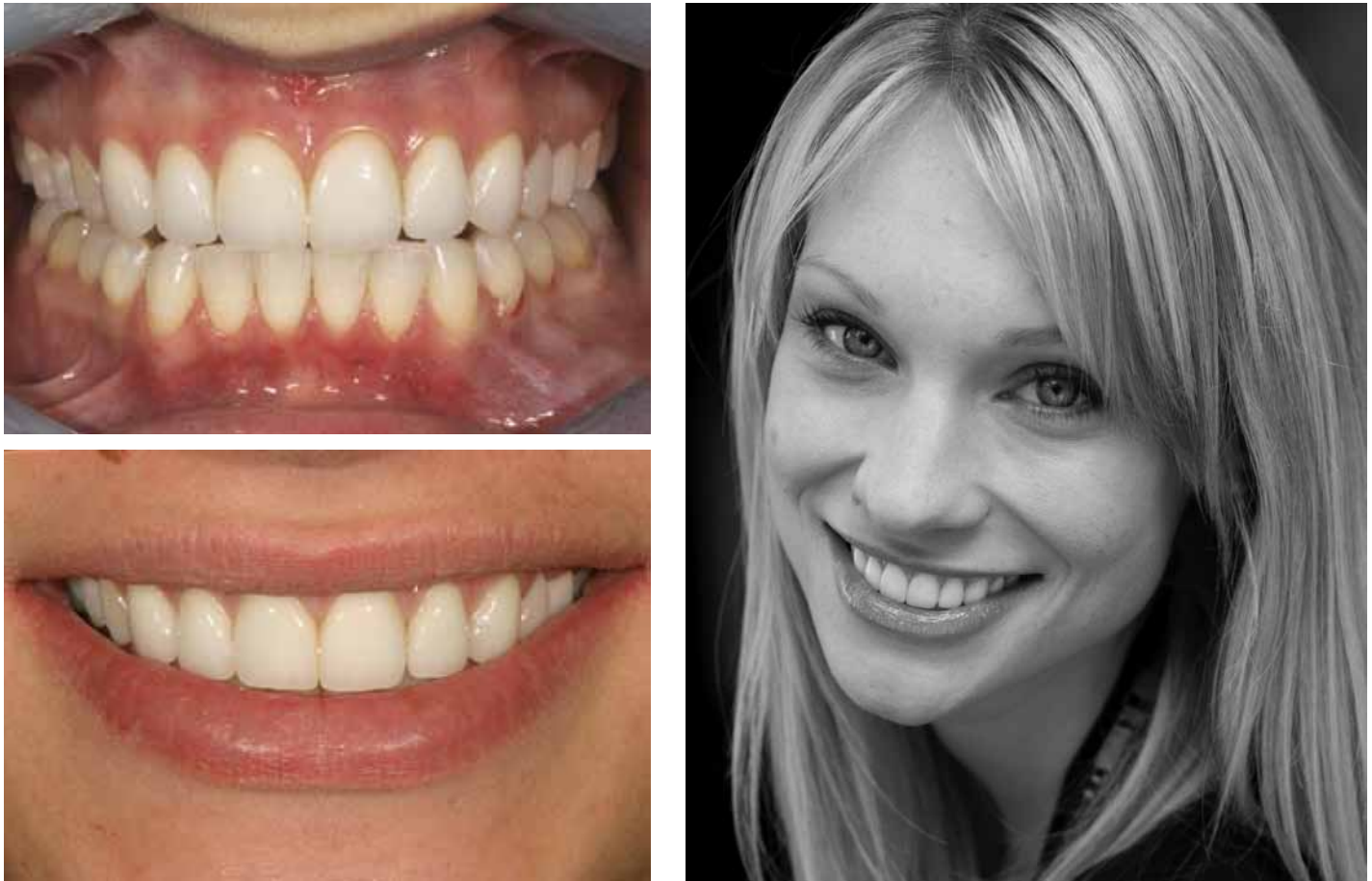Having had orthodontics five years prior, a 28-year-old female with multiple diastemas declined further orthodontic care (Figs 22a & 22b). The patient was given two options: orthodontics, which would eliminate the need for multiple veneers; and minimal preparation veneers on teeth #6 through 11 and all-ceramic restorations on teeth #12 and #13. Replacement of the crowns on #12 and #13 was necessary due to a food trap. The patient elected to undergo veneers after being informed of the advantages, risks, longevity, and prognoses of both treatment options.

Minimal preparation veneers (CL-II using the LeSage veneer classification system) were prepared with the aid of a bis-acrylic preparatory guide. This guide virtually eliminates the over-preparation of anterior restorations.

Esthetic issues discussed were multifactorial. Between the isolation of #10 and the weight of the centrals, guided tension existed. A borderline reverse smile line, distal axial inclination of #10, white maverick coloring, and diastemas mesial and distal of the laterals were other esthetic concerns. Additionally, the patient had incisal edge irregularities of the centrals and cuspids, as well as gingival asymmetry of the centrals, which highlighted the white,



**Figure 22:** (A) Retracted view showing esthetic issues. (B) Preoperative smile view of the patient's smile showing diastema and inclinations.



**Figure 23:** (A) Retracted view showing gingival health, harmony, and balance. (B) Postoperative smile, showing exceptional harmony and balance. (C) Portrait showing pleasing smile.

pink, and black esthetic violations. The color was acceptable, but balance, weight, and dimension were inclusive in the globality issues.

The definitive all-ceramic restorations (Figs 23a-23c), including a gingivectomy on #8, led to a pleasing smile defined by harmony and balance using the rules, tools, and strategies of esthetics, with an overriding influence of right-side artistic beauty.

#### Case #2

A 44-year-old male presented with a very dark tooth #9 and a large midline diastema (Figs 24a & 24b). Color was the dominant issue, and #9 overpowered his smile. With the diastema contributing to guided tension and the reverse smile line very noticeable, the patient was self-conscious about his teeth. When analyzing his smile using specific guidelines, many

parameters were problematic, especially the gummy smile in the posterior sextant. The latter did not bother the patient, nor was he looking to change his general composition, dimensions, and unique outline form, rotations, axial inclinations, embrasures, or general silhouetting of the incisal edges. He liked his slightly quirky gestalt.

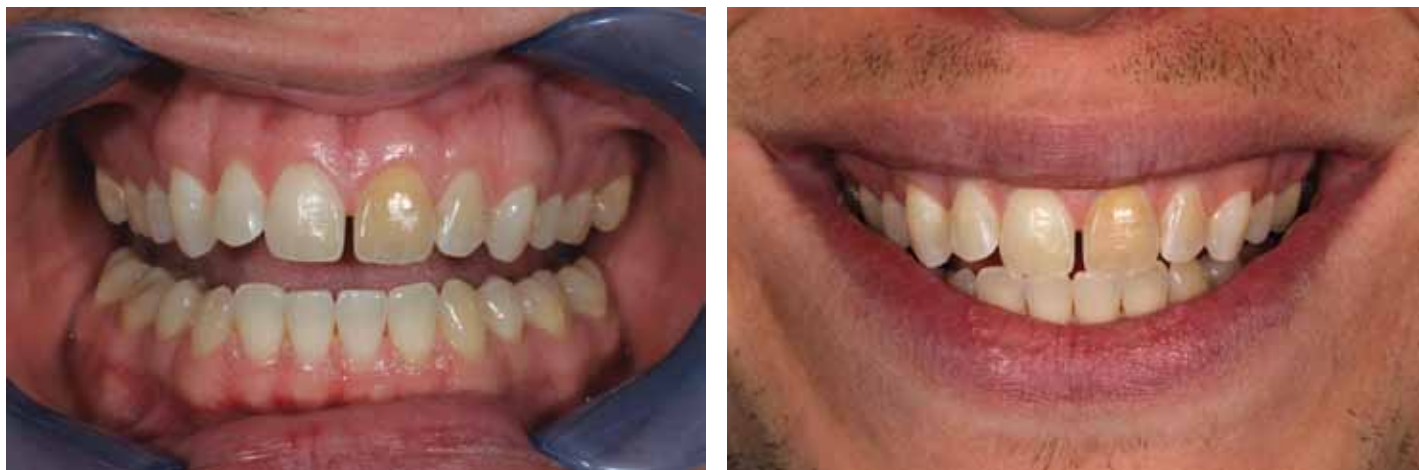As with all diastema closure patients, orthodontics was a treatment option. The patient was getting married soon and had an extremely busy work schedule. His fiancée had veneers, and they were looking for a very straightforward solution. Complete disclosure (information about advantages, disadvantages, risks, and longevity of the restorations, including how many times they would need to be replaced in his lifetime) was provided. After observing the minimal-preparation

veneer option, the patient decided upon that treatment.

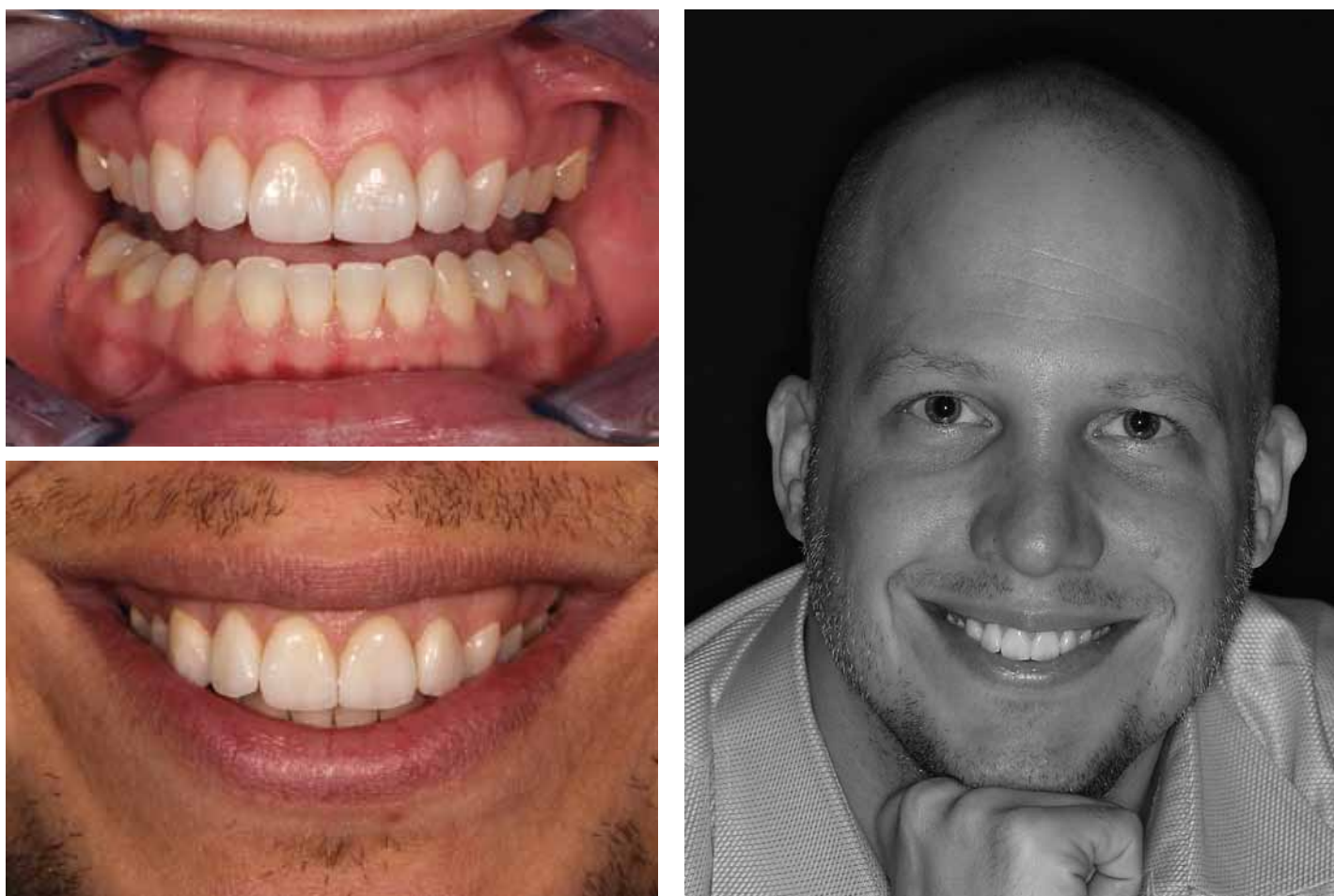A 0.5 to 0.7 mm preparation (CL-III in the LeSage veneer classification system) was performed on the dark #9, and virtually prepless (CL-I) all-ceramic restorations were provided for ##6-10. A natural smile was achieved that combined the patient's desires for uniqueness (maintaining his personality and character) and today's contemporary approach to smile design (Figs 25a-25c).

#### Case #3

[Editor's Note: Case #3 is a European case and uses the international numbering system.] A 58-year-old woman presented with #11, #13, and ##21-23 worn by bruxing activity; and a post and core and crown on #12 (Figs 26a-26f). Her main complaint was that her smile looked "old." On a perceptive level, the flat in-

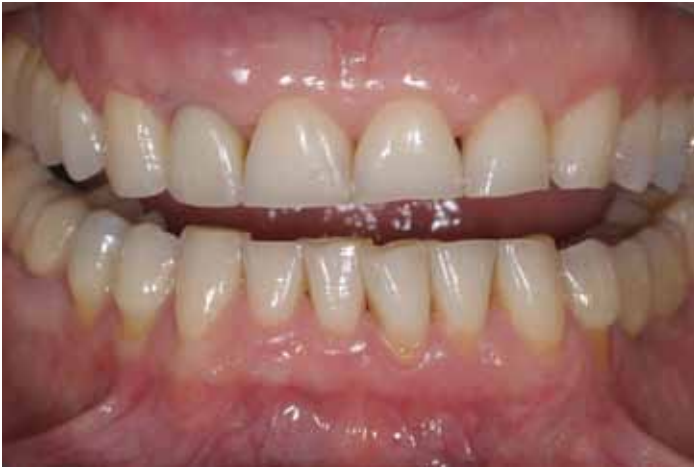

**Figure 24:** (A) Preoperative view showing the patient's diastema and unique smile characteristics. (B) Retracted preoperative view showing very dark #9.

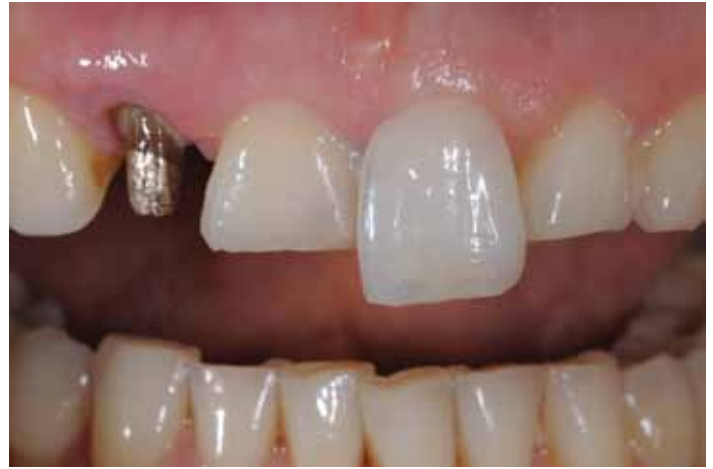

**Figure 25:** (A) View of the minimal preparations completed for the patient. (B) Postoperative view showing all-ceramic restorations. (C) Portrait showing a natural smile.

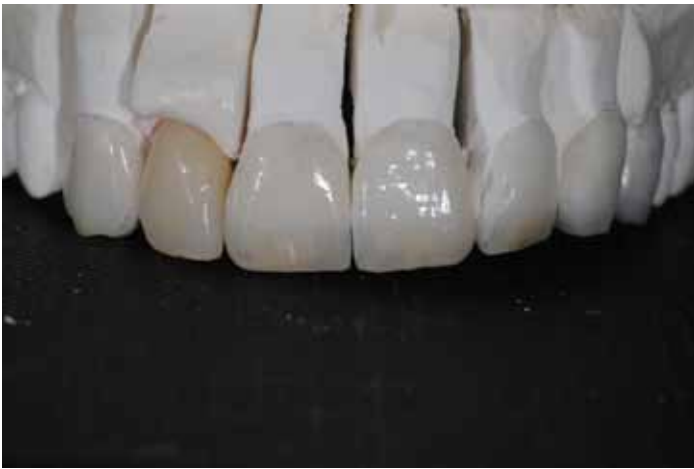



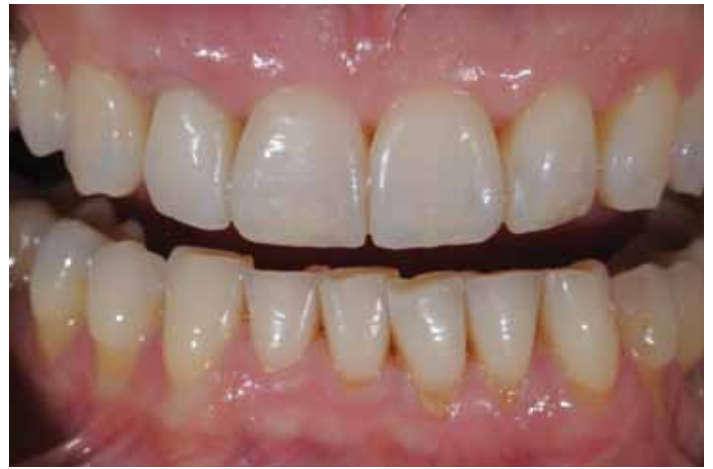**Figure 26a:** Postoperative image showing flat incisal edge of the front teeth worn from bruxing.



**Figure 26b:** Try in of porcelain additional veneer of #9; note the extension of the incisal edge.



**Figure 26c:** Porcelain restorations on the cast.



**Figure 26d:** Retracted clinical image showing porcelain crown on #7, and porcelain full additional veneers on #6 and ##8-12.



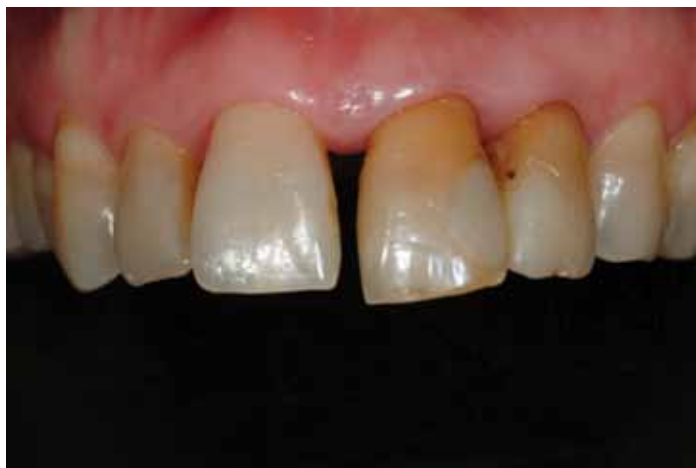**Figure 26e:** Preoperative facial view.



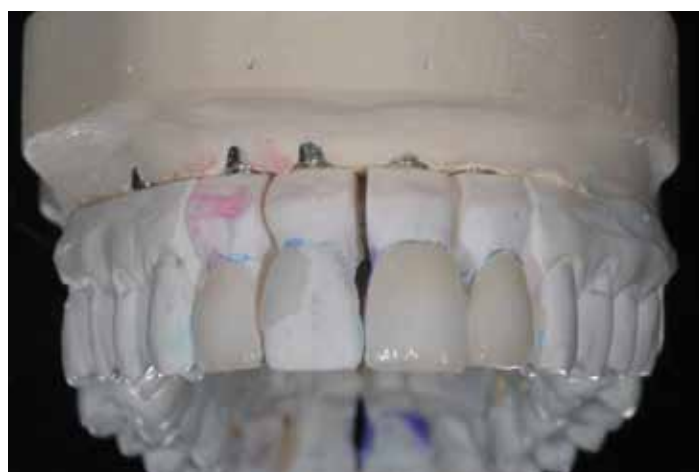**Figure 26f:** Postoperative facial view.



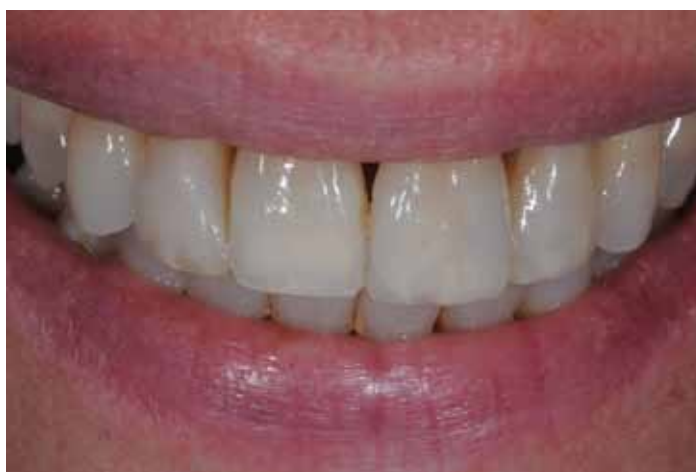**Figure 27a:** The patient before treatment.



**Figure 27b:** Clinical situation before treatment.



**Figure 27c:** Full additional veneers on #7, #9, and #10 and partial additional veneer on #8 (no preparation).



**Figure 27d:** Postoperative smile.



**Figure 27e:** The patient after treatment.

## Every case, no matter what the patient presents with, should be addressed as an esthetic case.

cisal edge of the front teeth was very noticeable compared with the lower lip line, indeed giving her smile an aged appearance. In addition, all the front teeth needed to be elongated.

To overcome the aged-looking smile, it was decided to make the centrals longer to attract the most visual weight and simulate what often is seen in youthful smiles. Particular attention was applied to the tooth surface texture and stain characterizations in order to simulate natural dentition. Treatment consisted of replacing the restoration on #12 with a new porcelain-fused-to-metal restoration, full porcelain veneers without preparation on #11, #21, and #22, and additive partial veneers on #13 and #23 to replace the original anatomy worn by years of parafunction.

### Case #4

[Editor's Note: Case #4 is a European case and uses the international numbering system.] A 40-year-old woman presented with chromatic and alignment problems on ##13-23 (Figs 27a-27e). Her main complaints were the dark color of #21 and #22, and that the front teeth were slowly moving outward. On a perceptible level, all the visual weight was dominated by the diastema between the two central incisors, and the elongated #21 created much visual tension and an unpleasant smile.

The treatment consisted of periodontal scaling and root planing. After achieving complete inflammation control, she underwent orthodontic treatment to align #21 and #22. Bleaching was performed, and three full additive veneers were placed on #12, #21, and #22, while #11 was treated with a partial additive veneer to compensate for the lack of papillae between #11 and #12.

### Conclusion

By understanding the fundamentals of smile design and the artistic approach, including psychology and visual perception, dentists today have the ability

to provide their patients with restorations based on individual characteristics, personality, needs, circumstances, and desires.<sup>3,4,6</sup> It is imperative to balance formulas with artistic views. The smile is a function of weight, balance, dimension, configuration, and gestalt in the patient's smile and face.

Simultaneously, the outcomes of treatment can satisfy clinical requirements for function and longevity, as well as today's emphasis on minimally invasive protocols.<sup>29,30</sup> At a time when dentistry is experiencing a paradigm shift from aggressive smile makeovers to those that are conservative and functional as well as esthetic, it behooves clinicians to inform patients of the benefits and consequences of choosing aggressive treatments and unnatural-looking esthetics over appropriate treatments and more natural-looking results. This upholds the duty to do no harm; it requires better communication, consent, treatment planning, and material selection; and a commitment to achieving the patient's objectives for the best in function, longevity, and esthetics.

### References

1. Keenan L. Providing oral health care across cultures. *J Dent Hyg.* 2009;83(4):180-1. Epub 2009 Nov 2.
2. Waldman HB. Dental care needs and services for children: England, Wales, and United States compared. *ASDC J Dent Child.* 1983;50(1):48-54.
3. Ahmad I. Risk management in clinical practice. part 5. ethical considerations for dental enhancement procedures. *Br Dent J.* 2010;209(5):207-14.
4. Saint Louis C. When that smile is too perfect. *The New York Times.* 2010 Oct 19. Available from: <http://www.nytimes.com/2010/10/21/fashion/21SKIN.html>.

5. Petersen PE. Global policy for improvement of oral health in the 21st century—implications to oral health research of World Health Assembly 2007, World Health Organization. *Community Dent Oral Epidemiol.* 2009;37(1):1-8. Epub 2008 Nov 12.
6. McLaren E, Cao P. Smile analysis and esthetic design: "in the zone." *Inside Dent.* 2009;5(7):44-8.
7. Dalloca L. The fusion of beauty and art. *Oral Health J.* 2010 Apr;20-1.
8. Edwards B. *The new drawing on the right side of the brain.* New York: Tarcher; 1999.
9. Gladwell M. *Outliers: the story of success.* New York: Little, Brown; 2008.
10. Chiche G, Pinault A. *Esthetics of anterior fixed prosthodontics.* Hanover Park (IL): Quintessence Pub.; 1994.
11. Lombardi RE. The principles of visual perception and their clinical application to denture esthetics. *J Prosthet Dent.* 1973;29(4):358-82.
12. Pretty IA, Sweet D. A look at forensic dentistry—part 1: the role of teeth in the determination of human identity. *Br Dent J.* 2001;190(7):359-66.
13. Introna F Jr, Cantatore E, Dragone M, Colonna M. Sexual dimorphism of deciduous teeth in medico-legal identification. *Boll Soc Ital Biol Sper.* 1993;69(4):223-30.
14. Shillingburg HT Jr, Kaplan MJ, Grace SC. Tooth dimensions—a comparative study. *J South Calif Dent Assoc.* 1972 Sep;40(9):830-9.
15. Wheeler R, Ash MM. *Dental anatomy, physiology and occlusion.* In: *An atlas of tooth form.* Philadelphia: Saunders; 1984. 137 p.
16. Massler M, Schour I. *Atlas of the mouth.* Bureau of Public Relations and Council on Dental Health. Chicago: American Dental Association.



17. Morley J, Eubank J. Macroesthetic elements of smile design. *J Am Dent Assoc.* 2001;132(1):39-45.
18. Tjan AH, Miller GD, The JG. Some esthetic factors in a smile. *J Prosthet Dent.* 1984;51(1):24-8.
19. Preston JD. The golden proportion revisited. *J Esthet Dent.* 1993;5(6):247-51.
20. Magne P, Belser U. Bonded porcelain restorations in the anterior dentition: a biomimetic approach. Hanover Park (IL): Quintessence Pub.; 2002.
21. Furhauser R, Florescu D, Benesch T, Haas R, Mailath G, Watzek G. Evaluation of soft tissue around single-tooth implant crowns: the pink esthetic score. *Clin Oral Implants Res.* 2005;16(6):639-44.
22. van der Velden U. Regeneration of the interdental soft tissues following denudation procedures. *J Clin Periodontol.* 1982;9(6):455-9.
23. Tarnow DP, Magner AW, Fletcher P. The effect of the distance from the contact point to the crest of bone on the presence or absence of the interproximal dental papilla. *J Periodontol.* 1992;63(12):995-6.
24. McLaren E, Rifkin R. Macroesthetics: facial and dentofacial analysis. *J Calif Dent Assoc.* 2002;30(11):839-46.
25. Simon Z. Elements of the smile. *J Calif Dent Assoc.* 2008;36(5):332-3.
26. Donitza A. Creating the perfect smile: prosthetic considerations and procedures for optimal dentofacial esthetics. *J Calif Dent Assoc.* 2008;36(5):335-40, 342.
27. Kokich VO Jr, Kiyak HA, Shapiro PA. Comparing the perception of dentists and lay people to altered dental esthetics. *J Esthet Dent.* 1999;11(6):311-24.
28. Spear F. Facially generated treatment planning: a restorative viewpoint. American Academy of Cosmetic Dentistry Annual Meeting, Orlando, FL, 1995.
29. Schultz C. Making standard of caring part of the standard of care. *J Calif Dent Assoc.* 2009;37(9):639-45.
30. Nanchoff-Glatt M. Clinician-patient communication to enhance health outcomes. *J Dent Hyg.* 2009;83(4):179. Epub 2009 Nov 2.
31. LeSage BP. Concepts of temporary restorations. *Dear Doctor.* 2011. www.deardoctor.com. Available from: [http://pages.nxtbook.com/nxtbooks/deardoctor/issue14/offline/deardoctor\\_issue14.pdf](http://pages.nxtbook.com/nxtbooks/deardoctor/issue14/offline/deardoctor_issue14.pdf)

### Additional Sources

Dalocca L, Iafrate R. Esthetics: harmony without symmetry. *QDT.* 1996;19(1):51-7.

Frush JP, Fisher RD. The age factor in dentogenics. *J Prosthet Dent.* 1957 Jan;5-8.

Stein DJ, Carey PD, Warwick J. Beauty and the beast: psychobiologic and evolutionary perspectives on body dysmorphic disorder. *CNS Spectr.* 2006 Jun;11(6):419-22. **JCD**



Dr. LeSage, a Fellow of the AACD, is the course director of the UCLA Aesthetic Continuum and the owner of Beverly Hills Institute of Dental Esthetics in Beverly Hills, California. He can be contacted at [brianlesage@sbcglobal.net](mailto:brianlesage@sbcglobal.net).

**Disclosure:** The author did not report any disclosures.



Dr. Dalloca is the owner of Oral Design Milano, Arcore, Rome, Italy, and Mendrisio, Switzerland. He can be contacted at [dr.dalloca@oraldesign.it](mailto:dr.dalloca@oraldesign.it).

**Disclosure:** The author did not report any disclosures.

### Acknowledgments

*Dr. LeSage thanks Frontier Dental Laboratories (El Dorado Hills, CA) and Burbank Dental Laboratory (Burbank, CA) for their laboratory work on Cases 1 and 2. Dr. Dalloca thanks Mr. Roberto Iafrate, Oral Design (Fontana Liri, Italy) for his laboratory work on Cases 3 and 4.*

# AACD Self-Instruction Continuing Education Information



## General Information

This continuing education (CE) self-instruction program has been developed by the American Academy of Cosmetic Dentistry (AACD) and an advisory committee of the *Journal of Cosmetic Dentistry*.

## Eligibility and Cost

The exam is free of charge and is intended for and available to AACD members only. It is the responsibility of each participant to contact his or her state board for its requirements regarding acceptance of CE credits. The AACD designates this activity for 3 continuing education credits.

## Testing and CE

The self-instruction exam comprises 10 multiple-choice questions. To receive course credit, AACD members must complete and submit the exam and answer at least 70% of the questions correctly. Participants will receive tests results immediately after taking the examination online and can only take each exam once. The exam is scored automatically by the AACD's online testing component. The deadline for completed exams is one calendar year from the publication date of the issue in which the exam appeared. The exam is available online at [www.aacd.com](http://www.aacd.com). A current web browser is necessary to complete the exam; no special software is needed.

Note: Although the AACD grants these CE credits, it is up to the receiving governing body to determine the amount of CE credits they will accept and grant to participants.

## Verification of Participation (VOP)

VOP will be sent to AACD members via their MyAACD account upon pass completion. Log onto [www.aacd.com](http://www.aacd.com) to sign into your MyAACD account.

For members of the Academy of General Dentistry (AGD): The AACD will send the AGD proof of your credits earned on a monthly basis. To do this, AACD must have your AGD member number on file. Be sure to update your AGD member number in your AACD member profile on MyAACD.com.

All participants are responsible for sending proof of earned CE credits to their state dental board or agency for licensure purposes.

## Disclaimer

AACD's self-instruction exams may not provide enough comprehensive information for participants to implement into practice. It is recommended that participants seek additional information as required. The AACD Self-Instruction Program adheres to the guidelines set forth by the American Dental Association Continuing Education Recognition Program (CERP), and the AGD Program Approval for Continuing Education (PACE).

## Questions and Feedback

For questions regarding a specific course, information regarding your CE credits, or to give feedback on a CE self-instruction exam, please contact the AACD Executive Office by e-mailing [meetings@aacd.com](mailto:meetings@aacd.com) or by calling 800.543.9220 or 608.222.8583.



ADA CERP is a service of the American Dental Association to assist dental professionals in identifying quality providers of continuing dental education. ADA CERP does not approve or endorse individual courses or instructors, nor does it imply acceptance of credit hours by boards of dentistry. AACD designates this activity for 3 continuing education credits. Concerns or complaints about a CE provider may be directed to the provider or to ADA CERP at [www.ada.org/goto/cerp](http://www.ada.org/goto/cerp).

The 10 multiple-choice questions for this Continuing Education (CE) self-instruction exam are based on the article, "Approaches to Smile Design: Mathematical to Artistic Interpretation" by Drs. Brian LeSage and Luca Dalloca. This article appears on pages 126-147.

The examination is free of charge and available to AACD members only. AACD members must log onto [www.aacd.com](http://www.aacd.com) to take the exam. Note that only Questions 1 through 5 appears in the printed and digital versions of the *jCD*; they are for readers' information only. The complete, official self-instruction exam is available online only—completed exams submitted any other way will not be accepted or processed. A current web browser is necessary to complete the exam; no special software is needed. The AACD is a recognized credit provider for the Academy of General Dentistry, American Dental Association, and National Association of Dental Laboratories. For any questions regarding this self-instruction exam, call the AACD at 800.543.9220 or 608.222.8583.

**1. When evaluating facial esthetics and how a color is perceived, the patient should realize that**

- a. blue colors have more weight (or "dominance") than reds.
- b. darker colors have more weight than lighter colors.
- c. white has more weight (or "dominance") than darker colors.
- d. color weight (or "dominance") has little visual effect in dentistry.

**2. In discussing shapes, the side (right or left) to which an object is positioned**

- a. can affect its appearance to the viewer.
- b. is irrelevant if natural symmetry is used.
- c. will be optically correct when viewed in a mirror.
- d. allows the object to appear larger if it is on the patient's right.

**3. Central incisors of older patients**

- a. are displayed as long and rectangular, equal in length to the canines.
- b. display decreased incisal embrasures and a smoother facial anatomy.
- c. are typically darker in color and show an increase in value.
- d. have a mamelon pattern demonstrating thick enamel.

**4. Lateral incisors in males are typically viewed as having**

- a. a wider profile at the neck with divergent proximal line angles and a flatter incisal edge.
- b. divergent proximal line angles, flatter incisal edges, and convex gingival embrasures.
- c. rounder incisal edges, convex gingival embrasures, and wider necks.
- d. convex gingival embrasures, flatter incisal edges and parallel proximal line angles.

**5. According to this article, female lateral incisors**

- a. are narrower at the neck and constricted at the gingival aspect.
- b. show converging proximal line angles.
- c. have a more rounded incisal edge and appear as wide as the central incisors.
- d. have more convex gingival embrasures.

To see and take the complete exam, log onto [www.aacd.com](http://www.aacd.com).



# Members' Exchange



## "Pearls" for Taking Portraits

Bernie B. Villadiego, DDS, Chatsworth, CA

Many dentists take clinical photographs to help them diagnose and plan a treatment for their patients. However, some clinicians and their teams are reluctant to implement portrait photography into their practice for several reasons. The list of reasons for not utilizing portrait photography can be long (fear of investing money in unfamiliar photographic equipment can be a discouraging factor). But for those who are interested or who have implemented portrait photography in their practice, the following "pearls" can help to simplify the experience.

1. Start with one light. Many professional photographers use a lot of lights, but this is usually an area where "less is more." Set up one main light and use reflectors and white foam boards to redirect light where it is desired. This will save a great deal of money on equipment.
2. Use the largest softbox that can fit in the room. A larger softbox allows a more beautiful light to wrap around the subject and decrease the contrast quality of the image. I prefer to use softboxes rather than umbrellas because it is easier to control the direction of light. Umbrellas tend to spill too much unwanted light around the room (Fig 1).
3. Position the softbox as close as possible to the subject. To achieve truly soft, beautiful light and more pleasing skin tones, place the softbox as close as possible to the subject without getting in the way of the viewfinder.
4. Camera settings will not have to change very often, if at all. In the studio, the ISO setting is a "set and forget it" setting. For Canon cameras, set the ISO to 100 and for Nikon cameras the ISO setting should be 200. For shutter speed, with studio strobes, 1/125 of a second is a safe setting for the camera to sync up with the strobe lights. If you change to a faster shutter speed, a dark gradient will appear across the image (Fig 2).

Although there is no "correct" f-stop for portraits, a popular f-stop for shooting studio portraits is f/11, because it keeps everything on the subject in focus. Additionally, when you know the shutter speed is 1/125 of a second, and the ideal f-stop is f/11, then all you have to do is power the lights up/down until the lighting looks right at those settings.

5. Make the backgrounds simple. Far too many people make this complicated. If your subject has dark hair, use a light, plain background; if the subject has light hair, use a dark, plain background (Fig 3). This will prevent the subject from blending in with the background (Fig 4).

Portrait photography is very simple and very fun. If you currently take clinical pictures and have not yet ventured into portrait photography, now is the time to go beyond your comfort zone and experience the creative side of photography. It is just a matter of time before you will be presenting your beautiful work with an element of style.



Figure 1: Softbox.

An alternative to using a softbox, which requires no lighting equipment, is a large window, preferably facing north. The sunlight coming from the window will serve as your main light and will give a natural skin tone to your subject. There are so many unique ways to take photographs. It is just a matter of finding quality light.



Figure 2: Sync speed.



Figure 3: Subject with light hair shown against dark background.



Figure 4: Subject with dark hair shown against dark background.

## Advertiser Index

AACD.....	aacd.com .....	81
American Academy of Facial Esthetics.....	FacialEsthetics.org .....	70
Aurum Ceramic Dental Laboratories.....	aurumgroup.com .....	20, 21
Cosmedent .....	cosmedent.com .....	53
Dear Doctor.....	deardocor.com.....	74
Dental GPS.....	dentalgps.com .....	99
DENTSPLY.....	dentsply.com .....	7
The Fahl Center .....	fahlcenter.com .....	89
Ivoclar Vivadent .....	ivoclarvivadent.com ....	IFC, IBC
Heraeus .....	heraeus.com.....	118
Knight Dental Group.....	knightdentalgroup.com.....	122

LK Dental Studio .....	lkdentalstudio.com .....	9
MAC, by Dental Technologies Inc.....	microdental.com/macstudio .....	BC
Micerium S.p.A. ....	micerium.it.....	125
NewBeauty Magazine .....	newbeauty.com .....	43
Panadent .....	panadent.com .....	65
Patient News.....	patientnews.com .....	5
Rosemont Media.....	rosemontmedia.com.....	111, 112
Smiles Inc. ....	whoisbradjones.com.....	29
Springstone Patient Financing .....	springstoneplan.com.....	11
Tokuyama.....	tokuyama-us.com.....	35

# Immediate high strength bonds you can rely on.

Multilink® Automix

## Easy Clean-Up Formula!



Developed to maximize the performance of indirect restorations, Multilink® Automix creates a strong immediate bond between dentin & enamel, and all types of restorative materials providing security you and your patients can rely on.

- High-immediate bond strengths to all types of restorative materials
- Fast, easy clean-up
- Self-etching primer for reduced sensitivity



**Multilink®  
Automix**  
UNIVERSAL ADHESIVE CEMENT

100% CUSTOMER SATISFACTION  
GUARANTEED!

[ivoclarvivadent.us/multilink](http://ivoclarvivadent.us/multilink)

Call us toll free at 1-800-533-6825 in the U.S., 1-800-263-8182 in Canada.  
©2012 Ivoclar Vivadent, Inc. Multilink and IPS e.max are registered trademarks of Ivoclar Vivadent, Inc.

**ivoclar  
vivadent®**  
passion vision innovation



**MACSTUDIO**  
BY MICRODENTAL LABORATORIES

Kimble Slonaker  
2011 MACVENEERS MODEL SEARCH FINALIST

DENTISTRY BY  
Dr. Trevor Murray, Lafayette, IN

## **MACSTUDIO** MICRODENTAL ADVANCED COSMETICS

Kimble's story began with a collaborative approach to smile design. Multimedia and photo-interpretation was used to enhance communication and define preferences. Wash bake methods, internal effect pastes, and porcelains of varied translucencies were harmonized to create beautiful, intrinsic qualities. Cutback and layering techniques, pioneered by MicroDental's cto and AACD accredited CDT Lee Culp, resulted in individualized, anatomical subtleties for each restoration.

From full-mouth rejuvenations to single tooth restorations; MACVENEERS™ to crowns, bridges, implants and removables; MicroDental's MACSTUDIO team can help create A SMILE FOR EVERY STORY™.



MicroDental.com/macstudio  
800.229.0936

**MICRODENTAL**  
LABORATORIES